

# Endoscopic Resection of the Oesophagus and Oesophagogastric Junction Histopathology Reporting Guide



Family/Last name  Date of birth

Given name(s)

Patient identifiers  Date of request  Accession/Laboratory number

Elements in **black text** are **CORE**. Elements in **grey text** are **NON-CORE**.

SCOPE OF THIS DATASET

indicates multi-select values     indicates single select values

## CLINICAL INFORMATION (select all that apply) (Note 1)

- Information not provided
- Relevant biopsy results, *specify*
- Previous diagnosis and treatment for oesophageal cancer, *specify*
- Endoscopic location of the tumour, *specify levels (upper/middle/lower)*
- Clinical staging, *specify level of involvement*
- History of gastroesophageal reflux and/or Barrett oesophagus
- Other (e.g., previous history of cancer), *specify*

## ENDOSCOPIC PROCEDURE (Note 2)

- Not specified
- Endoscopic mucosal resection (EMR)
- Endoscopic submucosal dissection (ESD)
- Other, *specify*

## SPECIMEN DIMENSIONS (Note 3)

(Record per specimen)

x  x

x  x

- Cannot be assessed, *specify*

## MACROSCOPIC APPEARANCE (Note 4)

- No macroscopically detectable lesion
- Polypoid
  - 0-Ip (protruded, pedunculated)
  - 0-Is (protruded, sessile; >2.5 mm above baseline)
- Non-polypoid
  - 0-IIa (superficial, elevated; <2.5 mm above baseline)
  - 0-IIb (flat)
  - 0-IIc (superficial shallow, depressed)
  - 0-III (excavated/ulcerated)

## TUMOUR FOCALITY<sup>a</sup> (Note 5)

- Unifocal
- Multifocal, *specify number of tumours in specimen*
- Cannot be assessed, *specify*

<sup>a</sup> If multiple primary tumours are present, separate datasets should be used to record this and all following elements for each primary tumour.

## TUMOUR SITE (select all that apply) (Note 6)

- Not specified
  - Cervical (proximal) oesophagus
  - Upper thoracic oesophagus
  - Middle thoracic oesophagus
  - Lower thoracic (distal) oesophagus
  - Oesophagogastric junction (OGJ) with tumour epicentre ≤20 mm into the proximal stomach
  - Other, *specify*
- Distance from epicentre/midpoint of tumour to OGJ  mm

## TUMOUR DIMENSIONS (Note 7)

- Maximum tumour dimension  mm
- Additional dimensions  mm x  mm
- No macroscopically visible tumour
  - Cannot be assessed, *specify*

**BARRETT MUCOSA** (Note 8)

- Not identified  
 Present

**HISTOLOGICAL TUMOUR TYPE** (Note 9)

(Value list based on the World Health Organization Classification of Tumours of the Digestive System (2019))

- Cannot be assessed  
 Oesophageal glandular dysplasia, low grade  
 Oesophageal glandular dysplasia, high grade  
 Oesophageal squamous dysplasia, low grade  
 Oesophageal squamous dysplasia, high grade  
 Squamous cell carcinoma  
 Conventional  
 Verrucous  
 Spindle cell carcinoma  
 Basaloid squamous cell carcinoma  
 Adenocarcinoma  
 Tubular  
 Papillary  
 Mucinous  
 Poorly cohesive carcinoma  
 Signet ring  
 Non-signet ring  
 Mucoepidermoid  
 Adenosquamous carcinoma  
 Adenoid cystic carcinoma  
 Undifferentiated carcinoma  
 Neuroendocrine neoplasms<sup>b</sup>  
 Neuroendocrine carcinoma  
 Small cell  
 Large cell  
 Mixed neuroendocrine-non-neuroendocrine neoplasm (MiNEN)  
 Other, specify

<sup>b</sup> Neuroendocrine tumour is not covered in this dataset.

**DYSPLASIA** (Note 10)

- Not applicable  
 Cannot be assessed  
 Not identified  
 Present

**Type**

- Squamous  
 Columnar/Barrett

**Grade**

- Low grade  
 High grade  
 Cannot be assessed, specify

**HISTOLOGICAL TUMOUR GRADE** (Note 11)

(Applicable to squamous cell carcinoma and adenocarcinoma)

- GX: Cannot be assessed  
 Grade 1 (G1): Well differentiated  
 Grade 2 (G2): Moderately differentiated  
 Grade 3 (G3): Poorly differentiated

**TISSUE LAYERS PRESENT** (select all that apply) (Note 12)

- Cannot be assessed  
 Mucosa  
 Glandular  
 Squamous  
 Mixed glandular and squamous  
 Muscularis mucosae  
 Deep muscularis mucosae  
 Superficial muscularis mucosae  
 Submucosa  
 Muscularis propria

**EXTENT OF INVASION** (Note 13)

- Cannot be assessed  
 No evidence of primary tumour  
 Dysplasia  
 Invasion into the lamina propria, specify depth of invasion<sup>c</sup>   
 Invasion into the muscularis mucosae  
 Invasion into the submucosa, specify depth of invasion<sup>d</sup>   
 Invasion into the muscularis propria

<sup>c</sup> Measurement from the lamina propria of the epithelial cells.

<sup>d</sup> Measurement from lower border of muscularis mucosae.

**LYMPHOVASCULAR INVASION** (Note 14)

- Not identified  
 Present (select all that apply)  
 Small vessel (lymphatic, capillary or venular), specify the type of vessel, if possible  
  
 Large vessel (venous)

**PERINEURAL INVASION** (Note 15)

- Not identified  
 Present

**MARGIN STATUS** (Note 16)**Invasive carcinoma** Cannot be assessed Not involvedDistance of tumour from closest margin  mmSpecify closest margin, if possible  Involved (select all that apply) Deep  Lateral**Dysplasia** Cannot be assessed Not involvedDistance of dysplasia from closest margin  mmSpecify closest margin, if possible  Involved Squamous Low grade High grade Columnar/Barrett Low grade High grade**COEXISTENT PATHOLOGY** (select all that apply) (Note 17) None identified Synchronous carcinoma(s), specify Other, specify**ANCILLARY STUDIES** (Note 18)**For neuroendocrine neoplasms only** Not applicable Neuroendocrine markers (chromogranin A, synaptophysin, other), specify test(s) performed and result(s) if available

AND

Ki-67 proliferation index  %**Other oesophageal carcinomas** Not performed Performed, specify test(s) and result(s)**PATHOLOGICAL STAGING (UICC TNM 8<sup>th</sup> edition)<sup>e</sup>** (Note 19)

(Applicable to specimens with sufficient tissue layers present)

**TNM Descriptors** (only if applicable) No adjuvant therapy y - post-therapy**Primary tumour (pT)** TX Primary tumour cannot be assessed Tis Carcinoma in situ/high grade dysplasia T1 Tumour invades lamina propria, muscularis mucosae, or submucosae T1a Tumour invades lamina propria or muscularis mucosae T1b Tumour invades submucosa T2 Tumour invades muscularis propria<sup>e</sup> Reproduced with permission. Source: UICC TNM Classification of Malignant Tumours, 8<sup>th</sup> Edition, eds by James D. Brierley, Mary K. Gospodarowicz, Christian Wittekind. 2016, Publisher Wiley-Blackwell.

## Definitions

### CORE elements

CORE elements are those which are essential for the clinical management, staging or prognosis of the cancer. These elements will either have evidentiary support at Level III-2 or above (based on prognostic factors in the National Health and Medical Research Council (NHMRC) levels of evidence<sup>1</sup>). In rare circumstances, where level III-2 evidence is not available an element may be made a CORE element where there is unanimous agreement in the expert committee. An appropriate staging system, e.g., Pathological TNM staging, would normally be included as a CORE element.

The summation of all CORE elements is considered to be the minimum reporting standard for a specific cancer.

### NON-CORE elements

NON-CORE elements are those which are unanimously agreed should be included in the dataset but are not supported by level III-2 evidence. These elements may be clinically important and recommended as good practice but are not yet validated or regularly used in patient management.

Key information other than that which is essential for clinical management, staging or prognosis of the cancer such as macroscopic observations and interpretation, which are fundamental to the histological diagnosis and conclusion e.g., macroscopic tumour details, may be included as either CORE or NON-CORE elements by consensus of the Dataset Authoring Committee.

[↑ Back](#)

## Scope

The dataset has been developed for the pathology reporting of endoscopic resection (ER) of pre-malignant and malignant lesions of the oesophagus and oesophagogastric junction (OGJ). Surgically resected specimens are covered in a separate dataset.

Neuroendocrine carcinomas (NECs) and mixed neuroendocrine-non-neuroendocrine neoplasms (MiNENs) of the oesophagus are included.

Well differentiated neuroendocrine tumours (NETs), non-epithelial malignancies such as melanoma, and secondary tumours are excluded from this dataset.

[↑ Back](#)

## Note 1 – Clinical information (Non-core)

Clinical information can be provided by the clinician on the endoscopy report or the pathology request form. Pathologists may also search for additional information from previous pathology reports.

Relevant biopsy results include the presence of carcinoma, dysplasia (intraepithelial neoplasia), Barrett metaplasia, etc.

Endoscopic location and information regarding the location of the tumour are an important guide. In addition, the depth of the invasion of early oesophageal cancer can be predicated by endoscopic appearance.<sup>2</sup>

Multiple tumours can occur in the oesophagus and especially in patients with a previous history of cancer, e.g., carcinoma of hypopharynx.

**↑ Back**

## **Note 2 – Endoscopic procedure (Core)**

Endoscopic resection (ER) is indicated in many early oesophageal cancers. Generally, ER for oesophageal cancer is limited to dysplasia and superficial mucosal cancers, whereas surgery is recommended for those with deep mucosal or submucosal invasion.

Endoscopic mucosal resection (EMR) is usually undertaken for mucosal lesions.<sup>3</sup> The complication rate for perforation for EMR is less than 2%.<sup>3</sup>

Endoscopic submucosal dissection (ESD) involves dissecting the submucosa to remove a larger oesophageal cancer and is technically more challenging. It allows for resection of lesions of much larger size but with higher complication rate.<sup>4,5</sup>

On pathological examination of a biopsy of early cancer, the presence of lymphovascular invasion, submucosal invasion, and poor tumour differentiation favour surgical treatment.<sup>6</sup>

**↑ Back**

## **Note 3 – Specimen dimensions (Core)**

When the specimens are received piecemeal, they should be reconstructed for measurement purposes, if possible. The Oesophagus ER Dataset Authoring Committee recommended that the reporting of specimen dimensions should be a core element.

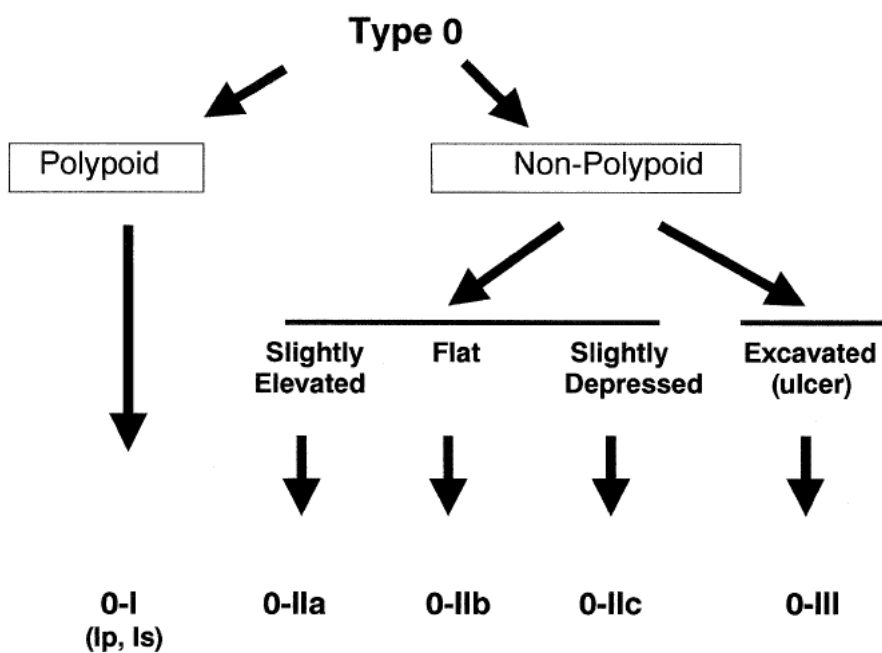
**↑ Back**

## **Note 4 – Macroscopic appearance (Non-core)**

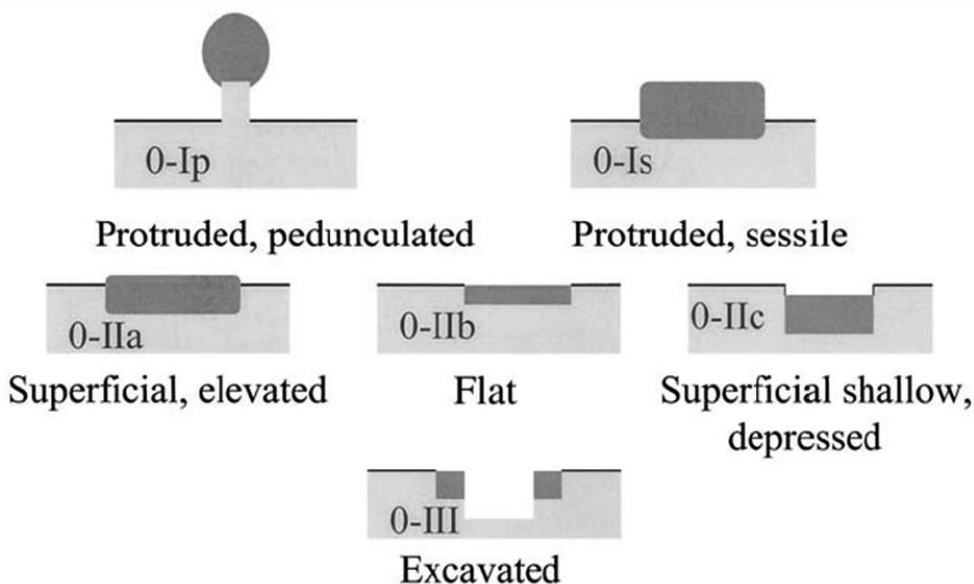
There is no evidence that macroscopic appearance has prognostic value in oesophageal cancer. However, the macroscopic appearance of the lesion, such as having an ulcerative appearance, could indicate the potential for a more advanced lesion.

The pathologist could also refer to the endoscopic appearance, if available, to compare the morphology (Figures 1 and 2).

An intramucosal cancer generally has a flat appearance (Paris classification 0-IIa, 0-IIb,). By contrast, a submucosally invasive cancer often has an excavated (Paris classification 0-IIc, 0-III) and sometimes a polypoid morphology (Paris classification 0-I).<sup>7</sup> In squamous cell carcinoma of the oesophagus, classification of surface vessels and intrapapillary capillary loops also allows accurate assessment of invasion depth.<sup>8,9</sup>



**Figure 1: Neoplastic lesions with ‘superficial’ morphology.** Reproduced with permission from Paris workshop participants (2003). The Paris endoscopic classification of superficial neoplastic lesions: oesophagus, stomach, and colon: November 30 to December 1, 2002. *Gastrointest Endosc* 58(6 Suppl):S3-43.<sup>7</sup>



**Figure 2: Schematic representation of the major variants of type 0 neoplastic lesions of the digestive tract: polypoid (Ip and Is), non-polypoid (IIa, IIb, and IIc), non-polypoid and excavated (III).** Terminology as proposed in a consensus macroscopic description of superficial neoplastic lesions. Reproduced with permission from Paris workshop participants (2003). The Paris endoscopic classification of superficial neoplastic lesions: oesophagus, stomach, and colon: November 30 to December 1, 2002. *Gastrointest Endosc* 58(6 Suppl):S3-43.<sup>7</sup>

↑ Back

## Note 5 – Tumour focality (Core)

Multifocal oesophageal carcinomas should be documented. If there are synchronous primary lesions (i.e., two or more individual tumours), separate datasets should be used to record the tumour site and all following elements for each primary tumour.

↑ Back

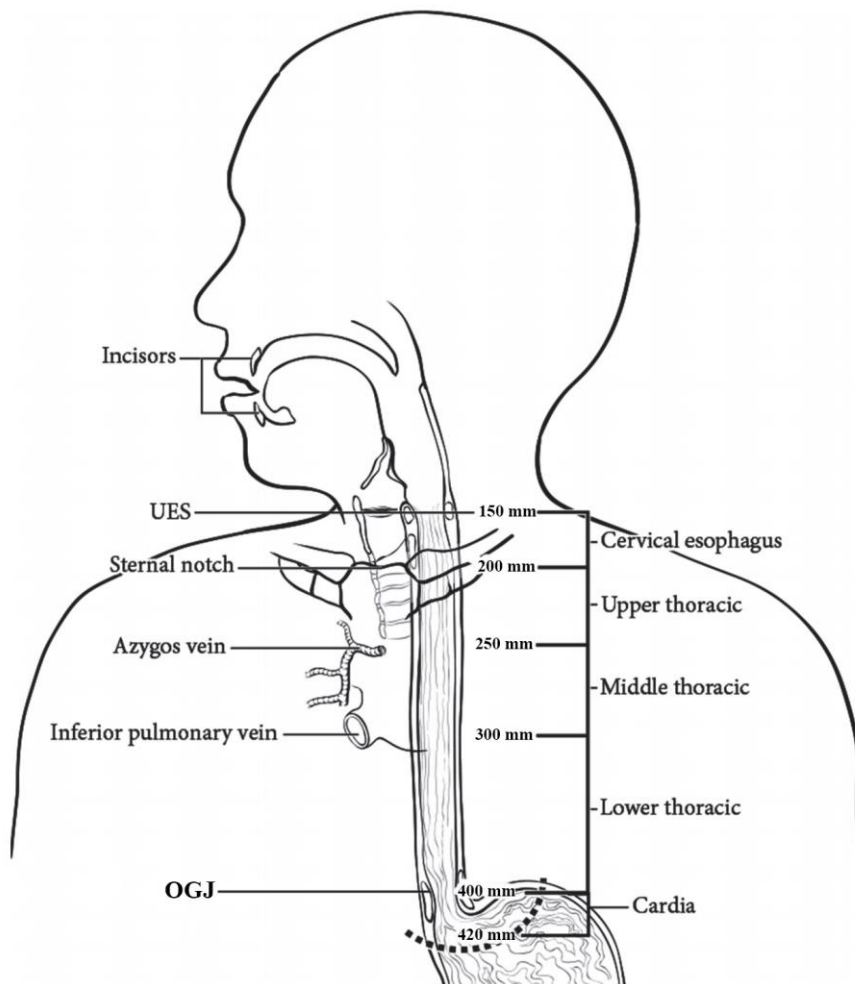
## Note 6 – Tumour site (Core and Non-core)

The location of the tumour is important for staging of oesophageal cancer.<sup>10</sup>

The location of a cancer is based on endoscopic examination and landmarks. Therefore, clinical information provided by surgeon or endoscopist is critical.

The anatomical subdivisions of the oesophagus are outlined below (Figure 3):<sup>10</sup>

- The cervical oesophagus begins at the hypopharynx and extends to the thoracic inlet (at the level of the sternal notch); 15 to <20 cm from the incisors.
- Upper thoracic oesophagus extends from the thoracic inlet to the lower border of the azygos vein; 20 to <25 cm from the incisors.
- Middle thoracic oesophagus extends from the lower border of the azygos vein to the lower border of the inferior pulmonary vein; 25 to <30 cm from the incisors.
- Lower thoracic (distal) oesophagus extends from the lower border of the inferior pulmonary vein to the stomach, including the abdominal oesophagus; 30-40 cm from the incisors.
- Upper oesophagus is equal to cervical oesophagus and upper thoracic oesophagus.
- Middle oesophagus is equal to middle thoracic oesophagus.
- Lower oesophagus is equal to lower thoracic oesophagus or distal oesophagus.



**Figure 3: Anatomic subdivisions of the oesophagus.** Modified with permission of the American College of Surgeons, Chicago, Illinois. The original source for this information is the American Joint Committee on Cancer Staging Manual, Eighth Edition (2016) published by Springer Science+Business Media.<sup>10</sup>

A description of the tumour site is ideally provided by the surgeon and should be documented by the pathologist. In addition, specific observations should be recorded by the pathologist which may help establish the exact site of origin of the tumour.

The American Joint Committee on Cancer (AJCC) and College of American Pathologists (CAP) define the OGJ as the junction of the tubular oesophagus and the stomach, irrespective of the type of epithelial lining of the oesophagus.<sup>10,11</sup>

Pure anatomical classification of the tumour site of origin can be defined in several different systems.

The Siewert classification categorises OGJ cancer into Siewert type I (tumours with their epicentre located 1-5 cm above the OGJ), type II (tumour epicentre located from 1 cm above to 2 cm below the OGJ) and type III (tumour epicentre located from 2 cm - 5 cm below the OGJ).<sup>12</sup> In the Siewert classification, the proximal end of the gastric longitudinal mucosa folds is used as pragmatic reference for the endoscopic cardia/OGJ (zero point).<sup>12</sup> The current Union for International Cancer Control (UICC)<sup>13</sup>/AJCC<sup>10</sup> 8<sup>th</sup> Edition Staging System definition of gastric cancer includes those tumours involving the OGJ but with the epicentre >2 cm into the proximal stomach and cardia cancer without involvement of the OGJ.<sup>10</sup> Therefore, all Siewert type III tumours are classified as gastric cancer based on the UICC<sup>13</sup>/AJCC<sup>10</sup> 8<sup>th</sup> Edition Staging Systems.



The UICC<sup>13</sup>/AJCC<sup>10</sup> 8<sup>th</sup> Edition Staging Manuals also define tumours involving the OGJ as those with a midpoint within the proximal 20 millimetres (mm) of the cardia/proximal stomach and are staged as oesophageal cancers. In contrast, tumours involving the OGJ with their epicentre more than 20 mm into the cardia/proximal stomach are staged as stomach cancers, as are all cardia/proximal stomach cancers not involving the OGJ, even if within 20 mm of the OGJ.

Some proximal stomach tumours which appear to be of gastric origin, under the AJCC 8<sup>th</sup> Edition classification, may be classified as tumours of the oesophagus and OGJ somewhat artificially and thus reported using the oesophageal dataset.<sup>10</sup> When reporting such tumours, it should be noted that the tumour may have arisen within the stomach.

**↑ Back**

## **Note 7 – Tumour dimensions (Core and Non-core)**

Where possible, the pathologist should record the maximum longitudinal dimension of the tumour mass and the distance of the tumour midpoint from the OGJ in the oesophagus and in the stomach.

If no tumour is macroscopically visible, or for small tumours where the macroscopic dimensions may not be accurate then the microscopic dimensions should be documented.

If the specimen is fragmented, measurements of the reconstructed tumour should be estimated, where possible. Otherwise, the clinical and/or radiological measurements should be used.

**↑ Back**

## **Note 8 – Barrett mucosa (Core)**

The presence of Barrett mucosa points to the aetiology of the adenocarcinoma and helps to differentiate the origin of the lesion i.e., oesophageal versus gastric. The definition of Barrett mucosa varies between countries. In many regions, the presence of goblet cells is required for a diagnosis of Barrett mucosa.

**↑ Back**

## **Note 9 – Histological tumour type (Core)**

Pathological staging is different for the two major groups of oesophageal carcinomas, adenocarcinoma and squamous cell carcinoma.<sup>10,14</sup> It is important to refer to the current World Health Organization (WHO) Classification of Tumours of the Digestive System, 5<sup>th</sup> Edition, 2019 (Table 1) for the different oesophageal malignant neoplasms.<sup>15</sup>

Adenoid cystic carcinoma, undifferentiated carcinoma or NEC with an adenocarcinoma component, follow the adenocarcinoma stage grouping.<sup>16</sup> There is no definite evidence for whether the staging of adenosquamous carcinoma or mucoepidermoid carcinoma should follow that of squamous cell carcinoma or adenocarcinoma staging groups.<sup>15</sup>

For adenocarcinoma, there are different histological patterns. In most instances, they could be grouped either into tubular, papillary and mucinous patterns. In rare circumstances, the tumour could be poorly cohesive and have either signet ring or non-signet ring pattern.

In MiNENs of the oesophagus, the neuroendocrine component is nearly always NEC.

**Table 1: World Health Organization classification of tumours of the oesophagus.**<sup>15</sup>

Descriptor	ICD-O codes <sup>a</sup>
<b>Benign epithelial tumours and precursors</b>	
Squamous cell papilloma NOS	8052/0
Squamous papillomatosis	8060/0
Oesophageal glandular dysplasia (intraepithelial neoplasia), low grade	8148/0
Oesophageal glandular dysplasia (intraepithelial neoplasia), high grade	8148/2
Oesophageal squamous intraepithelial neoplasia (dysplasia), low grade	8077/0
Oesophageal squamous intraepithelial neoplasia (dysplasia), low grade	8077/2
<b>Malignant epithelial tumours</b>	
Adenocarcinoma NOS	8140/3
Adenoid cystic carcinoma	8200/3
Mucoepidermoid carcinoma	8430/3
Adenosquamous carcinoma	8560/3
Squamous cell carcinoma NOS	8070/3
Verrucous squamous cell carcinoma	8051/3
Squamous cell carcinoma, spindle cell	8074/3
Basaloid squamous cell carcinoma	8083/3
Carcinoma, undifferentiated, NOS	8020/3
Lymphoepithelioma-like carcinoma	8082/3
Neuroendocrine tumour NOS	8240/3
Neuroendocrine tumour, grade 1	8240/3
Neuroendocrine tumour, grade 2	8249/3
Neuroendocrine tumour, grade 3	8249/3
Neuroendocrine carcinoma NOS	8246/3
Large cell neuroendocrine carcinoma	8013/3
Small cell neuroendocrine carcinoma	8041/3
Mixed neuroendocrine–non-neuroendocrine neoplasm (MiNEN)	8154/3
Combined small cell–adenocarcinoma	8045/3
Combined small cell–squamous cell carcinoma	8045/3

<sup>a</sup> These morphology codes are from the International Classification of Diseases for Oncology, Third Edition, second revision (ICD-O-3.2).<sup>17</sup> Behaviour is coded /0 for benign tumours; /1 for unspecified, borderline, or uncertain behaviour; /2 for carcinoma in situ and grade III intraepithelial neoplasia; and /3 for malignant tumours, primary site; and /6 for malignant tumours, metastatic site.

© World Health Organization/International Agency for Research on Cancer. Reproduced with permission.

**↑ Back**

## Note 10 – Dysplasia (Core)

There are two types of dysplasia, squamous dysplasia and columnar/glandular (either Barrett or non-Barrett) dysplasia.

In the current WHO classification, both squamous and Barrett dysplasia are classified using a two-tiered system, high and low grade.<sup>15</sup>

Columnar dysplasia is mostly Barrett dysplasia. The presence of Barrett dysplasia supports oesophageal origin of an adenocarcinoma.

The term Barrett dysplasia in the WHO classification is adopted because of the aetiological link with Barrett oesophagus. However, it is noted that rare cases of oesophageal adenocarcinoma may not arise from Barrett dysplasia. For instance, some rare adenocarcinoma of the mid oesophagus have no relationship with Barrett dysplasia.<sup>15</sup>

Oesophageal columnar neoplasia is broadly divided into gastric, intestinal and mixed (hybrid) types, based on morphological and immunohistochemical features. The clinical significance of this division is yet to be determined and is not needed for routine clinical care.

Over the past 10 years or more, there has been an important shift from surgery towards endoscopic treatment for Barrett oesophagus in patients with high grade dysplasia.<sup>15</sup> It currently a controversial issue whether confirmed low grade dysplasia justifies invasive management.<sup>15</sup>

**↑ Back**

## Note 11 – Histological tumour grade (Core)

Grade (differentiation) of the tumour contributes to pathological staging or pathological prognostic grouping.<sup>10</sup>

The 5<sup>th</sup> Edition of the WHO classification has defined the morphological criteria for grading of adenocarcinoma and squamous cell carcinoma.<sup>15</sup>

In adenocarcinoma, grade 1 is defined as adenocarcinoma with >95% of the carcinoma with well-formed glands; grade 2 with 50% to 95% with well-formed glands; grade 3 is <50% with glandular formation.<sup>16</sup>

In squamous cell carcinoma, grade 1 to grade 3 depends on the amount of keratin pearls, cytological atypia, mitotic activity and proportion of basaloid cells.<sup>14</sup>

Histological tumour grade is applicable to squamous cell carcinoma and adenocarcinoma only.

**↑ Back**

## Note 12 – Tissue layers present (Core)

Reporting of the tissue layers present in the specimen is important, as it provides context for the assessment of extent of invasion. For example, it is not possible to assess submucosal invasion if an ER specimen consists only of the mucosa.

It is worth noting that muscularis mucosae often duplicates, and this should be considered on assessment of the tissue present and the level of invasion.

In Barrett oesophagus, in addition to the original muscularis mucosae, a second ('neo') muscularis mucosae is often formed. The original muscularis mucosae is defined as the deep muscularis mucosae, and the newly derived muscularis mucosae is defined the superficial muscularis mucosae.

**↑ Back**

## Note 13 – Extent of invasion (Core and Non-core)

The UICC<sup>13</sup>/AJCC<sup>10</sup> 8<sup>th</sup> Edition Staging Manuals divide T stage into T1a and T1b. T1a refers to invasion into lamina propria or muscularis mucosae whereas T1b involves the submucosa. Thus, the depth of invasion which is the T staging criteria, must be recorded accurately.

It is also useful to measure the depth of invasion from the basement membrane of the epithelial layer and invasion to the submucosa (in mm).

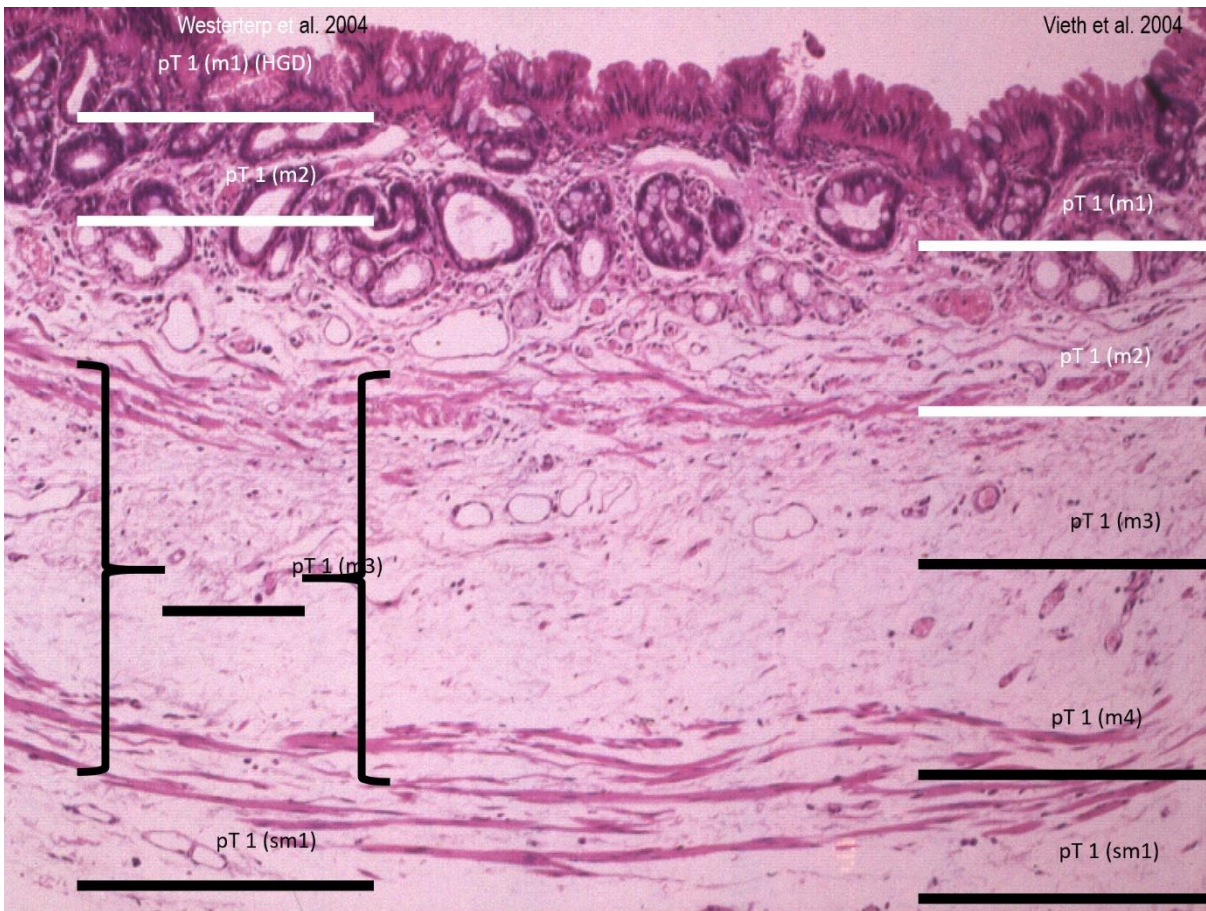
In addition, the extent of invasion has been associated with lymphovascular invasion and recurrence. For both glandular and squamous malignancies, there are efforts to further subdivide the level of invasion. However, there is lack of multicentred studies to confirm the need of these subdivisions and to evaluate the best system to use.

The following systems are commonly employed and are provided as reference for optional use:

### For adenocarcinoma and high grade Barrett dysplasia

In these malignancies, the Barrett muscularis mucosae is duplicated (Figures 4 and 6; Table 2).<sup>10,18-20</sup> There is a proposal to subdivide the involvement of muscularis mucosae into two classes as follows:

- Cannot be assessed
- High grade dysplasia (m1) Tis
- Invasion into lamina propria (m2, T1a)
- Invasion into muscularis mucosae (Inner duplicated layer) (m3, T1a)
- Invasion into muscularis mucosae (Outer duplicated layer) (m4, T1a)
- Invasion into submucosa (T1b)
- Invasion into muscularis propria (T2)



**Figure 4: Subdivision of mucosal Barrett layer.** Reproduced with permission from Vieth et al (2012). Barrett oesophagus. Practical issues for daily routine diagnosis. *Pathology - Research and Practice* 208(5):261-268.<sup>21</sup>

**Table 2: Intramucosal carcinoma (T1a) subclassification schemes.**<sup>10,18-20</sup>

Depth of invasion	Vieth et al 2005 <sup>18</sup>	Westerterp et al 2005 <sup>20</sup>	Kaneshiro et al 2011 <sup>19</sup>	AJCC 2017 <sup>10</sup>
None - Tis, high grade dysplasia (HGD)	HGD	m1	HGD	Tis
Tumour cells invade into lamina propria (LP) beyond the basement membrane	m1	m2	LP	T1a
Tumour cells invade inner duplicated muscularis mucosae (IMM)	m2	m2	IMM	T1a
Tumour cells in the space between the duplicated muscularis mucosae and original muscularis mucosae, i.e., between muscularis mucosae (BMM)	m3	m2	BMM	T1a
Tumour cells into outer original muscularis mucosae (OMM)	m4	m3	OMM	T1a

For squamous cell carcinoma and high grade squamous dysplasia

For these malignancies, Japanese pathologists have proposed a different sub-division of levels of invasion as follows:

- T1a-EP
- T1a-LPM
- T1a-MM
- T1b-SM1
- T1b-SM2
- T1b-SM3

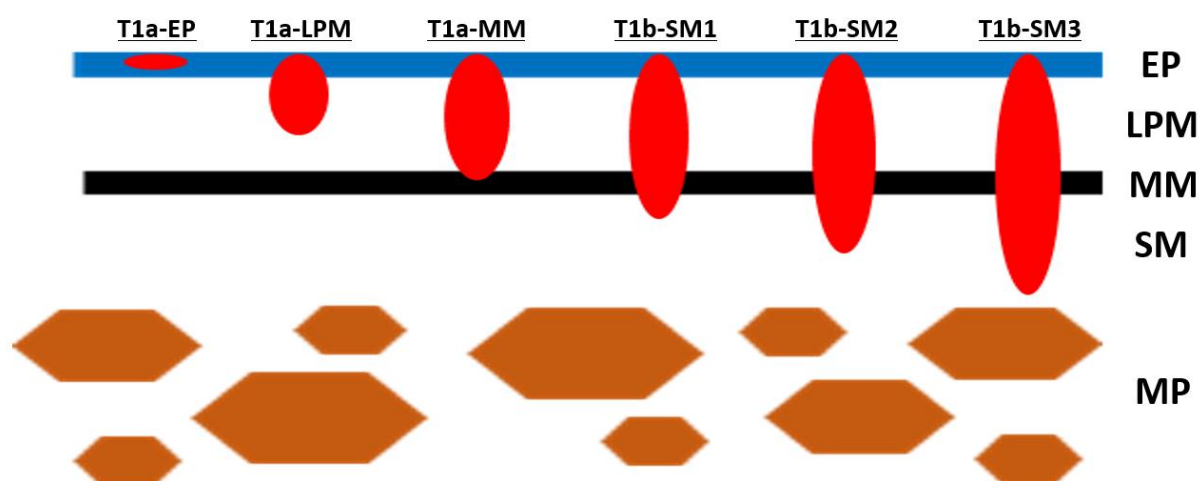
pT1 of intramucosal cancer is assessed in the three stages, including pT1-EP (epithelium), pT1a-LPM (lamina propria mucosae) and pT1a-MM (muscularis mucosae) (Figures 5 and 6).

When cancer remains in the mucosal layer, the depth of invasion is subclassified into three levels, pT1a-EP (cancer cells remain in the columnar epithelial layer), pT1a-LPM (cancer cells involve the lamina propria mucosae) and pT1a-MM (cancer cells invade the muscularis mucosae).

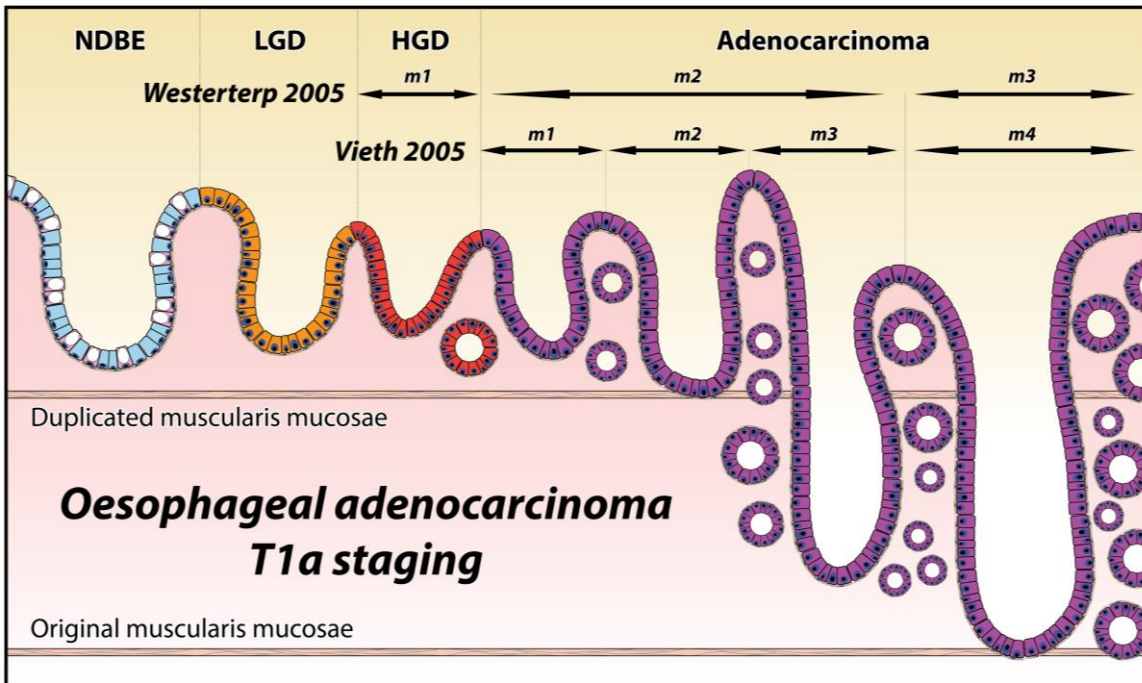
For cancer that invades the submucosa, the submucosa is divided into three equal parts to express the depth of invasion under microscopic observation - the top layer, middle layer, and bottom layer are pSM1, pSM2, and pSM3, respectively.

In a cancer that invades beyond the muscularis mucosae of an ER case, the entire submucosal layer cannot be observed. Therefore, the depth of invasion from the lower end of the muscularis mucosae should be described using measured values. The subclassification of pT1b is pT1b-SM1 for cancer cell invasion up to 200 micrometres ( $\mu\text{m}$ ) and pT1b-SM2 for cancer cell invasion exceeding 200  $\mu\text{m}$ .

One of the rationales for this subdivision is that the risk of lymph node metastasis is shown to be related to the invasive depth for ER cases.<sup>22,23</sup>



**Figure 5: pT1 of intramucosal squamous cancer is assessed in the three stages: pT1-EP (epithelium), pT1a-LPM (lamina propria mucosae) and pT1a-MM (muscularis mucosae). The subclassification of pT1b is: pT1b-SM (submucosa) 1 for cancer cell invasion up to 200  $\mu\text{m}$  and pT1b-SM2 for cancer cell invasion exceeding 200  $\mu\text{m}$ ; MP (muscularis propria).** Modified with permission from Japan Esophageal Society (2017). Japanese Classification of Esophageal Cancer, 11<sup>th</sup> Edition: Part I. *Esophagus* 14:1–36.<sup>24</sup> Copyright © The Author(s) 2016. Open Access - This content is distributed under the terms of the Creative Commons Attribution 4.0 International License (<http://creativecommons.org/licenses/by/4.0/>)



**Figure 6: Histo-anatomical layers in oesophageal Barrett mucosa and adenocarcinoma (m1-m4).**  
 Permission courtesy of Dr Marnix Jansen.

↑ Back

### Note 14 – Lymphovascular invasion (Core)

Lymphovascular invasion is a known poor prognostic factor in oesophageal carcinomas and is designated a core element.<sup>15</sup>

The value of subdividing lymphovascular invasion into large vessel (venous) and small vessels (lymphatic, capillary and venular) has not been investigated. However, recording of this type of data will be useful to aid further investigation. Identifying invasion into the extramural veins is also particularly important.

↑ Back

### Note 15 – Perineural invasion (Non-core)

Perineural invasion is an uncommon finding in ER specimens and more studies are needed to validate its impact, therefore it is designated as a non-core parameter.

↑ Back

## **Note 16 – Margin status (Core)**

Where there are multiple tumours, none of which involve a margin, the distance from the lesion nearest to the lateral/radial resection margin should be measured.

If the specimen is received piecemeal, the status of the margins may not be assessable. The lateral margins may not be assessable but the deep margin (which is more important) can and must be assessed in piecemeal EMR.

Endoscopic mucosal resection (EMR) is done either 'en bloc' or piecemeal. Lateral margin assessment can only be done for en bloc resection specimen. If the EMR specimen is received piecemeal, the lateral margins may not be assessable but the deep margin (which is more important) can and must be assessed.

Endoscopic submucosal dissection (ESD) specimens allow better assessment of margins as they are likely to be done en bloc.

For multifocal tumours, the presence of positive margin in any tumours should be indicated as 'positive', and the closest margin can be measured from any tumours in the specimen.

**↑ Back**

## **Note 17 – Coexistent pathology (Non-core)**

Common coexisting pathology other than Barrett oesophagus may include scar tissue, leiomyoma, squamous papilloma, etc.

**↑ Back**

## **Note 18 – Ancillary studies (Core and Non-core)**

For oesophageal neuroendocrine carcinomas including mixed neuroendocrine-non-neuroendocrine carcinomas (MiNECs), the reporting of neuroendocrine marker expression and Ki-67 proliferation index are core elements. These elements are non-core for other types of oesophageal carcinomas. Neuroendocrine neoplasms are classified into NETs, NECs and MiNENs. NETs are graded 1-3 using the mitotic count and Ki-67 proliferation index but pure NETs are not considered within the scope of this dataset.<sup>15</sup> Most NECs show marked cytological atypia, brisk mitotic activity, and are subclassified into small cell and large cell subtypes. NECs are considered high grade by definition.<sup>25</sup> MiNENs are usually composed of a poorly differentiated NEC component and an adenocarcinoma component. If a pure or mixed NEC is suspected on morphology, immunohistochemistry is required to confirm neuroendocrine differentiation, usually applying synaptophysin and chromogranin A as a minimum.<sup>15</sup>

p53 may be used to assess the presence of Barrett dysplasia in selected cases, though it is more useful in the endoscopic biopsy setting rather than for ER.

**↑ Back**



## Note 19 – Pathological staging (Core)

Pathological staging (according to the agreed criteria of the UICC<sup>13</sup> and AJCC<sup>10</sup> 8<sup>th</sup> Editions) is the most important factor to predict the survival of patients with oesophageal carcinomas.

In the AJCC 8<sup>th</sup> Edition Staging Manual, there is only one staging grouping for both squamous cell carcinoma and adenocarcinoma.<sup>10</sup> The stage grouping is different from that without therapy. The grade of carcinoma is not a criterion for the stage grouping.<sup>10,14,16</sup>

For ER, usually T1 is used because of the absence of muscularis propria and adventitia.

↑ Back

## References

- 1 Merlin T, Weston A and Tooher R (2009). Extending an evidence hierarchy to include topics other than treatment: revising the Australian 'levels of evidence'. *BMC Med Res Methodol* 9:34.
- 2 Maes S, Haidry R and Bisschops R (2018). Can the depth of invasion of early esophageal cancer be predicted based on endoscopic evidence? *Minerva Chir* 73(4):385-393.
- 3 Zhang YM, Boerwinkel DF, Qin X, He S, Xue L, Weusten BL, Dawsey SM, Fleischer DE, Dou LZ, Liu Y, Lu N, Bergman JJ and Wang GQ (2016). A randomized trial comparing multiband mucosectomy and cap-assisted endoscopic resection for endoscopic piecemeal resection of early squamous neoplasia of the esophagus. *Endoscopy* 48(4):330-338.
- 4 Yamamoto H, Kawata H, Sunada K, Sasaki A, Nakazawa K, Miyata T, Sekine Y, Yano T, Satoh K, Ido K and Sugano K (2003). Successful en-bloc resection of large superficial tumors in the stomach and colon using sodium hyaluronate and small-caliber-tip transparent hood. *Endoscopy* 35(8):690-694.
- 5 Kim JS, Kim BW and Shin IS (2014). Efficacy and safety of endoscopic submucosal dissection for superficial squamous esophageal neoplasia: a meta-analysis. *Dig Dis Sci* 59(8):1862-1869.
- 6 Simic AP, Skrobic OM and Pesko PM (2019). A surgeon's role in the management of early esophageal, EGJ and gastric lesions. *Dig Dis* 37(5):355-363.
- 7 Participants in the Paris Workshop (2003). The Paris endoscopic classification of superficial neoplastic lesions: esophagus, stomach, and colon: November 30 to December 1, 2002. *Gastrointest Endosc* 58(6 Suppl):S3-43.
- 8 Inoue H, Kaga M, Ikeda H, Sato C, Sato H, Minami H, Santi EG, Hayee B and Eleftheriadis N (2015). Magnification endoscopy in esophageal squamous cell carcinoma: a review of the intrapapillary capillary loop classification. *Ann Gastroenterol* 28(1):41-48.
- 9 Sharma P, Shaheen NJ, Katzka D and Bergman J (2020). AGA clinical practice update on endoscopic treatment of Barrett's esophagus with dysplasia and/or early cancer: expert review. *Gastroenterology* 158(3):760-769.

- 10 Amin MB, Edge SB, Greene FL, Byrd DR, Brookland RK, Washington MK, Gershenwald JE, Compton CC, Hess KR, Sullivan DC, Jessup JM, Brierley JD, Gaspar LE, Schilsky RL, Balch CM, Winchester DP, Asare EA, Madera M, Gress DM and Meyer LR (eds) (2017). *AJCC Cancer Staging Manual. 8th Edition*, Springer, New York.
- 11 College of American Pathologists (2020). *Protocol for the examination of specimens from patients with carcinoma of the esophagus*. Available from: <https://documents.cap.org/protocols/cp-giupper-esophagus-20-4100.pdf> (Accessed 9th October 2020).
- 12 Stein HJ, Feith M and Siewert JR (2000). Cancer of the esophagogastric junction. *Surg Oncol* 9(1):35-41.
- 13 Brierley JD, Gospodarowicz MK and Wittekind C (eds) (2016). *Union for International Cancer Control. TNM Classification of Malignant Tumours, 8th Edition*, Wiley-Blackwell, USA.
- 14 Lam AK (2020). Application of pathological staging in esophageal squamous cell carcinoma. *Methods Mol Biol* 2129:19-31.
- 15 Odze RD, Lam AK, Ochiai A and Washington MK (2019). Tumours of the oesophagus. In: *Digestive System Tumours. WHO Classification of Tumours, 5th Edition.*, Lokuhetty D, White V, Watanabe R and Cree IA (eds), IARC Press, Lyon.
- 16 Lam AK (2018). Application of pathological staging in esophageal adenocarcinoma. *Methods Mol Biol* 1756:93-103.
- 17 Fritz A, Percy C, Jack A, Shanmugaratnam K, Sobin LH, Parkin DM, Whelan SL and World Health Organization (2000). *International classification of diseases for oncology*, World Health Organization, Geneva.
- 18 Vieth M and Stolte M (2005). Pathology of early upper GI cancers. *Best Pract Res Clin Gastroenterol* 19(6):857-869.
- 19 Kaneshiro DK, Post JC, Rybicki L, Rice TW and Goldblum JR (2011). Clinical significance of the duplicated muscularis mucosae in Barrett esophagus-related superficial adenocarcinoma. *Am J Surg Pathol* 35(5):697-700.
- 20 Westerterp M, Koppert LB, Buskens CJ, Tilanus HW, ten Kate FJ, Bergman JJ, Siersema PD, van Dekken H and van Lanschoot JJ (2005). Outcome of surgical treatment for early adenocarcinoma of the esophagus or gastro-esophageal junction. *Virchows Arch* 446(5):497-504.
- 21 Vieth M, Langner C, Neumann H and Takubo K (2012). Barrett's esophagus. Practical issues for daily routine diagnosis. *Pathol Res Pract* 208(5):261-268.
- 22 Yamashina T, Ishihara R, Nagai K, Matsuura N, Matsui F, Ito T, Fujii M, Yamamoto S, Hanaoka N, Takeuchi Y, Higashino K, Uedo N and Iishi H (2013). Long-term outcome and metastatic risk after endoscopic resection of superficial esophageal squamous cell carcinoma. *Am J Gastroenterol* 108(4):544-551.
- 23 Katada C, Muto M, Momma K, Arima M, Tajiri H, Kanamaru C, Ooyanagi H, Endo H, Michida T, Hasuike N, Oda I, Fujii T and Saito D (2007). Clinical outcome after endoscopic mucosal resection for esophageal squamous cell carcinoma invading the muscularis mucosae--a multicenter retrospective cohort study. *Endoscopy* 39(9):779-783.

- 24 Japan Esophageal Society (2017). Japanese Classification of Esophageal Cancer, 11th Edition: part I. *Esophagus* 14(1):1-36.
- 25 Milione M, Maisonneuve P, Spada F, Pellegrinelli A, Spaggiari P, Albarello L, Pisa E, Barberis M, Vanoli A, Buzzoni R, Pusceddu S, Concas L, Sessa F, Solcia E, Capella C, Fazio N and La Rosa S (2017). The clinicopathologic heterogeneity of grade 3 gastroenteropancreatic neuroendocrine neoplasms: morphological differentiation and proliferation identify different prognostic categories. *Neuroendocrinology* 104(1):85-93.