

Endoscopic Resection of the Stomach Histopathology Reporting Guide



Family/Last name	<input type="text"/>	Date of birth	<input type="text" value="DD – MM – YYYY"/>
Given name(s)	<input type="text"/>		
Patient identifiers	<input type="text"/>	Date of request	<input type="text" value="DD – MM – YYYY"/>
		Accession/Laboratory number	<input type="text"/>

Elements in **black text** are **CORE**. Elements in **grey text** are **NON-CORE**.

☐ indicates multi-select values ☐ indicates single select values

SCOPE OF THIS DATASET

CLINICAL INFORMATION (select all that apply) (Note 1)

☐ Information not provided

☐ Relevant biopsy results, *specify*

☐ Endoscopic location of the tumour, *specify*

☐ Clinical staging, *specify level of involvement, distant metastases*

☐ Previous history of gastric cancer, *specify*

☐ Previous endoscopic resection, *specify*

☐ Previous partial gastrectomy procedure, *specify*

☐ History of chronic gastritis, *specify*

☐ Other clinical information, *specify*

ENDOSCOPIC PROCEDURE (Note 2)

☐ Not specified

☐ Endoscopic mucosal resection (EMR)

☐ Endoscopic submucosal dissection (ESD)

☐ Other, *specify*

SPECIMEN DIMENSIONS (Note 3)

Mucosal area

 ×

Thickness

☐ Cannot be assessed, *specify*

TUMOUR FOCALITY^a (Note 4)

☐ Unifocal

☐ Multifocal, *specify number of tumours in specimen*

☐ Cannot be assessed, *specify*

^a If multiple primary tumours are present, separate datasets should be used to record this and all following elements for each primary tumour.

TUMOUR SITE (select all that apply) (Note 5)

☐ Not specified

☐ Region

☐ Upper third

☐ Middle third

☐ Distal third

☐ Curvature

☐ Greater

☐ Lesser

☐ Wall

☐ Anterior

☐ Posterior

☐ Other, *specify*

TUMOUR DIMENSIONS (Note 6)

Maximum tumour dimension

mm

Additional dimensions

mm

x

mm

☐ Cannot be assessed, *specify*
MACROSCOPIC TUMOUR TYPE (Note 7)

(Applicable to early gastric carcinomas)

☐ Protruding (type 0-I)

☐ Superficial (type 0-II)

☐ Excavated (type 0-III)

☐ Other, *specify*
HISTOLOGICAL TUMOUR TYPE (Note 8)(Value list based on the World Health Organization Classification of Tumours of the Digestive System, 5th Edition (2019))
☐ Cannot be assessed

☐ Tubular adenocarcinoma

☐ Papillary adenocarcinoma

☐ Mucinous adenocarcinoma

☐ Poorly cohesive carcinoma, including signet-ring cell carcinoma and other subtypes

☐ Mixed adenocarcinoma

☐ Other histological type/subtype, *specify*
Laurén Classification

(Applicable to gastric adenocarcinomas)

☐ Intestinal

☐ Diffuse

☐ Mixed
HISTOLOGICAL TUMOUR GRADE (Note 9)

(Applicable to tubular and papillary adenocarcinomas)

☐ GX: Cannot be assessed

☐ G1: Well differentiated

☐ G2: Moderately differentiated

☐ G3: Poorly differentiated, undifferentiated

☐ Other, *specify*
TISSUE LAYERS PRESENT (select all that apply) (Note 10)
☐ Cannot be determined

☐ Lamina propria

☐ Muscularis mucosae

☐ Submucosa

☐ Muscularis propria
EXTENT OF INVASION (Note 11)
☐ Cannot be assessed

☐ No evidence of primary tumour

☐ Carcinoma in situ (intraepithelial tumour without invasion of the lamina propria, high grade dysplasia)

☐ Invasion into the lamina propria

☐ Invasion into the muscularis mucosae

☐ Invasion into the submucosa

Depth of invasion

µm

☐ Invasion into the muscularis propria
LYMPHOVASCULAR INVASION (Note 12)
☐ Not identified

☐ Present
MARGIN STATUS (Note 13)**Invasive carcinoma**
☐ Cannot be assessed

☐ Not involved

Distance of tumour from closest margin

mm

Specify closest margin, if possible

☐ Involved (select all that apply)

☐ Mucosal

☐ Deep
High grade dysplasia
☐ Cannot be assessed

☐ Not involved

Distance of high grade dysplasia from closest margin

mm

☐ Involved
Low grade dysplasia
☐ Cannot be assessed

☐ Not involved

☐ Involved
COEXISTENT PATHOLOGY (select all that apply) (Note 14)
☐ None identified

☐ *Helicobacter* gastritis

☐ Autoimmune gastritis

☐ Reactive gastritis

☐ Intestinal metaplasia

☐ Gastric polyps, *specify*
☐ Dysplasia

☐ Low grade

☐ High grade

☐ Synchronous carcinoma(s), *specify*
☐ Other, *specify*

ANCILLARY STUDIES (Note 15)**For neuroendocrine neoplasms only**

- ☐ Not applicable
- ☐ Neuroendocrine markers (chromogranin A, synaptophysin, other), specify test(s) performed and result(s) if available

AND

Ki-67 proliferation index

%

- ☐ Cannot be assessed
- ☐ Not performed

Other gastric carcinomas

- ☐ Not performed
- ☐ Performed, specify test(s) and result(s)

PATHOLOGICAL STAGING (UICC TNM 9th edition)^b (Note 16)
(Applicable to specimens with sufficient tissue layers present)**TNM Descriptors** (only if applicable) (select all that apply)

- ☐ m - multiple primary tumours
- ☐ r - recurrent

Primary tumour (pT)

- ☐ TX^c Primary tumour cannot be assessed
- ☐ Tis Carcinoma in situ: intraepithelial tumour without invasion of the lamina propria, high grade dysplasia
- ☐ T1 Tumour invades lamina propria, muscularis mucosae, or submucosa
- ☐ T1a Tumour invades lamina propria or muscularis mucosae
- ☐ T1b Tumour invades submucosa
- ☐ T2 Tumour invades muscularis propria

^b Reproduced with permission. Source: UICC TNM Classification of Malignant Tumours, 9th Edition, eds by James Brierley, Meredith Giuliani, Brian O'Sullivan, Brian Rous, Elizabeth Van Eycken. 2025, Publisher Wiley (incorporating errata published 12th October 2025).

^c TX should be used only if absolutely necessary.

Definitions

CORE elements

CORE elements are those which are essential for the clinical management, staging or prognosis of the cancer. These elements will either have evidentiary support at Level III-2 or above (based on prognostic factors in the National Health and Medical Research Council (NHMRC) levels of evidence¹). In rare circumstances, where level III-2 evidence is not available an element may be made a CORE element where there is unanimous agreement by the Dataset Authoring Committee (DAC). An appropriate staging system, e.g., Pathological TNM staging, would normally be included as a CORE element.

Molecular and immunohistochemical testing is a growing feature of cancer reporting. However, in many parts of the world this type of testing is limited by the available resources. In order to encourage the global adoption of ancillary tests for patient benefit, International Collaboration on Cancer Reporting (ICCR) includes the most relevant ancillary testing in ICCR Datasets as CORE elements, especially when they are necessary for the diagnosis. Where the technical capability does not yet exist, laboratories may consider temporarily using these data elements as NON-CORE items.

The summation of all CORE elements is considered to be the minimum reporting standard for a specific cancer.

NON-CORE elements

NON-CORE elements are those which are unanimously agreed should be included in the dataset but are not supported by level III-2 evidence. These elements may be clinically important and recommended as good practice but are not yet validated or regularly used in patient management.

Key information other than that which is essential for clinical management, staging or prognosis of the cancer such as macroscopic observations and interpretation, which are fundamental to the histological diagnosis and conclusion e.g., macroscopic tumour details, may be included as either CORE or NON-CORE elements by consensus of the DAC.

 [Back](#)

Scope

The dataset has been developed for the pathology reporting of endoscopic resection (ER) specimens of the stomach. Surgically resected specimens are covered in a separate ICCR dataset.²

Carcinomas involving the oesophagogastric junction (OGJ) with their epicentre >20 millimetres (mm) into the proximal stomach and cardia cancers that do not involve the OGJ are included. These criteria are set by the Union for International Cancer Control (UICC)³ 9th edition/American Joint Committee on Cancer (AJCC)⁴ 8th edition TNM classifications and have been adopted by the World Health Organization (WHO) and define the diagnosis 'gastric cancer'. An ICCR dataset for carcinoma of the oesophagus is available for tumours not meeting these criteria.⁵

Neuroendocrine carcinomas (NECs) and mixed neuroendocrine-non-neuroendocrine neoplasms (MiNENs) (with the exception of mixed adenoma and neuroendocrine tumours (NETs)) are included in this dataset.

Neuroendocrine tumours (NETs), non-epithelial malignancies, and secondary tumours are excluded from this dataset.

The authors of this dataset can be accessed [here](#).

 **Back**

Note 1 – Clinical information (Non-core)

Clinical information should ideally be provided by the clinician in the endoscopy report or the pathology request form. Patient medical records may be another source of information if accessible.

Relevant biopsy results include the presence of carcinoma, dysplasia (glandular intraepithelial neoplasia), and intestinal metaplasia.

Endoscopic tumour location or information on the tumour location as reported by the clinicians are important guides to determine the tumour epicentre.

Multiple tumours may occur in the stomach and previous history of cancer or cancer treatment is relevant. In addition, a number of conditions, including previous partial gastrectomy for a benign disease and chronic atrophic gastritis, are risk factors for gastric cancer.

 **Back**

Note 2 – Endoscopic procedure (Core)

Endoscopic resection (ER), including endoscopic mucosal resection (EMR) and endoscopic submucosal dissection (ESD), is recommended for selected early gastric carcinomas. En bloc resection may be necessary to obtain precise pathological diagnosis. EMR cannot be used to resect lesions larger than 15 millimetres (mm) in one piece, and piecemeal EMR of larger lesions is potentially associated with risk of local recurrence. Therefore, for larger lesions, ESD is the better option.⁶ The European Society of Gastrointestinal Endoscopy (ESGE), American Gastroenterological Association (AGA) and Japanese Gastric Cancer Association (JGCA) recommend ESD as the treatment of choice for most gastric superficial neoplastic lesions.⁷⁻¹⁰ The standard criteria for ER are 1) T1a; 2) well/moderately differentiated; 3) ≤20 mm; 4) non-ulcerated; and 5) no lymphovascular invasion (also see National Comprehensive Cancer Network (NCCN) guidelines for gastric cancer).^{7,8,11} Extended criteria^{7,9} for ESD include: 1) moderately and well differentiated intramucosal carcinoma with no ulcer, size >20 mm; 2) moderately and well differentiated intramucosal carcinomas, with ulcer, size ≤30 mm; 3) moderately and well differentiated carcinomas with early submucosal invasion (SM1) ≤500 micrometres (µm), with no ulcer and size ≤30 mm; and 4) poorly differentiated intramucosal carcinoma ≤20 mm, with no ulcer. Reliable long-term results have not been established for the extended criteria.⁶ Table 1 shows therapeutic recommendations for endoscopic treatment of gastric cancer from the 2018 JGCA treatment guidelines.¹⁰ Based on pathological examination of the ER specimens, patients are managed with either endoscopic surveillance or surgery.

Table 1: Therapeutic recommendations for endoscopic treatment of gastric cancer based on histopathologic examination of endoscopically resected specimens, from the 2018 Japanese Gastric Cancer Association (JGCA) treatment guidelines.¹²

Endoscopic treatment (EMR/ESD)			
Differentiated ^a		Undifferentiated ^a	
Vertical/deep margin (–) Lymphovascular infiltration (–) Any of following: • Intramucosal without ulcer, any size • Intramucosal with ulcer, diameter ≤3 centimetres (cm) (≤30 millimetres (mm)) • Submucosal, diameter ≤3 cm (≤30 mm)		Vertical/deep margin (–) Horizontal/lateral margin (–) Lymphovascular infiltration (–) Intramucosal without ulcer, diameter ≤2 cm (≤20 mm)	
Yes	No	No	Yes
Follow-up ^b	Surgery		Follow-up

EMR, endoscopic mucosal resection; ESD, endoscopic submucosal dissection.

^a According to the Nakamura Classification,¹³ see Table 3 for the corresponding 2017 JGCA and 2019 World Health Organization Classifications.

^b If the horizontal margin is positive, additional endoscopic treatment or surgery is required.

Reproduced with permission from Frayling I et al (2016). Association for Clinical Genetic Science (ACGS) Best practice guidelines for genetic testing and diagnosis of Lynch syndrome.

<https://www.acgs.uk.com/quality/best-practice-guidelines/>, derived from van Lier et al etc.; and from WHO Classification of Tumours Editorial Board. *World Health Organization Classification of Tumours, Digestive System Tumours, 5th Edition*, 2019, IARC Press, Lyon.¹²

© World Health Organization/International Agency for Research on Cancer. Reproduced with permission.

↑ Back

Note 3 – Specimen dimensions (Core)

There is no internationally agreed recommendation on how specimens should be measured and whether they should be measured fresh or after formalin fixation. However, the ICCR Stomach Endoscopic Resection DAC recommended that the reporting of specimen dimensions be a core element as this allows for good clinical correlation.

↑ Back

Note 4 – Tumour focality (Core)

While multifocal gastric carcinomas are rare, they should be documented. If multiple primary tumours are present, separate datasets should be used to describe this and all following elements for each primary tumour.

↑ Back

Note 5 – Tumour site (Core)

The stomach is divided into the cardia, fundus, body, antrum and pylorus, but these regions are difficult to define macroscopically, which is especially true for the cardia and fundus. The JGCA guidelines divide the stomach into upper third, middle third and distal third by the lines connecting the trisected points on the lesser and greater curvatures (Figure 1),¹⁴ which is adopted by this dataset. Primary gastric cancer located in the upper third of the stomach, especially at the OGJ/cardia, are reported to be more aggressive and associated with a poor prognosis.¹⁵

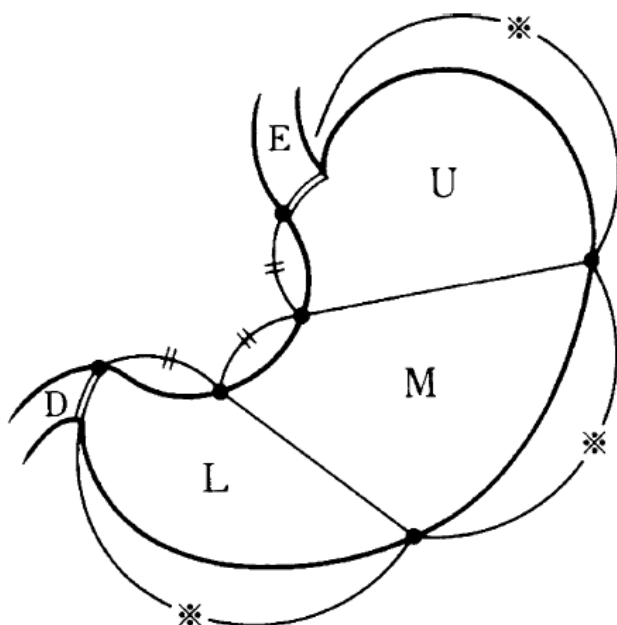


Figure 1: The stomach can be divided into 3 portions: upper third (U), middle third (M) and distal third (L). (E) oesophagus and (D) duodenum. Reproduced with permission from Japanese Gastric Cancer Association, Sano T and Kodera Y (2011). *Japanese classification of gastric carcinoma: 3rd English Edition*, Gastric Cancer Springer; London.¹⁴

The OGJ is defined as the border between the oesophageal and gastric muscles, irrespective of the type of epithelial lining of the oesophagus. However, it can be challenging to determine the exact location of the OGJ, especially in individuals with conditions affecting OGJ landmarks. Four methods have been proposed to locate the OGJ anatomically as follows:¹⁴⁻¹⁶

1. The distal end of the longitudinal palisading small vessels in the lower oesophagus. It can be seen endoscopically as well as microscopically and is commonly used by Japanese pathologists. However, it can be obscured by inflammation.
2. The horizontal level of the angle of His (defined as starting from the peritoneal reflection of the stomach onto the diaphragm), as shown by barium meal examination. It can be altered by hiatal hernia or tumour invasion.
3. The proximal end of the gastric longitudinal mucosal folds, which is the most commonly used definition by endoscopists in Western countries. However, it can be obscured by the presence of gastric mucosal atrophy (i.e., post chemoradiation therapy and atrophic gastritis) or a large gastric mass.
4. The level of the macroscopic calibre changes of the resected oesophagus and stomach.

The current recommendation is to use the proximal end of the gastric longitudinal mucosal folds as the landmark for the OGJ. If it cannot be identified, use the distal end of the longitudinal palisading small vessels.

The Siewert Classification categorises OGJ cancer into Siewert type I (tumours with their epicentre located 10-50 mm above the OGJ), type II (tumour epicentre located from 10 mm above to 20 mm below the OGJ) and type III (tumour epicentre located from 20 mm - 50 mm below the OGJ).¹⁷ In the Siewert Classification, the proximal end of the gastric longitudinal mucosa folds is used as pragmatic reference for the endoscopic cardia/OGJ (zero point).¹⁷ The UICC³ 9th edition/AJCC⁴ 8th edition Cancer Staging System definition of gastric cancer includes those tumours involving the OGJ but with the epicentre >20 mm into the proximal stomach and cardia cancer without involvement of the OGJ (Figure 2). Therefore, all Siewert type III and some Siewert type II tumours are classified as gastric cancer based on the UICC³ 9th edition/AJCC⁴ 8th edition Cancer Staging Systems.

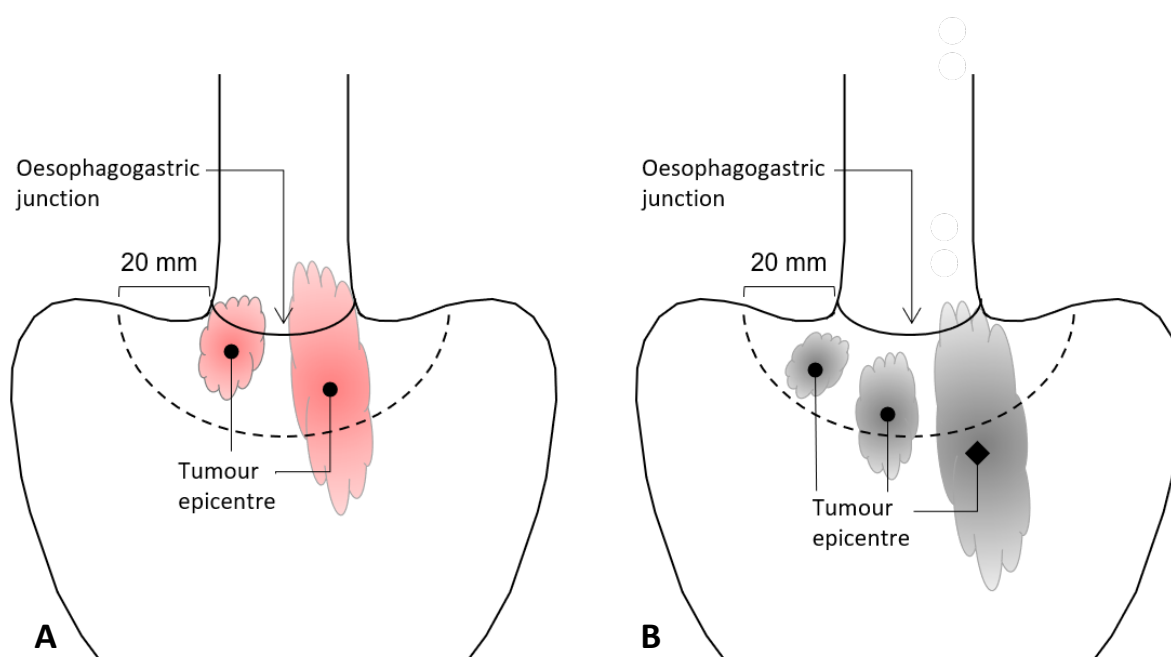


Figure 2: Classification of oesophagogastric junction tumours by epicentre location. (A) Stage as carcinomas of the oesophagus - tumours of the OGJ with epicentre (● circle) in the stomach <20 mm from the OGJ. (B) Stage as carcinomas of the stomach - tumours of the gastric cardia not involving the OGJ (● circle); tumours involving the OGJ with epicentre >20 mm from the OGJ (◊ diamond). *Used with permission courtesy of Dr Amanda Charlton.*

↑ Back

Note 6 – Tumour dimensions (Core and Non-core)

For early gastric cancer, the tumour dimension is usually measured microscopically. However, when the tumour size is large, macroscopic mapping of the entire tumour and a thorough pathologic examination may be necessary.

↑ Back

Note 7 – Macroscopic tumour type (Non-core)

Early gastric carcinoma is defined as an invasive carcinoma involving only the mucosa (T1a) or submucosa (T1b). Growth patterns of early gastric carcinoma are classified into type 0-I (protruding), type 0-II (superficial), and type 0-III (excavated). Type 0-II tumours are further divided into type 0-IIa (superficial, elevated), type 0-IIb (superficial, flat) and type 0-IIc (superficial depressed) (Table 2, Figure 3).^{12,14,18} Tumour ulceration may be a negative determinant in selecting patients for ER, which can be recorded in the dataset. Early gastric carcinomas are usually small, and their macroscopic tumour types may only be accurately assessed by endoscopists.

Table 2: Subclassification of early (type 0) gastric cancer.^{12,14,18}

Type 0-I (protruding)	Polyploid lesions, protruding >3 mm
Type 0-IIa (superficial elevated)	Slightly elevated lesions protruding <3 mm
Type 0-IIb (superficial flat)	Tumours without elevation or depression
Type 0-IIc (superficial depressed)	Slightly depressed lesions
Type 0-III (excavated)	Lesions with a deep depression

Reproduced with permission from Frayling I et al (2016). Association for Clinical Genetic Science (ACGS) Best practice guidelines for genetic testing and diagnosis of Lynch syndrome.

<https://www.acgs.uk.com/quality/best-practice-guidelines/>, derived from van Lier et al etc.; and from World Health Organization (WHO) Classification of Tumours Editorial Board. *WHO Classification of Tumours, Digestive System Tumours, 5th Edition*, 2019, IARC Press, Lyon.¹²

© World Health Organization/International Agency for Research on Cancer. Reproduced with permission.

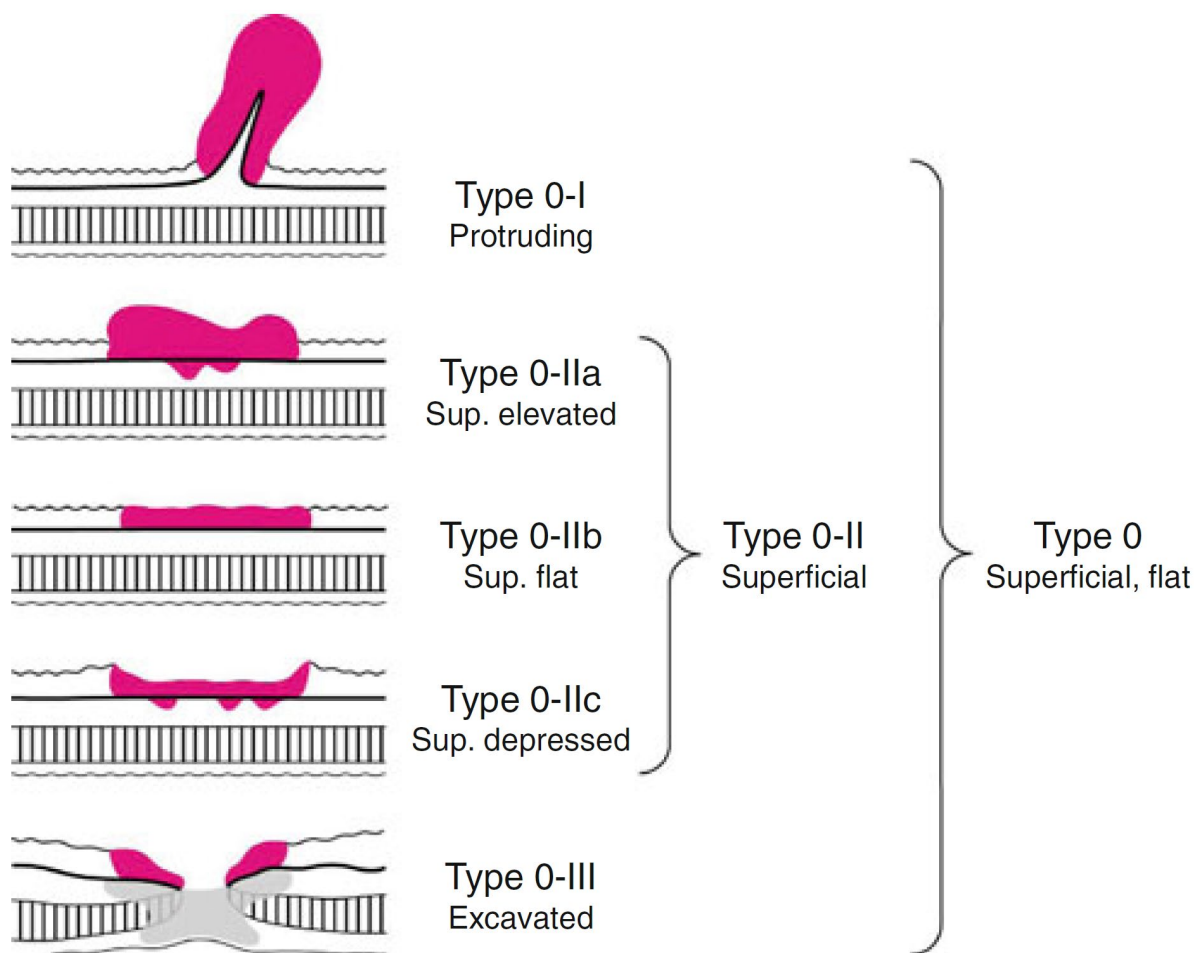


Figure 3: Subclassification of early gastric carcinoma (type 0). Reproduced with permission from Japanese Gastric Cancer Association, Sano T and Kodera Y (2011). *Japanese classification of gastric carcinoma: 3rd English Edition, Gastric Cancer*. Springer; London.¹⁴

↑ Back

Note 8 – Histological tumour type (Core and Non-core)

Several Classification schemes have been used for subtyping gastric carcinomas histologically, including the Laurén,¹⁹ Nakamura,¹³ JGCA,²⁰ WHO¹² (Table 3) and Ming²¹ Classifications. For consistency in reporting, the WHO Classification of Tumours of the Digestive System, 5th edition, is recommended (Tables 3-5).¹² However, if a carcinoma does not fit the WHO Classification for gastric carcinomas, a descriptive diagnosis should be given. The Laurén Classification is also widely used for gastric adenocarcinomas.¹⁹ In the Laurén Classification, gastric adenocarcinomas are simply divided into two histological subtypes - intestinal type and diffuse type.¹⁹ Gastric carcinomas that do not fit into one of these two histological subtypes are placed into the mixed or indeterminate categories. The Laurén Classification provides a simplified categorisation of common types of gastric carcinoma and facilitates a general understanding of pathogenesis of most gastric carcinomas.^{12,19,22} However, unlike the WHO Classification, the Laurén Classification is difficult to apply to all histologic gastric cancer subtypes and is therefore a non-core element.

A high incidence of intragastric recurrence is observed in certain histological subtypes including undifferentiated carcinoma and mixed adenocarcinoma with both signet ring cell carcinoma and poorly differentiated adenocarcinoma.²³

Table 3: Comparison of the Laurén, Nakamura, Japanese Gastric Cancer Association (JGCA) and 5th edition World Health Organization (WHO) Classification of gastric cancer. ²⁴

Laurén (1965)	Nakamura et al (1968)	JGCA (2017)	WHO (2019)
Intestinal	Differentiated	Papillary: pap Tubular 1, well differentiated: tub1 Tubular 2, moderately differentiated: tub2	Papillary Tubular, well differentiated Tubular, moderately differentiated
Indeterminate	Undifferentiated	Poorly 1 (solid type): por1	Tubular (solid), poorly differentiated
Diffuse	Undifferentiated	Signet-ring cell: sig Poorly 2 (non-solid type): por2	Poorly cohesive, signet-ring cell phenotype Poorly cohesive, other cell types
Intestinal/ diffuse/ indeterminate	Differentiated/ undifferentiated	Mucinous	Mucinous
Mixed		Description according to the proportion (e.g., por2>sig>tub2)	Mixed
Not defined	Not defined	Special type: Adenosquamous carcinoma Squamous cell carcinoma Undifferentiated carcinoma Carcinoma with lymphoid stroma Hepatoid adenocarcinoma Adenocarcinoma with enteroblastic differentiation Adenocarcinoma of fundic gland type	Other histological subtypes: Adenosquamous carcinoma Squamous cell carcinoma Undifferentiated carcinoma Carcinoma with lymphoid stroma Hepatoid adenocarcinoma Adenocarcinoma with enteroblastic differentiation Adenocarcinoma of fundic gland type Micropapillary adenocarcinoma

Reproduced with permission from Frayling I et al (2016). Association for Clinical Genetic Science (ACGS) Best practice guidelines for genetic testing and diagnosis of Lynch syndrome.

<https://www.acgs.uk.com/quality/best-practice-guidelines/>, derived from van Lier et al etc.; and from World Health Organization (WHO) Classification of Tumours Editorial Board. *WHO Classification of Tumours, Digestive System Tumours, 5th Edition*, 2019, IARC Press, Lyon.¹²

© World Health Organization/International Agency for Research on Cancer. Reproduced with permission.

Table 4: 5th edition of the World Health Organization histological classification of gastric carcinomas.¹²

Tumour type	Histologic features
Adenocarcinoma, main histologic types	
Tubular adenocarcinoma	Most common subtype; composed of dilated or slit-like branching tubules of variable diameter or acinar structures
Papillary adenocarcinoma	Exophytic growth pattern and most commonly well differentiated; composed of elongated finger-like processes lined by columnar or cuboidal cells supported by fibrovascular cores
Poorly cohesive carcinoma, including signet ring cell carcinoma and other subtypes	Accounting for 20-54% of gastric cancers; composed of neoplastic cells that are isolated or arranged in small aggregates without well-formed glands; either signet-ring cell type (composed predominantly or exclusively of signet-ring cells) or non-signet ring cell type with marked desmoplasia
Mucinous adenocarcinoma	Composed of malignant epithelium and extracellular mucin pools (mucin pools >50% of the tumour area)
Mixed adenocarcinoma	Composed of signet ring cell/poorly cohesive component and one or more other distinct histological components such as tubular/papillary carcinoma
Adenocarcinoma, other histological subtypes	
Gastric (adeno)carcinoma with lymphoid stroma	Characterised by irregular sheets, trabeculae, ill-defined tubules or syncytia of polygonal cells embedded within a prominent lymphocytic infiltrate, with intraepithelial lymphocytes; frequently associated with Epstein-Barr virus infection; less commonly associated with microsatellite instability or DNA mismatch repair deficiency
Hepatoid adenocarcinoma and related entities	Composed of large polygonal eosinophilic hepatocyte-like neoplastic cells with alpha fetoprotein (AFP) expression; other AFP-producing carcinomas including well differentiated papillary/tubular-type adenocarcinoma with clear cytoplasm, adenocarcinoma with enteroblastic differentiation and yolk-sac tumour-like carcinoma
Micropapillary adenocarcinoma	Composed of micropapillary component (10-90% of the tumour area) and tubular/papillary adenocarcinoma
Gastric adenocarcinoma of fundic-gland type	Likely develop from oxyntic gland adenoma with oxyntic gland differentiation; include chief-cell predominant (most common), parietal cell-predominant, and mixed phenotype
Rare histological subtypes	Mucoepidermoid carcinoma, paneth cell carcinoma, and parietal cell carcinoma
Gastric squamous cell carcinoma	Only composed of squamous cell carcinoma with no other histological component after thorough sampling
Gastric adenosquamous cell carcinoma	Admixture of adenocarcinoma and squamous cell carcinoma with the squamous cell component $\geq 25\%$
Gastric undifferentiated (anaplastic) carcinoma	Composed of diffuse sheets of anaplastic, large to medium size polygonal cells, with frequent pleomorphic tumour giant cells; other morphologies that may be seen include rhabdoid cell, sarcomatoid pleomorphic pattern, undifferentiated carcinoma

	with osteoclast-like giant cells, carcinoma with lymphoepithelioma-like feature, and a glandular component
Gastroblastoma	Composed of uniform spindle cells and uniform epithelial cells arranged in nests
Gastric neuroendocrine carcinoma (NEC)	
Small cell NEC	Resemble its lung counterpart; frequent necrosis
Large cell NEC	Resemble its lung counterpart; frequent necrosis
Mixed neuroendocrine-non-neuroendocrine neoplasm	
Mixed adenocarcinoma-NEC	Composed of both adenocarcinoma and NEC with each component $\geq 30\%$
Mixed adenocarcinoma-neuroendocrine tumour	Composed of both adenocarcinoma and neuroendocrine tumour with each component $\geq 30\%$

Table 5: 5th edition of the World Health Organization Classification of tumours of the stomach.¹²

Descriptor	ICD-O codes^a
Benign epithelial tumours and precursors	
Glandular intraepithelial neoplasia, low grade	8148/0
Glandular intraepithelial neoplasia, high grade	8148/2
Serrated dysplasia, low grade	8213/0*
Serrated dysplasia, high grade	8213/2*
Intestinal-type dysplasia	
Foveolar-type (gastric-type) dysplasia	
Gastric pit/crypt dysplasia	
Intestinal-type adenoma, low grade	8144/0*
Intestinal-type adenoma, high grade	8144/2*
Sporadic intestinal-type gastric adenoma	
Syndromic intestinal-type gastric adenoma	
Adenomatous polyp, low-grade dysplasia	8210/0*
Adenomatous polyp, high-grade dysplasia	8210/2*
Malignant epithelial tumours	
Adenocarcinoma not otherwise specified (NOS)	8140/3
Tubular adenocarcinoma	8211/3
Parietal cell carcinoma	8214/3
Adenocarcinoma with mixed subtypes	8255/3
Papillary adenocarcinoma NOS	8260/3
Micropapillary carcinoma NOS	8265/3
Mucoepidermoid carcinoma	8430/3
Mucinous adenocarcinoma	8480/3
Signet-ring cell carcinoma	8490/3

Descriptor	ICD-O codes ^a
Poorly cohesive carcinoma	8490/3
Medullary carcinoma with lymphoid stroma	8512/3
Hepatoid adenocarcinoma	8576/3
Paneth cell carcinoma	
Squamous cell carcinoma NOS	8070/3
Adenosquamous carcinoma	8560/3
Carcinoma, undifferentiated, NOS	8020/3
Large cell carcinoma with rhabdoid phenotype	8014/3
Pleomorphic carcinoma	8022/3
Sarcomatoid carcinoma	8033/3
Carcinoma with osteoclast-like giant cells	8035/3
Gastroblastoma	8976/3*
Neuroendocrine tumour NOS	8240/3
Neuroendocrine tumour, grade 1	8240/3
Neuroendocrine tumour, grade 2	8249/3
Neuroendocrine tumour, grade 3	8249/3
Gastrinoma NOS	8153/3
Somatostatinoma NOS	8156/3
Enterochromaffin-cell carcinoid	8241/3
ECL-cell carcinoid, malignant	8242/3
Neuroendocrine carcinoma NOS	8246/3
Large cell neuroendocrine carcinoma	8013/3
Small cell neuroendocrine carcinoma	8041/3
Mixed neuroendocrine-non-neuroendocrine neoplasm (MiNEN)	8154/3

^a These morphology codes are from the International Classification of Diseases for Oncology, third edition, second revision (ICD-O-3.2).²⁵ Behaviour is coded /0 for benign tumours; /1 for unspecified, borderline, or uncertain behaviour; /2 for carcinoma in situ and grade III intraepithelial neoplasia; and /3 for malignant tumours, primary site; and /6 for malignant tumours, metastatic site. Subtype labels are indented. Incorporates all relevant changes from the 5th edition Corrigenda, July 2024.²⁶

* Codes marked with an asterisk were approved by the International Agency for Research on Cancer/World Health Organization Committee for ICD-O at its meeting in April 2019.

© World Health Organization/International Agency for Research on Cancer. Reproduced with permission.

 **Back**

Note 9 – Histological tumour grade (Core)

The three-tiered grading system, applicable for tubular and papillary adenocarcinomas, is recommended by the UICC³ 9th edition/AJCC⁴ 8th edition Cancer Staging Systems as follows:

- G1: Well differentiated
- G2: Moderately differentiated
- G3: Poorly differentiated, undifferentiated

The AJCC 8th edition also recommends that the highest grade is recorded if there is evidence of more than one grade or level of differentiation of the tumour.⁴ The ICCR Stomach Endoscopic Resection DAC recommended that the UICC³/AJCC⁴ grading system for endoscopic specimens should be a core element because tumour grade may be more relevant in locally excised tumour specimens.

It is noted that the WHO Classification recommends a two-tiered system: low grade (well and moderately differentiated) and high grade (poorly differentiated).¹²

Histopathological grading does not independently affect patient survival after R0 resection; however, poor histopathological grade is associated with high rate of R1 and R2 resections.²⁷

As discussed in **Note 2 – ENDOSCOPIC PROCEDURE**, the criteria for ER are different between well/moderately differentiated and poorly/undifferentiated tumours. Some (but not all) studies have shown that poorly differentiated/undifferentiated mucosal and submucosal gastric cancer are associated with a high risk for lymphovascular invasion/lymph node metastasis.^{9,28,29}

 [Back](#)

Note 10 – Tissue layers present (Core)

Sometimes it is not possible to accurately stage the tumour when there are limited tissue layers present in ER specimens. For example, submucosal invasion cannot be determined if an ER specimen consists only of the mucosa with presence of cancer at the deep margin. Therefore, reporting the of tissue layers present in the specimen is very important and is a core element.

 [Back](#)

Note 11 – Extent of invasion (Core)

The term ‘carcinoma in situ’ is not commonly applied to glandular epithelium. However, high grade dysplasia (glandular intraepithelial neoplasia, high grade) in a gastric resection specimen is also reported as ‘carcinoma in situ’ as recommended by the UICC³ 9th edition/AJCC⁴ 8th edition Cancer Staging Systems mainly for tumour registry reporting purposes.

The depth of invasion is associated with increased risk of lymph node metastasis in early gastric cancer.⁹ Tumour invasion into the submucosa >500 µm (0.5 mm) from the muscularis mucosa has been reported as an independent risk factor for lymph node metastasis after noncurative ER.⁹ The depth of submucosal invasion is measured from the lower border of the muscularis mucosae to the point of the deepest tumour penetration. While submucosal invasion of <500 µm in depth has been included as one of the extended

criteria for ESD, other studies have suggested setting a different cutoff or dividing the submucosa invasion into superficial third (SM1), mid third (SM2) and deep third (SM3).^{30,31} However, a measurement is more accurate and less subjective than superficial, mid or deep third.

↑ Back

Note 12 – Lymphovascular invasion (Core)

Lymphovascular invasion is an independent predictor of lymph node metastasis in endoscopically resected early gastric cancers.^{32,33} Therefore, additional gastrectomy is recommended for patients who have ER showing lymphovascular invasion.

↑ Back

Note 13 – Margin status (Core)

For ER gastric carcinomas, margins include mucosal and deep margins. ER can be en bloc or piecemeal resection. Mucosal margin status is impossible to assess if it is a piecemeal resection with no orientation provided. At this stage no clear consensus on the definition of margin positivity has been reached. Presence or absence of low grade and high grade dysplasia at the mucosal margin should also be recorded.

↑ Back

Note 14 – Coexistent pathology (Non-core)

Based on the updated Sydney system, chronic gastritis is classified into *Helicobacter pylori* gastritis, ex-*Helicobacter pylori* gastritis, chemically induced/reactive gastritis, autoimmune gastritis and other special forms of gastritis.³⁴ *Helicobacter pylori* gastritis and autoimmune gastritis are recognised risk factors for gastric carcinoma. Both cause atrophic gastritis with intestinal metaplasia, which may develop into dysplasia/adenoma and further progresses into intestinal-type adenocarcinoma. In addition, pyloric gland adenoma may arise in a background of autoimmune atrophic gastritis,³⁵ which can also progress into gastric carcinoma.

Gastric polyps include fundic gland polyp, hyperplastic polyp and different types of adenoma. Hyperplastic polyps can be seen in the setting of long-term gastritis, and intestinal metaplasia may be seen in large hyperplastic polyps, which may progress into dysplasia and eventually into invasive carcinoma. Rarely dysplasia is seen in fundic gland polyps, but it almost never progresses to adenocarcinoma. Gastric adenomas include intestinal type, foveolar type, pyloric gland adenoma and oxyntic gland (chief cell) adenoma, all of which can progress to invasive carcinoma.¹²

Other risk factors associated with gastric carcinoma include previous gastric surgery and Epstein-Barr virus (EBV) infection. In addition, approximately 10% of gastric cancers develop in a familial/ hereditary setting, including hereditary diffuse gastric cancer in patients with *CDH1* or *CTBBA1* mutations, patients with Lynch syndrome with microsatellite instability (MSI)-high gastric cancer, familial intestinal gastric cancer, gastric adenocarcinoma, and proximal polyposis of the stomach due to germline mutations in promoter 1B of *APC*. Some patients with familial adenomatous polyposis can have multiple foveolar-type adenomas, which have a

potential to become invasive carcinoma but at a consistently low rate.¹² In addition, synchronous gastric carcinoma is rare; however, in one report from Asia, synchronous gastric cancer is seen in approximately 10% of gastric cancer patients.³⁶

 **Back**

Note 15 – Ancillary studies (Core and Non-core)

For gastric carcinomas with neuroendocrine differentiation, including gastric NECs and MiNENs, the reporting of neuroendocrine marker expression and Ki-67 proliferation index are core elements. These elements are non-core for other types of gastric carcinomas.

Gastric neuroendocrine neoplasms are classified into NETs, NECs and MiNENs. NETs are graded 1-3 using the mitotic count and Ki-67 proliferation index,¹² however pure NETs are not considered within the scope of this dataset. Most NECs show marked cytological atypia, brisk mitotic activity, and are subclassified into small cell and large cell subtypes. NECs are considered high grade by definition, typically with a Ki-67 proliferation index >55%.³⁷ MiNENs are usually composed of a poorly differentiated NEC component and an adenocarcinoma component. If a pure or mixed NEC is suspected on morphology, immunohistochemistry is required to confirm neuroendocrine differentiation, usually applying synaptophysin and chromogranin A as a minimum.¹²

PD-L1 expression and *HER2* amplification/overexpression are only useful for patients with advanced/metastatic gastric cancer. Therefore, these tests are not normally performed on the ER specimens but may be helpful for patients who develop metastases. Mismatch repair may be examined in patients where there is a suspicion for Lynch syndrome-associated gastric cancer, or to predict response to immune checkpoint inhibitor therapy, where appropriate.³⁸

Epstein-Barr virus (EBV) associated gastric cancer (EBVaGC) accounts for approximately 10% of total gastric cancers, most of which occur in men, and are located in the upper part of the stomach.³⁹ Histologically, EBVaGC is poorly differentiated, with abundant tumour-infiltrating lymphocytes. Morphologic features associated with EBVaGC include abundant tumour-infiltrating lymphocytes and Crohn disease-like reaction. Epstein-Barr encoding region (EBER) in situ hybridisation is widely used to identify EBVaGC, particularly for proximal gastric cancers with the above-mentioned demographic and morphologic features. Although EBVaGC can be poorly differentiated, EBVaGC is a distinct subtype with a low risk of lymph node metastasis.⁴⁰ Extension of the criteria for ESD in early EBVaGC is still under discussion.

Lymphovascular invasion is an independent predictor of lymph node metastasis in endoscopically resected early gastric cancers.^{32,33} However, immunohistochemical stains for lymphovascular markers are not routinely performed, unless there is a high histological suspicion of lymphovascular invasion.

 **Back**

Note 16 – Pathological staging (Core)

The UICC³ 9th edition/AJCC⁴ 8th edition Cancer Staging Systems for gastric carcinoma are recommended (Figure 4). However, staging is only applicable to specimens with sufficient tissue layers present.

Endoscopic resections (ERs) are one of the treatment options for early gastric carcinomas, therefore the 'y' stage is not applicable.

According to the UICC/AJCC convention, the designation 'T' refers to a primary tumour that has not been previously treated. High grade dysplasia in a gastric resection specimen is reported as 'carcinoma in situ' (Tis) as recommended by the UICC³ 9th edition/AJCC⁴ 8th edition Cancer Staging Systems mainly for tumour registry reporting purposes.

For ER only T1 and T2 are used, as ER specimens do not contain the subserosa but very rarely may contain superficial muscularis propria.

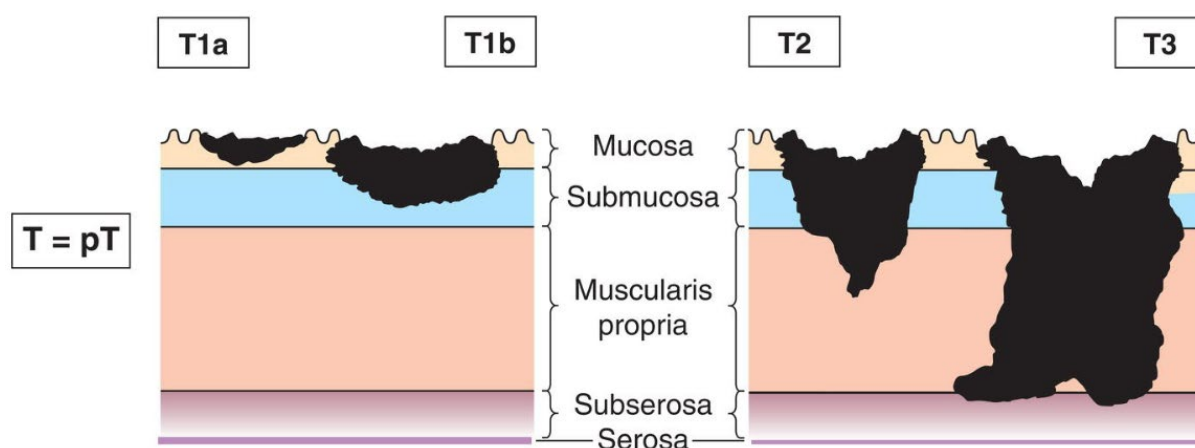


Figure 4: Primary tumour invasion. T1a: tumour that invades the lamina propria or muscularis mucosae, T1b: tumour that invades the submucosa, T2: tumour that invades the muscularis propria, T3: tumour that invades the subserosa. Used with permission of the Union for International Cancer Control (UICC). UICC TNM Atlas 7th edition.⁴¹

↑ Back

References

- 1 Merlin T, Weston A and Tooher R (2009). Extending an evidence hierarchy to include topics other than treatment: revising the Australian 'levels of evidence'. *BMC Med Res Methodol* 9:34.
- 2 International Collaboration on Cancer Reporting (2025). *Carcinoma of the Stomach Histopathology Reporting Guide, 3rd Edition*. Available from: <http://www.iccr-cancer.org/datasets/published-datasets/digestive-tract/carcinoma-of-the-stomach> (Accessed 11th December 2025).
- 3 Brierley JD, MGiliani M, O'Sullivan B, Rous B and Van Eycken E (eds) (2025). *Union for International Cancer Control. TNM Classification of Malignant Tumours, 9th Edition*, Wiley, USA.

- 4 Amin MB, Edge SB, Greene FL, Byrd DR, Brookland RK, Washington MK, Gershenwald JE, Compton CC, Hess KR, Sullivan DC, Jessup JM, Brierley JD, Gaspar LE, Schilsky RL, Balch CM, Winchester DP, Asare EA, Madera M, Gress DM and Meyer LR (eds) (2017). *AJCC Cancer Staging Manual. 8th Edition*, Springer, New York.
- 5 International Collaboration on Cancer Reporting (2025). *Carcinoma of the Oesophagus Histopathology Reporting Guide, 3rd Edition*. Available from: <http://www.iccr-cancer.org/datasets/published-datasets/digestive-tract/carcinoma-of-the-oesophagus> (Accessed 11th December 2025).
- 6 Hatta W, Gotoda T, Koike T and Masamune A (2019). History and future perspectives in Japanese guidelines for endoscopic resection of early gastric cancer. *Dig Endosc* 32:180–190.
- 7 Draganov PV, Wang AY, Othman MO and Fukami N (2019). AGA Institute clinical practice update: endoscopic submucosal dissection in the United States. *Clin Gastroenterol Hepatol* 17(1):16–25.e11.
- 8 Pimentel-Nunes P, Dinis-Ribeiro M, Ponchon T, Repici A, Vieth M, De Ceglie A, Amato A, Berr F, Bhandari P, Bialek A, Conio M, Haringsma J, Langner C, Meisner S, Messmann H, Morino M, Neuhaus H, Piessevaux H, Rugge M, Saunders BP, Robaszkiewicz M, Seewald S, Kashin S, Dumonceau JM, Hassan C and Deprez PH (2015). Endoscopic submucosal dissection: European Society of Gastrointestinal Endoscopy (ESGE) Guideline. *Endoscopy* 47(9):829–854.
- 9 Hatta W, Gotoda T, Koike T and Masamune A (2019). A recent argument for the use of endoscopic submucosal dissection for early gastric cancers. *Gut Liver* doi: 10.5009/gnl19194.
- 10 Japanese Gastric Cancer Association (2018). Japanese gastric cancer treatment guidelines 2018 (5th edition). *Gastric Cancer* doi: 10.1007/s10120-020-01042-y.
- 11 Ajani JA, D'Amico TA, Almhanna K, Bentrem DJ, Chao J, Das P, Denlinger CS, Fanta P, Farjah F, Fuchs CS, Gerdes H, Gibson M, Glasgow RE, Hayman JA, Hochwald S, Hofstetter WL, Ilson DH, Jaroszewski D, Johung KL, Keswani RN, Kleinberg LR, Korn WM, Leong S, Linn C, Lockhart AC, Ly QP, Mulcahy MF, Orringer MB, Perry KA, Poultides GA, Scott WJ, Strong VE, Washington MK, Weksler B, Willett CG, Wright CD, Zelman D, McMillian N and Sundar H (2016). Gastric Cancer, Version 3.2016, NCCN Clinical Practice Guidelines in Oncology. *J Natl Compr Canc Netw* 14(10):1286–1312.
- 12 Fukayama M, Rugge M and Washington MK (2019). Tumours of the stomach. In: *Digestive System Tumours. WHO Classification of Tumours, 5th Edition*, Lokuhetty D, White V, Watanabe R and Cree IA (eds), IARC Press, Lyon.
- 13 Nakamura K, Sugano H and Takagi K (1968). Carcinoma of the stomach in incipient phase: its histogenesis and histological appearances. *Gan* 59(3):251–258.
- 14 Sano T and Kodera Y (2011). Japanese classification of gastric carcinoma: 3rd English Edition. *Gastric Cancer* 14(2):101–112.
- 15 Petrelli F, Ghidini M, Barni S, Steccanella F, Sgroi G, Passalacqua R and Tomasello G (2017). Prognostic role of primary tumor location in non-metastatic gastric cancer: a systematic review and meta-analysis of 50 studies. *Ann Surg Oncol* 24(9):2655–2668.
- 16 Huang Q (2011). Definition of the esophagogastric junction: a critical mini review. *Arch Pathol Lab Med* 135(3):384–389.

- 17 Stein HJ, Feith M and Siewert JR (2000). Cancer of the esophagogastric junction. *Surg Oncol* 9(1):35–41.
- 18 Endoscopic Classification Review Group (2005). Update on the paris classification of superficial neoplastic lesions in the digestive tract. *Endoscopy* 37(6):570–578.
- 19 Lauren P (1965). The two histological main types of gastric carcinoma: diffuse and so-called intestinal-type carcinoma. An attempt at a histo-clinical classification. *Acta Pathol Microbiol Scand* 64:31–49.
- 20 Japanese Gastric Cancer Association (ed) (2017). *Japanese Classification of Gastric Carcinoma*, 15th Edition (in Japanese), Tokyo, Kanehara.
- 21 Ming SC (1977). Gastric carcinoma. A pathobiological classification. *Cancer* 39(6):2475–2485.
- 22 Lee S-M, Kim K-M and Ro YY (2012). Gastric carcinoma: morphologic classifications and molecular changes. In: *Gastric Carcinoma- New Insights into Current Management*, IntechOpen, London.
- 23 Park JC, Lee YK, Kim SY, Roh Y, Hahn KY, Shin SK, Lee SK, Lee YC, Kim HI, Cheong JH, Hyung WJ and Noh SH (2018). Long-term outcomes of endoscopic submucosal dissection in comparison to surgery in undifferentiated-type intramucosal gastric cancer using propensity score analysis. *Surg Endosc* 32(4):2046–2057.
- 24 WHO Classification of Tumours Editorial Board (2019). *Digestive System Tumours. WHO Classification of Tumours, 5th Edition, Volume 1*. IARC Press, Lyon.
- 25 Fritz A, Percy C, Jack A, Shanmugaratnam K, Sobin L, Parkin DM and Whelan S (eds) (2020). *International Classification of Diseases for Oncology, Third Edition, Second Revision ICD-O-3.2*. Available from:
http://www.iacr.com.fr/index.php?option=com_content&view=category&layout=blog&id=100&Itemid=577 (Accessed 11th December 2025).
- 26 WHO Classification of Tumours Editorial Board (2024). *Digestive System Tumours, WHO Classification of Tumours, 5th Edition, Volume 1 - Corrigenda August 2024*. Available from:
<https://publications.iarc.who.int/Book-And-Report-Series/Who-Classification-Of-Tumours/Digestive-System-Tumours-2019> (Accessed 11th December 2025).
- 27 Inoue K, Nakane Y, Michiura T, Nakai K, Iiyama H, Sato M, Okumura S, Yamamichi K and Hioki K (2002). Histopathological grading does not affect survival after R0 surgery for gastric cancer. *Eur J Surg Oncol* 28(6):633–636.
- 28 Lee SH, Kim MC, Jeon SW, Lee KN, Park JJ and Hong SJ (2019). Risk factors and clinical outcomes of non-curative resection in patients with early gastric cancer treated with endoscopic submucosal dissection: a retrospective multicenter study in Korea. *Clin Endosc* 53(2):196–205.
- 29 Lin JX, Wang ZK, Wang W, Desiderio J, Xie JW, Wang JB, Lu J, Chen QY, Cao LL, Lin M, Tu RH, Zheng CH, Li P, Parisi A, Zhou ZW and Huang CM (2019). Risk factors of lymph node metastasis or lymphovascular invasion for early gastric cancer: a practical and effective predictive model based on international multicenter data. *BMC Cancer* 19(1):1048.

- 30 Eom BW, Yu JS, Ryu KW, Kook MC, Kim YI, Cho SJ, Lee JY, Kim CG, Choi IJ, Yoon HM and Kim YW (2015). Optimal submucosal invasion of early gastric cancer for endoscopic resection. *Ann Surg Oncol* 22(6):1806–1812.
- 31 Hölscher AH, Drebber U, Mönig SP, Schulte C, Vallböhmer D and Bollschweiler E (2009). Early gastric cancer: lymph node metastasis starts with deep mucosal infiltration. *Ann Surg* 250(5):791–797.
- 32 Lee JH, Kim MG, Jung MS and Kwon SJ (2015). Prognostic significance of lymphovascular invasion in node-negative gastric cancer. *World J Surg* 39(3):732–739.
- 33 Li P, He HQ, Zhu CM, Ling YH, Hu WM, Zhang XK, Luo RZ, Yun JP, Xie D, Li YF and Cai MY (2015). The prognostic significance of lymphovascular invasion in patients with resectable gastric cancer: a large retrospective study from Southern China. *BMC Cancer* 15:370.
- 34 Stolte M and Meining A (2001). The updated Sydney system: classification and grading of gastritis as the basis of diagnosis and treatment. *Can J Gastroenterol* 15(9):591–598.
- 35 Park JY, Cornish TC, Lam-Himlin D, Shi C and Montgomery E (2010). Gastric lesions in patients with autoimmune metaplastic atrophic gastritis (AMAG) in a tertiary care setting. *Am J Surg Pathol* 34(11):1591–1598.
- 36 Isobe T, Hashimoto K, Kizaki J, Murakami N, Aoyagi K, Koufujii K, Akagi Y and Shirouzu K (2013). Characteristics and prognosis of synchronous multiple early gastric cancer. *World J Gastroenterol* 19(41):7154–7159.
- 37 Milione M, Maisonneuve P, Spada F, Pellegrinelli A, Spaggiari P, Albarello L, Pisa E, Barberis M, Vanoli A, Buzzoni R, Pusceddu S, Concas L, Sessa F, Solcia E, Capella C, Fazio N and La Rosa S (2017). The clinicopathologic heterogeneity of grade 3 gastroenteropancreatic neuroendocrine neoplasms: morphological differentiation and proliferation identify different prognostic categories. *Neuroendocrinology* 104(1):85–93.
- 38 Eso Y, Shimizu T, Takeda H, Takai A and Marusawa H (2020). Microsatellite instability and immune checkpoint inhibitors: toward precision medicine against gastrointestinal and hepatobiliary cancers. *J Gastroenterol* 55(1):15–26.
- 39 Murphy G, Pfeiffer R, Camargo MC and Rabkin CS (2009). Meta-analysis shows that prevalence of Epstein-Barr virus-positive gastric cancer differs based on sex and anatomic location. *Gastroenterology* 137(3):824–833.
- 40 Yanai H, Chihara D, Harano M, Sakaguchi E, Murakami T and Nishikawa J (2019). Epstein-Barr Virus-associated early gastric cancer treated with endoscopic submucosal dissection: a possible candidate for extended criteria of endoscopic submucosal dissection. *Intern Med* 58(22):3247–3250.
- 41 Brierley JD, Asamura H, Van Eycken E and Rous B (eds) (2021). *Union for International Cancer Control. TNM Atlas, 7th Edition*, Wiley, USA.