

Colorectal Cancer Histopathology Reporting Guide

Family/Last name Date of birth Given name(s) Patient identifiers Date of request Accession/Laboratory number Elements in **black text** are **CORE**. Elements in **grey text** are **NON-CORE**.

SCOPE OF THIS DATASET

 indicates multi-select values indicates single select values**CLINICAL INFORMATION** (select all that apply) (Note 1)

- Information not provided
- Known polyposis syndrome
- Familial adenomatous polyposis (FAP)
 - MUTYH*-associated polyposis (MAP)
 - Serrated polyposis
 - Other, *specify*
-
- Lynch syndrome
- Chronic inflammatory bowel disease
- Ulcerative colitis
 - Crohn disease
- Previous polyp(s)
- Previous colorectal cancer
- Other, *specify*
-

NEOADJUVANT THERAPY (Note 2)

- Information not provided
- Not administered
- Administered, *describe*
-

OPERATIVE PROCEDURE (Note 3)

- Total colectomy
- Proctocolectomy
- Right hemicolectomy
- Extended right hemicolectomy
- Transverse colectomy
- Left hemicolectomy
- Sigmoid colectomy
- Anterior resection
- High
 - Low
- Hartmann's procedure
- Abdominoperineal resection
- Other, *specify*
-

TUMOUR SITE^a (Note 4)

- Not specified
- Caecum
- Ascending colon
- Hepatic flexure
- Transverse colon
- Splenic flexure
- Descending colon
- Sigmoid colon
- Rectosigmoid^b
- Rectum
- Other, *specify*
-

^a If multiple primary tumours are present, separate datasets should be used to record this and all following elements for each primary tumour.^b Reserved for cases in which an accurate determination between rectum and sigmoid cannot be made by pathological assessment and clinical information regarding site is not available.**TUMOUR DIMENSIONS** (Note 5)

- Cannot be assessed
- Maximum tumour dimension
-
- Additional dimensions
-
- x
-

PERFORATION^c (Note 6)

- Not identified
- Present
- Through tumour (tumour perforation)
 - Not involving tumour

^c Defined as a macroscopically visible full thickness defect in the wall.**RELATION OF TUMOUR TO ANTERIOR PERITONEAL REFLECTION** (Note 7)

(Applicable to any specimen containing a rectal cancer e.g., anterior resection, abdominoperineal resection, proctocolectomy)

- Not applicable
- Entirely above
- Entirely below
- Astride

PLANE OF MESORECTAL EXCISION (Note 8)

(Applicable to any specimen containing a rectal cancer e.g., anterior resection, abdominoperineal resection, proctocolectomy)

- Not applicable
- Mesorectal fascia (complete)
- Intramesorectal (near complete)
- Muscularis propria (incomplete)

PLANE OF SPHINCTER EXCISION (Note 9)

(Applicable to abdominoperineal excision specimens only and should be reported in addition to the mesorectal plane)

- Extralevator plane
- Sphincteric plane
- Intrasphincteric plane

PLANE OF MESOCOLIC EXCISION (Note 10)

(Applicable to any specimen containing a colon cancer)

- Mesocolic plane
- Intramesocolic plane
- Muscularis propria plane

HISTOLOGICAL TUMOUR TYPE (Note 11)

(Value list from the World Health Organization Classification of Tumours of the Digestive System (2019))

- No evidence of residual tumour
- Adenocarcinoma not otherwise specified (NOS)
- Mucinous adenocarcinoma
- Signet-ring cell adenocarcinoma
- Medullary carcinoma
- Serrated adenocarcinoma
- Micropapillary adenocarcinoma
- Adenoma-like adenocarcinoma
- Neuroendocrine carcinoma
 - Small cell type
 - Large cell type
- Mixed neuroendocrine-non-neuroendocrine neoplasm (MiNEN)
- Other, specify

HISTOLOGICAL TUMOUR GRADE (Note 12)

(Only adenocarcinoma NOS and mucinous adenocarcinoma should be graded)

- Not applicable
- Low grade (formerly well to moderately differentiated)
- High grade (formerly poorly differentiated)

EXTENT OF INVASION (Note 13)

- Cannot be assessed
- No evidence of primary tumour
- High grade dysplasia/non-invasive neoplasia
- Invasion into submucosa
- Invasion into muscularis propria
- Invasion into subserosa or into pericolic or perirectal connective tissues
- Invasion onto the surface of the visceral peritoneum
- Invasion directly into other structures/organs, specify

MEASUREMENT OF INVASION BEYOND MUSCULARIS PROPRIA (Note 14)

(Only applicable to pT3 tumours)

- Cannot be assessed

Distance of invasion beyond the muscularis propria, to nearest 1 mm mm

LYMPHATIC AND VENOUS INVASION (Note 15)

- Not identified
- Present
 - Small vessel (lymphatic, capillary or venular)
 - Large vessel (venous)
 - Intramural
 - Extramural

PERINEURAL INVASION (Note 16)

- Not identified
- Present

LYMPH NODE STATUS (Note 17)

- Cannot be assessed
- No nodes submitted or found

Number of lymph nodes examined

- Not involved

Involved
Number of involved lymph nodes

TUMOUR DEPOSITS (Note 18)

- Not identified
- Present

Number of tumour deposits

TUMOUR BUDDING (Note 19)

(Should only be reported in non-mucinous and non-signet ring cell adenocarcinoma areas)

- Cannot be assessed

Number of tumour buds^d

Tumour budding score

- Bd1 - low budding (0-4 buds)
- Bd2 - intermediate budding (5-9 buds)
- Bd3 - high budding (≥10 buds)

^d After scanning 10 fields on a 20x objective lens, the hotspot field normalised to represent a field of 0.785 mm².

RESPONSE TO NEOADJUVANT THERAPY (Note 20)

- No neoadjuvant treatment
- Complete response – no viable cancer cells (score 0)
- Near complete response – single cells or rare groups of cancer cells (score 1)
- Partial response – residual cancer with evident tumour regression (score 2)
- Poor or no response – extensive residual cancer with no evident tumour regression (score 3)
- Cannot be assessed, *specify*

MARGIN STATUS (Note 21)

Longitudinal margin status

- Cannot be assessed
- Not involved, *estimate distance to closer margin^e*

 mm

- Involved, *specify proximal or distal margin^e*

^e Includes assessment of any separately submitted anastomotic ring(s).

Circumferential margin status

- Cannot be assessed
- Not involved, *specify distance to nearest 1 mm or ≥10 mm*

 mm OR ≥10 mm

- Involved (≤1 mm), *specify 0 mm or distance to nearest 0.1 mm*

 mm

- By primary tumour
- By other, *specify*

COEXISTENT PATHOLOGY (select all that apply) (Note 22)

- None identified
- Polyp(s), *specify*

- Synchronous carcinoma(s), *specify*

- Other, *specify*

ANCILLARY STUDIES (select all that apply) (Note 23)

For neuroendocrine neoplasms only

- Not applicable
- Neuroendocrine markers, *specify result(s) if available*

AND

Ki-67 proliferation index %

Mismatch repair (MMR) immunohistochemistry

- Not tested
- Not interpretable
- MMR proficient
- MMR deficient
 - MLH1/PMS2 loss*
 - MSH2/MSH6 loss*
 - MSH6 loss*
 - PMS2 loss*
 - Other, specify*

MMR status by microsatellite instability (MSI) testing

- Not tested
- Test failed
- MSI-high
- MSI-low
- MS-stable

BRAF V600E mutation testing

- Not tested
- Test failed
- Mutated
- Wild type

MLH1 promoter methylation testing

- Not tested
- Test failed
- Methylated
- Not methylated
- Inconclusive

Other, specify

HISTOLOGICALLY CONFIRMED DISTANT METASTASES (Note 24)

- Not identified
- Present, *specify site(s)*

PATHOLOGICAL STAGING (UICC TNM 8th edition)^f (Note 25)

TNM Descriptors (only if applicable) (select all that apply)

- m - multiple primary tumours
- r - recurrent
- y - post-therapy

Primary tumour (pT)

- TX Primary tumour cannot be assessed
- T0 No evidence of primary tumour
- Tis^g Carcinoma in situ: invasion of lamina propria
- T1 Tumour invades submucosa
- T2 Tumour invades muscularis propria
- T3 Tumour invades subserosa or into non-peritonealized pericolic or perirectal tissues
- T4 Tumour directly invades other organs or structures and/or perforates^h visceral peritoneum
 - T4a Tumour perforates visceral peritoneumⁱ
 - T4b Tumour directly invades other organs or structures^{j,k}

^g Use of the category pTis is not approved in this dataset.

^h Perforation in this context implies penetration of the visceral peritoneum.

ⁱ Invades through to visceral peritoneum to involve the surface.

^j Direct invasion in T4b includes invasion of other organs or segments of the colorectum by way of the serosa, as confirmed on microscopic examination, or for tumours in a retroperitoneal or subperitoneal location, direct invasion of other organs or structures by virtue of extension beyond the muscularis propria.

^k Tumour that is adherent to other organs or structures, macroscopically, is classified cT4b. However, if no tumour is present in the adhesion, microscopically, the classification should be pT1-3, depending on the anatomical depth of wall invasion.

Regional lymph nodes (pN)

- NX Regional lymph nodes cannot be assessed
- N0 No regional lymph node metastasis
- N1 Metastasis in 1 to 3 regional lymph nodes
 - N1a Metastasis in 1 regional lymph node
 - N1b Metastasis in 2 to 3 regional lymph nodes
 - N1c Tumour deposit(s), i.e., satellites,^l in the subserosa, or in non-peritonealized pericolic or perirectal soft tissue without regional lymph node metastasis
- N2 Metastasis in 4 or more regional lymph nodes
 - N2a Metastasis in 4-6 regional lymph nodes
 - N2b Metastasis in 7 or more regional lymph nodes

^l Tumour deposits (satellites) are discrete macroscopic or microscopic nodules of cancer in the pericolorectal adipose tissue's lymph drainage area of a primary carcinoma that are discontinuous from the primary and without histological evidence of residual lymph node or identifiable vascular or neural structures.

Distant metastasis (pM)

- M0^m No distant metastasis
- M1 Distant metastasis
 - M1a Metastasis confined to one organ (liver, lung, ovary, non-regional lymph node(s)) without peritoneal metastasis
 - M1b Metastasis in more than one organ
 - M1c Metastasis to the peritoneum with or without other organ involvement

^m No pathological stage use clinical stage cM0.

^f Reproduced with permission. Source: UICC TNM Classification of Malignant Tumours, 8th Edition, eds by James D. Brierley, Mary K. Gospodarowicz, Christian Wittekind. 2016, Publisher Wiley-Blackwell.

Definitions

CORE elements

CORE elements are those which are essential for the clinical management, staging or prognosis of the cancer. These elements will either have evidentiary support at Level III-2 or above (based on prognostic factors in the National Health and Medical Research Council levels of evidence¹). In rare circumstances, where level III-2 evidence is not available an element may be made a CORE element where there is unanimous agreement in the expert committee. An appropriate staging system e.g., Pathological TNM staging would normally be included as a CORE element.

The summation of all CORE elements is considered to be the minimum reporting standard for a specific cancer.

NON-CORE elements

NON-CORE elements are those which are unanimously agreed should be included in the dataset but are not supported by level III-2 evidence. These elements may be clinically important and recommended as good practice but are not yet validated or regularly used in patient management.

Key information other than that which is essential for clinical management, staging or prognosis of the cancer such as macroscopic observations and interpretation, which are fundamental to the histological diagnosis and conclusion e.g., macroscopic tumour details, may be included as either CORE or NON-CORE elements by consensus of the Dataset Authoring Committee.

Scope

The dataset has been developed for the reporting of surgical resection specimens from patients with primary carcinoma of the colon and rectum, including neuroendocrine carcinomas (NECs) and mixed neuroendocrine-non-neuroendocrine neoplasms (MiNENs).² It is not applicable to carcinomas of the small intestine, appendix or anus, nor to neuroendocrine tumours (NETs) or non-epithelial malignancies.

Primary colorectal carcinomas treated by local excision are dealt with in a separate dataset.

[↑ Back](#)

Note 1 – Clinical information (Non-core)

Clinical information can be provided by the clinician on the endoscopy report or the pathology request form. Pathologists could search for additional information from possible previous pathology reports. The presence of a known polyposis syndrome, Lynch syndrome, chronic inflammatory bowel disease or any other relevant gastrointestinal disorder should be recorded and provided to the pathologist, as awareness of such underlying conditions may influence both specimen sampling and histological interpretation.

[↑ Back](#)

Note 2 – Neoadjuvant therapy (Core)

Given implications for staging and interpretation of morphological features related to the primary tumour, it is important that clinical information is provided to the pathologist regarding the application of any neoadjuvant therapy, and details of such therapy, for example radiotherapy and/or chemotherapy, duration and timing in relation to surgery.

↑ Back

Note 3 – Operative procedure (Core and Non-core)

Information regarding the nature of the operative procedure should be provided, with any refinements as necessary, for example the attempted dissection plane in an abdominoperineal resection. Should the operative specimen include any tissue or organ not typically submitted within that specimen type, for example en bloc resection of a segment of intestine or abdominal wall connective tissue, this should be clearly indicated. Inclusion of the peritoneal reflection within an anterior resection specimen distinguishes a low anterior resection from a high anterior resection.

↑ Back

Note 4 – Tumour site (Core)

If multiple primary tumours are present, separate datasets should be used to record tumour site and all following elements for each primary tumour. Determination of tumour site is based on clinical information provided on the pathology request form combined with specimen assessment by the pathologist. Any significant discrepancy should be discussed with the clinical team and the tumour site clearly documented by specimen photography. Recording the anatomical site of tumour allows correlation with prior endoscopic and radiological investigations, indicates whether or not a non-peritonealised margin is likely to be present and defines the presence of regional versus non-regional lymph nodes. In particular, distinction of colonic from rectal origin is of importance, given different biologies, clinical features and management. Every effort should be made, therefore, to accurately classify a tumour as colonic or rectal in origin.

If a tumour straddles two sites, the site with the greatest tumour bulk should be recorded. The three taeniae coli of the sigmoid colon fuse to form the circumferential longitudinal muscle of the rectal wall, marking the rectosigmoid boundary. If distinction between the sigmoid colon and rectum is not possible by pathological assessment, for example owing to advanced tumour stage obliterating anatomical landmarks, the tumour site can be recorded based on clinical information available. Classification as rectosigmoid should be reserved for cases in which an accurate determination between rectum and sigmoid cannot be made by pathological assessment and clinical information regarding site is not available.

↑ Back

Note 5 – Tumour dimensions (Core and Non-core)

No prognostic significance has been attached to tumour size for colorectal cancer and size does not directly influence tumour staging. Recording of size, based on a combination of macroscopic and microscopic assessment, allows correlation with pre-operative imaging, endoscopic and surgical assessments. Assessment of tumour dimensions should, if possible, exclude any inflammatory component or pre-invasive lesion, a separate measurement of which may be provided.

↑ Back

Note 6 – Perforation (Core)

Perforation through the tumour into the peritoneal cavity is a well-established adverse prognostic factor in colonic³ and rectal⁴ cancer and should be recorded. Tumour perforation is defined as a macroscopically visible full thickness defect through the tumour, such that the bowel lumen within the segment involved by tumour is in communication with the external surface of the resection specimen or with the lumen of another organ. Such cases are regarded as pT4a in the Union for International Cancer Control (UICC)/American Joint Committee on Cancer (AJCC) 8th edition Staging Systems.^{5,6} The term perforation should be reserved for the biological setting and, for clarity, different descriptive terminology applied should a full thickness defect in the specimen arise intra-operatively. Such clinical information should be conveyed to the reporting pathologist to assist pathological interpretation. If an iatrogenic full thickness defect in the tumour occurs whilst the specimen is in situ within the abdominal cavity, this is best regarded as pT4a disease, given the risk of tumour seeding the peritoneal cavity. This interpretation is however offered without good evidence. If such an iatrogenic defect occurs once the specimen is outside the abdominal cavity, the defect should not influence pT classification. An explanatory note regarding interpretation should be provided in the pathology report.

Peritumoural abscess cavity, for example within the mesentery, that is contained and does not demonstrate breach of the serosal surface, should not be considered perforation and is considered pT3 rather than pT4a. Perforation of the colon as a result of a more distal obstructing tumour is distinct from tumour perforation and does not indicate pT4 disease, but nevertheless should be recorded as it is associated with high mortality risk.

↑ Back

Note 7 – Relation of tumour to anterior peritoneal reflection (Core)

For rectal tumours only, the relationship of the tumour to the anterior peritoneal reflection must be recorded, as this predicts the risk of local recurrence in addition to peritoneal recurrence (Figure 1).⁷ The anterior aspect of the rectum is covered by peritoneum down to level of the peritoneal reflection. Posteriorly, the non-peritonealised margin extends upwards as a triangular shaped bare area containing the rectal arteries. Superiorly this area is continuous with the sigmoid mesocolon.

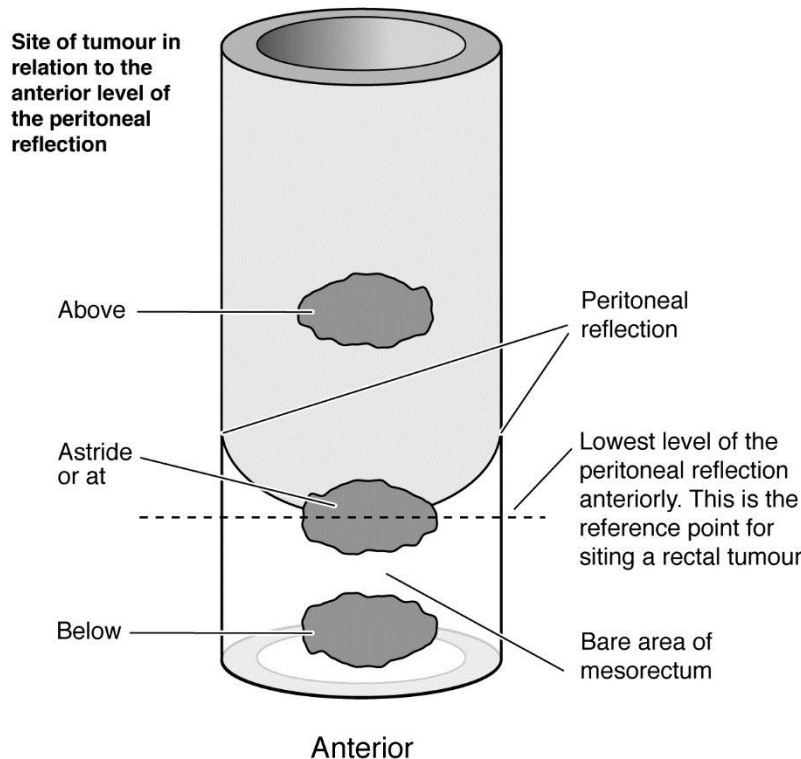


Figure 1: Site of tumour in relation to the anterior level of the peritoneal reflection. Reproduced with permission from Royal College of Pathologists of Australasia (2016). *Colorectal cancer structured reporting protocol, 3rd Edition*. RCPA, Australia.⁸

↑ Back

Note 8 – Plane of mesorectal excision (Core)

The quality of surgical technique has been shown by prospective randomised controlled trials to predict outcome following surgical treatment for rectal cancer. Total mesorectal excision (TME) surgery improves local recurrence rates and the corresponding survival by up to 20%.^{9,10} Macroscopic evaluation of the completeness of the mesorectum, by objective assessment of the surgical plane of excision, predicts margin involvement, local recurrence and survival.^{7,11} Excision in the mesorectal plane (complete TME) has the best outcome while excision extending onto the muscularis propria (incomplete TME) has the worst.

Assessment requires examination of the intact specimen and overall assessment is based on the worst area, as described below:

Mesorectal fascia (complete)

- Intact bulky mesorectum with a smooth surface
- Only minor irregularities of the mesorectal surface
- No surface defects greater than 5 millimetres (mm) in depth
- No coning towards the distal margin of the specimen

Intramesorectal (near complete)

- Moderate bulk to the mesorectum
- Irregularity of the mesorectal surface with defects greater than 5 mm, but none extending to the muscularis propria
- Moderate coning may be evident distally
- No areas of visibility of the muscularis propria except at the insertion site of the levator ani muscles

Muscularis propria (incomplete)

- Little bulk to the mesorectum
- Defects in the mesorectum down to the muscularis propria
- After transverse sectioning, the circumferential margin appears very irregular and is formed by muscularis propria in areas.

 [Back](#)

Note 9 – Plane of sphincter excision (Non-core)

Abdominoperineal excision for low rectal cancer has been associated with poorer outcomes compared to anterior resection for higher tumours due to increased rates of circumferential resection margin (CRM) involvement and intraoperative full thickness defects (“perforations”).¹² Extralevator abdominoperineal excision has been shown in meta-analyses to reduce CRM involvement and intraoperative full thickness defects leading to better long term outcomes.¹³ This is due to the removal of more tissue around the tumour.¹⁴ Radiologists are able to predict the optimal dissection plane in abdominoperineal excision from the staging magnetic resonance imaging (MRI).¹⁵ This should be correlated with the plane of dissection achieved on the resection specimen around the sphincters (below the mesorectum). The plane of surgery in the mesorectum should be assessed separately. Assessment requires examination of the intact specimen and overall assessment is based on the worst area, as described below:⁴

Extralevator plane

- Dissection plane lies external to the external sphincter and levator ani muscles, which are removed en bloc with the mesorectum and anal canal
- Cylindrical-shaped specimen with the levators forming an extra protective layer above the sphincters
- No significant defects into the sphincter muscles or levators

Sphincteric plane

- Dissection plane lies on the surface of the sphincter muscles
- No levator ani muscle attached or only a very small cuff leading to coning or surgical waisting at the level of puborectalis
- No significant defects into the sphincter muscles

Intrasphincteric plane

- Dissection plane lies within the sphincter muscles or even deeper into the submucosa
- Full thickness iatrogenic defect of the specimen at any point below the peritoneal reflection.

↑ Back

Note 10 – Plane of mesocolic excision (Non-core)

The quality of surgical technique in the mesocolon has been shown, in retrospective observational studies and one randomised clinical trial, to predict outcome following surgical treatment for colon cancer in a similar way to that seen in rectal cancer.^{16,17} Surgery in the mesocolic plane is associated with a lower rate of local recurrence and better survival when compared to surgery in the muscularis propria plane. Complete mesocolic excision, where surgery occurs in the mesocolic plane with a high vascular ligation, is associated with better plane of surgery and more lymph nodes, although the effect of the high ligation on long term outcomes remains debated.¹⁸ The height of the vascular ligation is not taken into consideration during the plane of mesocolic excision assessment.

Assessment requires examination of the intact specimen and overall assessment is based on the worst area, as described below:¹⁷

Mesocolic plane

- Smooth surface to the mesocolon (mesocolic fascia and peritoneum)
- Only minor irregularities
- No surface defects greater than 5 mm in depth

Intramesocolic plane

- Irregularity of the mesocolic surface with defects greater than 5 mm, but none extending to the muscularis propria

Muscularis propria plane

- Defects in the mesocolon down to the muscularis propria
- After transverse sectioning, the mesocolic margin is irregular and formed by muscularis propria in areas.

↑ Back

Note 11 – Histological tumour type (Core)

Colorectal cancers should be typed according to the World Health Organization (WHO) Classification of Tumours of the Digestive System, 5th edition, 2019.² Almost all are adenocarcinomas. Most colorectal adenocarcinomas are of no specific type (not otherwise specified (NOS)) but some subtypes of adenocarcinoma are defined as follows:

Mucinous adenocarcinoma classification requires greater than 50% of the tumour to comprise pools of extracellular mucin containing malignant glands or individual tumour cells. Microsatellite instability is present in a higher proportion compared to adenocarcinoma NOS. Tumours with less than 50% mucinous content are described as having a mucinous component.

Signet-ring cell adenocarcinoma classification requires greater than 50% of the tumour to demonstrate single malignant cells with intracytoplasmic mucin, displacing and typically indenting the nuclei, imparting signet-ring cell morphology. Signet-ring cell carcinoma has stage-independent adverse prognostic significance relative to conventional adenocarcinoma.¹⁹ There is a strong association with microsatellite instability and with Lynch syndrome.²⁰ Tumours with less than 50% signet-ring cell content are described as having a signet-ring cell component.

Medullary carcinoma is characterised by sheets of malignant cells with indistinct cell boundaries, vesicular nuclei, prominent nucleoli, abundant eosinophilic cytoplasm and prominent intratumoural lymphocytes and neutrophils. These tumours almost invariably demonstrate microsatellite instability and are associated with a good prognosis.²¹

Serrated adenocarcinoma shares morphological similarities with precursor serrated polyps, demonstrating glandular serrations, which are often slit-like, abundant eosinophilic or clear cytoplasm, minimal necrosis and sometimes areas of mucinous differentiation.²²

Micropapillary adenocarcinoma is characterised by small, rounded clusters of tumour cells lying within stromal spaces mimicking vascular channels. At least 5% of the tumour should demonstrate this feature to classify as micropapillary adenocarcinoma. This pattern is most frequently encountered alongside adenocarcinoma NOS. There is a strong association with adverse pathological features including a high risk of lymph node metastatic disease.²³

Adenoma-like adenocarcinoma is defined as an invasive adenocarcinoma in which at least 50% of the invasive tumour has an adenoma-like appearance with villous architecture, low grade cytology, a pushing growth pattern and minimal desmoplastic stromal reaction.²⁴ Diagnosis of adenocarcinoma on endoscopic biopsy is exceedingly difficult. This variant is associated with a good prognosis.

Neuroendocrine neoplasms are classified into NETs, NECs and MiNENs.² NETs are graded 1-3 using the mitotic count and Ki-67 proliferation index. Pure NETs are not considered within the scope of this dataset. NECs show marked cytological atypia, brisk mitotic activity, and are subclassified into small cell and large cell subtypes. NECs are considered high-grade by definition. A Ki-67 proliferation index <55% is associated with better overall survival.²⁵ MiNENs are usually composed of a poorly differentiated NEC component and an adenocarcinoma component.

Other epithelial tumours rarely encountered include adenosquamous carcinoma, carcinoma with sarcomatoid components, undifferentiated carcinoma, squamous cell carcinoma and non-signet-ring cell poorly cohesive adenocarcinoma. Many of these are extremely rare.

 [Back](#)

Note 12 – Histological tumour grade (Core)

Despite low level of interobserver agreement,²⁶ histological grade is an independent prognostic factor used in risk assessment models for colorectal carcinoma.²⁷⁻²⁹ Various grading systems have been used over the years. A two-tiered grading system is more reproducible and more prognostically relevant than a four-tiered grading system. For consistency with the latest WHO Classification,² grading should be based on the least differentiated component of the tumour, although there is no good evidence to support this stance and a minimum area of high grade tumour required for this classification has not been defined. Tumour buds or poorly differentiated clusters, most commonly seen at the invasive tumour front, should not be considered in the evaluation of grade. Emerging data suggests that grading based on poorly differentiated clusters is superior to conventional grading with respect to both prognostic value and reproducibility.^{30,31}

Only adenocarcinoma NOS and mucinous adenocarcinoma should be graded. Grading is not applicable to other subtypes of adenocarcinoma, as grading by gland formation is difficult to apply to subtypes and most of these are associated with their own clinical prognosis e.g., bad for signet-ring cell adenocarcinoma and good for adenoma-like adenocarcinoma. Mucinous adenocarcinoma should be graded on glandular formation and epithelial maturation.² Tumour mismatch repair status is likely to influence clinical behaviour of some histological tumour types, including mucinous adenocarcinoma, but some studies have found morphological grading superior to mismatch repair status for prognostication of mucinous adenocarcinomas.^{32,33}

↑ Back

Note 13 – Extent of invasion (Core)

The anatomic extent of tumour invasion, based on a combination of macroscopic and microscopic assessment of an excision specimen, is the most important prognostic factor in colorectal cancer. pT classification indicates the extent of invasion of the primary tumour in the absence of application of neoadjuvant therapy. Criteria of the UICC and AJCC 8th editions^{5,6} are applied, with the exception that pT in situ is not recognised. Rare cases of colorectal neoplasia confined to invasion of the lamina propria (intramucosal invasive neoplasia or intramucosal carcinoma) are acknowledged but, given the negligible metastatic potential of such neoplasms,³⁴ these should be classified under the same category with high grade dysplasia/high grade non-invasive neoplasia.

pT1 indicates tumour extension beyond muscularis mucosae into submucosa, but without involvement of muscularis propria. Further consideration of pT1 colorectal carcinoma is provided in a separate local excision dataset.

pT2 indicates extension into muscularis propria but not beyond. In the low rectum, the internal sphincter represents a continuation of the muscularis propria and invasion of this also constitutes pT2. Note that skeletal muscle fibres can cross over from external to internal sphincter and invasion of skeletal muscles fibres of the internal sphincter is also classified as pT2. Such complexities of sphincter anatomy make accurate assessment of level of invasion in this region challenging.

pT3 indicates tumour spread beyond muscularis propria in continuity with the primary tumour and excluding tumour confined to the lumen of veins or lymphatic channels. Distinction from pT2 may be difficult if tumour extends to the outer edge of the muscularis propria. If no muscle separates tumour cells from mesenteric connective tissue, the tumour should be classified as pT3.³⁵ Invasion beyond

internal sphincter into the intrasphincteric plane, but not involving the external sphincter, is considered pT3.

pT4 encompasses either tumour infiltration of the peritoneal surface (pT4a) or tumour involvement of an adjacent organ (pT4b). Peritoneal involvement has been demonstrated by multivariate analysis to have a negative impact on prognosis.^{36,37} Although some small studies have suggested that peritoneal involvement was associated with worse outcome than invasion of adjacent organs, data from a large cohort of more than 100,000 colon cancer cases indicate that penetration of the visceral peritoneum carries a 10-20% better 5-year survival than locally invasive carcinomas for each pN category.³⁸

Involvement of the peritoneal surface (pT4a) is defined as tumour breaching the serosa with tumour cells visible either on the peritoneal surface, free in the peritoneal cavity or separated from the peritoneal surface by inflammatory cells only.³ Should tumour pass close to the serosal surface and elicit a mesothelial reaction but no clear invasion, additional sections and/or multiple levels should be examined. If tumour does not demonstrate serosal involvement after additional evaluation, it should be categorised as pT3. Assessment of this scenario remains prone to interobserver variation.³⁹ Several studies advocate the application of elastic stains to evaluate peritoneal elastic lamina invasion, as a staging or prognostic tool, but others have not found this useful.⁴⁰⁻⁴³ Cases with perforation through tumour should also be classified as pT4a, even in the absence of microscopic documentation of tumour cells on the peritoneal surface. This does not apply to colonic or rectal perforation distant from the tumour, for example secondary to distal obstruction.

Note pT4a implies peritoneal involvement through direct continuity with the primary tumour whereas peritoneal deposition of tumour discontinuous from the primary tumour is regarded as distant metastatic disease (pM1c). It is also important to carefully distinguish involvement of a peritoneal surface from involvement of a non-peritonealised surgical resection margin, which is recorded separately. The first is a risk factor for intraperitoneal metastatic disease while the latter is a risk factor for local recurrence.

Tumour involvement of an adjacent organ (pT4b) may follow peritoneal invasion or represent direct extraperitoneal invasion, for example in low rectal tumours. Tumours adherent to other organs must be demonstrated microscopically to show invasion into the adjacent organ, rather than inflammatory adherence, to be classified as pT4b. Intramural (longitudinal) tumour extension into an adjacent part of the intestine does not influence pT classification, for example intramural extension of a caecal tumour into the terminal ileum or of a rectal tumour into the anal canal. Tumour involvement of greater omentum is considered pT4b if it follows transperitoneal invasion. Rarely, a transverse colonic tumour can invade greater omentum directly without breaching the serosa, meriting classification as pT3 rather than pT4b. For rectal tumours, invasion of skeletal muscle of the external sphincter and/or levator ani is classified as pT4b.

 [Back](#)

Note 14 – Measurement of invasion beyond muscularis propria (Non-core)

Tumours classified as pT3 can be prognostically stratified accordingly to their extent of invasion beyond muscularis propria, with 5 mm an important cut-off in some studies.^{44,45} This distance should be measured to the nearest mm from the outer margin of the muscularis propria, reconstructing this margin if necessary in the event of destruction by tumour. Note this measurement applies only to the primary tumour and any discontinuous tumour foci, of any form, should be discounted in this assessment.

↑ Back

Note 15 – Lymphatic and venous invasion (Core)

For colorectal cancer, it is important to report the presence or absence of lymphovascular invasion and to classify this further according to the type of vessels involved and, for veins, their intramural or extramural location, as these features may have different clinical and prognostic implications. Extramural (beyond muscularis propria) venous invasion has been demonstrated on multivariate analysis by multiple studies to be a stage independent adverse prognostic factor for colonic and rectal cancer.⁴⁶ There is also evidence from several studies that intramural (intramuscular or submucosal) venous spread is also of prognostic importance but the evidence is much weaker than for extramural venous invasion.^{3,47,48}

Venous invasion is defined as tumour present within an endothelium-lined space that is either surrounded by a rim of muscle or contains red blood cells.⁴⁹ It should be suspected in the presence of a rounded or elongated deposit of tumour beside an artery. Interpretation of such features is subjective and can be improved by the application of immunohistochemical and histochemical stains, in particular elastic staining to identify venous elastic lamina.^{48,50-54} A circumscribed tumour nodule surrounded by a smooth muscle wall or an identifiable elastic lamina, evident on haematoxylin and eosin (H&E) or elastic stains, is considered sufficient to classify as venous invasion. Examination of multiple levels in blocks showing features suspicious of venous invasion can also be helpful in borderline cases.

Small vessel invasion should be reported separately from venous (large vessel) invasion. Small vessel invasion is defined as tumour involvement of thin-walled structures lined by endothelium, without an identifiable smooth muscle layer or elastic lamina. Small vessels may represent lymphatics, capillaries or post-capillary venules. Lymphatics and venules may be distinguished by D2-40 immunohistochemistry, which only stains lymphatic endothelial cells, not venular, but this is not routinely recommended in reporting surgical resection specimens. All forms of small vessel invasion are considered under the 'L' classification under UICC/AJCC TNM 8th editions.^{5,6} Small vessel invasion is associated with lymph node metastatic disease and has been shown to be an independent indicator of adverse outcome in some but not all studies.^{47,55-57} A higher prognostic significance of extramural small vessel invasion has been suggested, but the importance of anatomic location in small vessel invasion is not well established.⁴⁷

↑ Back

Note 16 – Perineural invasion (Core)

Multiple independent studies and one meta-analysis have demonstrated the adverse prognostic implication of perineural invasion in colorectal cancer, particularly in stage II disease.^{55,58-61} One large multicentre study reported adverse prognostic significance of both intramural and extramural perineural invasion.⁵⁸ However the importance of anatomic location in perineural invasion is not well established.

[↑ Back](#)

Note 17 – Lymph node status (Core)

The regional lymph node status is a major determinant of whether or not a patient receives adjuvant chemotherapy. Non-regional lymph node involvement by tumour, within large resection specimens, should be recorded separately, as this indicates distant metastatic (pM1) disease. In the case of two synchronous primary tumours in distinct anatomic regions, lymph nodes need to be assigned by regional status and assessed for each cancer separately.

The number of nodes present depends on the length of the resection specimen, the amount of attached mesenteric tissue, the age of the patient and whether or not the patient has received neoadjuvant therapy.⁶² Diligent pathology dissection is crucial as many positive lymph nodes are less than 5 mm in size. Some cases contain only a small number of nodes, but dissectors and departments should aim for a median lymph node yield of at least twelve per case. In stage II disease, low lymph node harvest is an adverse prognostic factor.⁶³

With respect to small nodal tumour deposits, a systematic review and meta-analysis found higher risk of disease recurrence in stage I/II colorectal cancer cases in the presence of only micrometastatic disease in lymph nodes (one or more deposit ≥ 0.2 mm and < 2 mm) compared to those with tumour-negative nodes, but no increased risk of disease recurrence in cases in the presence of only 'isolated tumour cells' in lymph nodes (single tumour cells or groups < 0.2 mm in maximum dimension) compared to those with tumour-negative nodes.⁶⁴ Therefore, cases in which isolated tumour cells, identified on H&E or immunohistochemical staining, represent the only form of nodal involvement should be classified as pN0, with a comment on the presence of the isolated tumour cells and optional designation as pN0(i+). Any lymph node containing tumour measuring ≥ 0.2 mm in diameter is counted as a positive node.

If neoadjuvant therapy has been received, designation as nodal involvement (ypN1/2) is based only on the presence of viable tumour. Assessment of lymph nodes in this setting should include a descriptive comment on the presence or absence of signs of regression (fibrosis, necrosis or mucin) within nodal tissue, to allow correlation with initial staging MRI.

[↑ Back](#)

Note 18 – Tumour deposits (Core)

Under the UICC/AJCC TNM 8th editions definition, tumour deposits (satellites) are discrete macroscopic or microscopic nodules of cancer in the pericolorectal adipose tissue's lymph drainage area of a primary carcinoma that are discontinuous from the primary and without histological evidence of residual lymph node or identifiable vascular or neural structures.^{5,6} The definition does not specify any minimum size of deposit or minimum distance of separation from the primary tumour. If a vessel wall is identifiable on H&E, elastic or other stains, it should be classified as venous invasion or lymphatic invasion. Similarly, if neural structures are identifiable, the lesion should be classified as perineural invasion. Identification of venous, lymphatic or perineural invasion does not change the T category. The presence of tumour deposits, as defined, also does not change the primary tumour T category, but changes the node status (N) to pN1c if all regional lymph nodes are negative on pathological examination. Therefore, pN1c is only applied in the setting of node-negative disease and, if any nodes contain metastatic tumour, the number of tumour deposits is not added to the involved node count in determining final pN category. However, as there is evidence from meta-analysis of the adverse prognostic significance of tumour deposits, albeit based on a previous definition, the presence and number of identified tumour deposits should be recorded regardless of pN status.⁶⁵

A mesenteric focus of tumour, without evidence of origin, which is discontinuous from the primary tumour, located within its lymphatic drainage area and predominantly subserosal in location but which penetrates the serosal surface of the mesentery, should be classified as a tumour deposit rather than distant metastatic (pM1c) disease. This finding does not influence the pT category, which should be based on extent of invasion of the primary tumour only, but a comment may be added that, given serosal involvement by the tumour deposit, behaviour may equate to pT4a disease. Guidance on this interpretation is offered without good evidence. pM1c disease should be reserved for tumour which appears to have arisen from metastatic spread via the peritoneal cavity.

Assessment of discontinuous tumour foci is difficult following administration of neoadjuvant therapy and evident tumour regression. This setting requires consideration of tissue separating the primary tumour site from the discontinuous tumour foci. Designation of such foci as tumour deposits should require the presence of intervening normal tissue, not just fibrosis.

↑ Back

Note 19 – Tumour budding (Non-core)

Tumour budding is defined as single cells or clusters of up to four tumour cells at the invasive front of carcinomas. It is considered to be the morphological manifestation of epithelial mesenchymal transition.⁶⁶ Tumour budding is different from tumour grade (based on gland formation) and poorly differentiated clusters (≥5 cells).

There is increasing evidence that tumour budding is an independent adverse prognostic factor in colorectal carcinoma. Several studies have shown that stage pT1 colorectal carcinomas with tumour budding score Bd2 and Bd3 (≥5 buds) are associated with an increased risk of lymph node metastasis.⁶⁷⁻⁷¹ For stage II colorectal carcinomas, tumour budding score Bd3 is associated with increased risk of recurrence and mortality.⁷²⁻⁷⁴

Tumour budding is reported as the number of buds and scored using a three-tier system. According to the recommendations from a consensus conference on tumour budding,⁷⁵ the number of tumour buds is the highest count after scanning ten separate fields (at 20x objective lens) along the invasive front of the tumour or the entire lesion for malignant polyps ('hotspot' approach). The number of tumour buds

is counted on H&E. If the invasive front of the tumour is obscured by inflammatory cells, immunohistochemistry using pan-cytokeratin can be used to help identifying the buds, but the final count is performed on H&E. Depending on the eyepiece field diameter of the microscope, the number of buds may need to be normalised to represent the number for a field of 0.785 mm² (objective lens 20x with eyepiece diameter of 20 mm).

Tumour budding should only be reported in non-mucinous and non-signet-ring cell adenocarcinoma areas. Furthermore, for colonic or rectal adenocarcinomas resected after neoadjuvant therapy, tumour budding should not be reported.

↑ Back

Note 20 – Response to neoadjuvant therapy (Core)

Patients with completely excised rectal carcinomas, who have received preoperative chemo-radiotherapy that has resulted in complete or marked regression of tumour and replacement by fibrosis, necrosis or acellular mucin, have a better prognosis than those without significant regression.⁷⁶⁻⁸⁰ A four-tier system of grading regression is recommended, based on a modification of that described by Ryan et al (2005).⁸¹ This should be applied when any form of neoadjuvant therapy is administered to rectal or colonic tumours. Tumour regression assessment is based on evaluation of the primary tumour site, but a descriptive comment should be added if any such features are evident in regional lymph nodes, or at any distant metastatic sites. Designation as complete pathological response implies the absence of viable tumour locally (ypT0) and in lymph nodes (ypN0) and requires processing of the entire tumour bed for histological examination.

↑ Back

Note 21 – Margin status (Core)

Assessments of longitudinal and circumferential resection margins may require macroscopic or microscopic measurement, depending on proximity of tumour to margins. Separately submitted anastomotic rings (“doughnuts”) should be taken into consideration for longitudinal margin assessment. Unless a tumour has particularly aggressive morphological features, for example signet-ring cell carcinoma, it is generally only necessary to histologically examine longitudinal margins if the tumour extends macroscopically to within 30 mm.⁸² For tumours further than this, it can be assumed that the longitudinal margins are not involved.

The circumferential (radial or non-peritonealised) margin represents the adventitial soft tissue margin closest to the deepest penetration of tumour and is created surgically by blunt or sharp dissection of the retroperitoneal or subperitoneal aspect, depending on the nature of the surgical resection. This margin must be assessed for any tumour either unencased or incompletely encased by peritoneum. Rectal tumours below the peritoneal reflection will be completely encased by a circumferential, non-peritonealised margin, while upper rectal tumours, and often proximal colonic tumours, have a non-peritonealised margin posteriorly and a peritonealised surface anteriorly (Figure 2). Transverse and sigmoid colonic tumours generally only have a narrow, readily identifiable, non-peritonealised margin, representing the level of surgical dissection of the mesentery. The term circumferential margin is favoured, even though the non-peritonealised margin is not always circumferential.

Circumferential margin involvement, typically defined as tumour ≤ 1 mm from the margin, is predictive of local recurrence and poor survival in rectal tumours,⁸³⁻⁸⁷ The importance of circumferential margin involvement in proximal colonic tumours has been recognised but less evidence is available.^{88,89} Any circumferential margin ≤ 1 mm from tumour should be recorded as involved, but the precise distance recorded, to the nearest 0.1 mm. If the tumour is clear by <10 mm, the specific distance of clearance should also be recorded, to the nearest 1 mm.

There is limited outcome data with respect to mode of circumferential margin involvement by tumour, but this limited data suggest that cases with margin involvement by discontinuous or intravascular (blood vessel or lymphatic vessel) tumour behave similarly to those with margin involvement by direct tumour spread with respect to local recurrence.^{83,84} However, margin involvement by tumour confined to a lymph node was not associated with a significant risk of local recurrence in one study.⁸⁴ Therefore, assuming the involved lymph node has an intact capsule and has not been transected at surgery, identification of an involved node at the circumferential margin should not be interpreted as margin involvement. An explanatory comment should be added to the pathology report to this effect. If a margin is designated as involved by tumour other than the primary mass, this should be clearly described and a separate measurement provided with respect to clearance from the margin of the primary tumour.

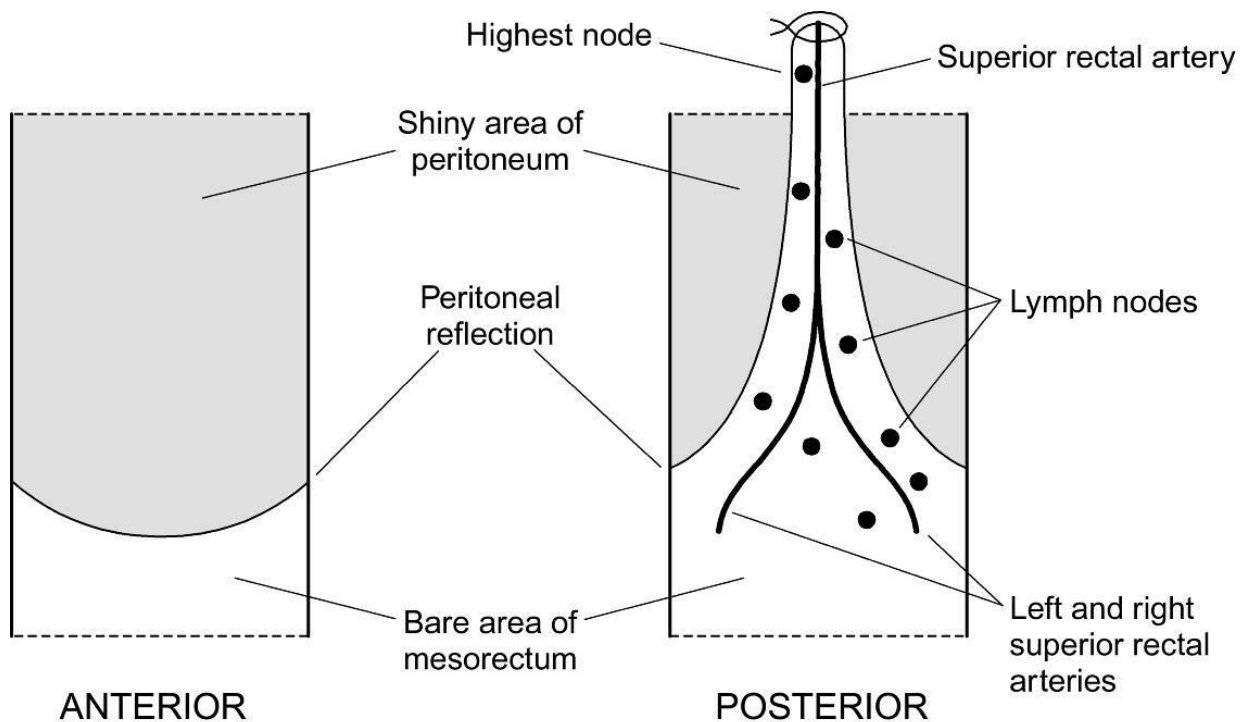


Figure 2: Diagrammatic representation of a resected rectum. Reproduced with permission from Loughrey MB, Quirke P and Shepherd NA (2018). *Dataset for histopathological reporting of colorectal cancer, 4th Edition*. The Royal College of Pathologists, United Kingdom.⁹⁰

↑ Back

Note 22 – Coexistent pathology (Non-core)

The presence of any pathological abnormalities in the background colon or rectum should be recorded. These include polyps (type, number and whether meeting criteria for any polyposis syndrome), chronic inflammatory bowel disease (distribution and specify with or without dysplasia), effects of any neoadjuvant therapy on non-neoplastic tissue, diverticular disease and/or changes related to obstruction. Synchronous primary carcinomas should have individual datasets completed for all appropriate elements.

↑ Back

Note 23 – Ancillary studies (Core and Non-core)

If a pure or mixed neuroendocrine neoplasm is suspected on morphology, immunohistochemistry is required to confirm neuroendocrine differentiation, usually applying synaptophysin and chromogranin A as a minimum. As with other gastrointestinal tract and pancreatic neuroendocrine neoplasms, assessment of proliferation index by Ki-67 immunohistochemistry is fundamental to grading of the neuroendocrine component.² A Ki-67 proliferation index <55% is associated with better overall survival in NECs.²⁵

Testing colorectal carcinoma for mismatch repair (MMR) protein deficiency is used for Lynch syndrome screening and provides therapeutic decision information for patient management. MMR deficiency is associated with good prognosis, poor response to 5-fluorouracil-based chemotherapy and predicts response to immune checkpoint blockade therapy.^{91,92}

BRAF mutation testing and *MLH1* promoter methylation analysis are performed to help distinguish sporadic *MLH1*-deficient colorectal carcinomas from Lynch syndrome associated tumours caused by constitutional *MLH1* mutation. The presence of either *BRAF* V600E mutation or *MLH1* promoter methylation effectively excludes Lynch syndrome. *BRAF* mutation status may also have predictive/therapeutic value.

↑ Back

Note 24 – Histologically confirmed distant metastasis (Core)

Tumour classifiable as distant metastatic disease may sometimes be present within the primary tumour resection specimen, for example a peritoneal or omental deposit that is discontinuous from the primary mass. Metastatic deposits in “non-regional” lymph nodes distant from those surrounding the main tumour will usually be submitted separately by the surgeon but may be present within an extended colectomy specimen.

Given different prognostication associated with the pattern of organ involvement by distant metastatic disease, UICC/AJCC 8th edition Staging Manuals have subclassified pM1 into pM1a indicating metastatic disease in one distant organ (excluding metastatic peritoneal disease), pM1b indicating metastatic disease in two or more distant organs and pM1c indicating metastatic peritoneal disease (regardless of other organ involvement).^{5,6} Note, pathologists can only base assessment of distant metastatic disease on submitted specimens and therefore should not use the terms ‘pM0’ or

'pMX'. cM1 and cM0 are used when clinical, usually radiological, evidence suggests the presence or absence respectively of distant metastatic disease.

↑ Back

Note 25 – Pathological staging (Core)

TNM staging should be assessed according to the agreed criteria of the UICC and AJCC 8th editions.^{5,6} The only exception is that pT in situ is not recognised for colorectal cancer in this dataset. Rare cases of colorectal neoplasia confined to invasion of the lamina propria (intramucosal invasive neoplasia or intramucosal carcinoma) are acknowledged but, given the negligible metastatic potential of such neoplasms,³⁴ these should be classified under the same category with high grade dysplasia/high grade non-invasive neoplasia.

Note that in the setting of completion surgery following a diagnosis of carcinoma in a local excision specimen, an overall tumour stage should be provided based on the pathological findings within both specimens, usually taking into consideration extent of local invasion in the local excision specimen and any residual local or nodal metastatic tumour in the subsequent surgical resection specimen. Regarding synchronous primary carcinomas, whilst individual datasets should be completed for each tumour, a single overarching stage should also be provided, following the conventions of TNM and applying the 'm' suffix.

↑ Back

References

- 1 Merlin T, Weston A and Tooher R (2009). Extending an evidence hierarchy to include topics other than treatment: revising the Australian 'levels of evidence'. *BMC Med Res Methodol* 9:34.
- 2 Nagtegaal ID, Arends MJ, Odze RD and Lam AK (2019). Tumours of the colon and rectum. In: *Digestive System Tumours. WHO Classification of Tumours, 5th Edition*, Lokuhetty D, White V, Watanabe R and Cree IA (eds), IARC Press, Lyon, France.
- 3 Petersen VC, Baxter KJ, Love SB and Shepherd NA (2002). Identification of objective pathological prognostic determinants and models of prognosis in Dukes' B colon cancer. *Gut* 51(1):65-69.
- 4 Nagtegaal ID, van de Velde CJ, Marijnen CA, van Krieken JH and Quirke P (2005). Low rectal cancer: a call for a change of approach in abdominoperineal resection. *J Clin Oncol* 23(36):9257-9264.
- 5 Brierley JD, Gospodarowicz MK and Wittekind C (eds) (2016). *UICC TNM Classification of Malignant Tumours, 8th Edition*, Wiley-Blackwell.
- 6 Amin MB, Edge SB, Greene FL, Byrd DR, Brookland RK, Washington MK, Gershenwald JE, Compton CC, Hess KR, Sullivan DC, Jessup JM, Brierley JD, Gaspar LE, Schilsky RL, Balch CM, Winchester DP, Asare EA, Madera M, Gress DM and Meyer LR (eds) (2017). *AJCC Cancer Staging Manual. 8th ed.*, Springer, New York.

- 7 Quirke P, Steele R, Monson J, Grieve R, Khanna S, Couture J, O'Callaghan C, Myint AS, Bessell E, Thompson LC, Parmar M, Stephens RJ and Sebag-Montefiore D (2009). Effect of the plane of surgery achieved on local recurrence in patients with operable rectal cancer: a prospective study using data from the MRC CR07 and NCIC-CTG CO16 randomised clinical trial. *Lancet* 373(9666):821-828.
- 8 Royal College of Pathologists of Australasia (2016). *Colorectal cancer structured reporting protocol*. Available from: <https://www.rcpa.edu.au/getattachment/730b9fad-3228-4601-9009-b3d671818bd6/Protocol-colorectal-cancer.aspx> (Accessed 22nd April 2020).
- 9 Arbman G, Nilsson E, Hallbook O and Sjudahl R (1996). Local recurrence following total mesorectal excision for rectal cancer. *Br J Surg* 83(3):375-379.
- 10 Kapiteijn E, Marijnen CA, Nagtegaal ID, Putter H, Steup WH, Wiggers T, Rutten HJ, Pahlman L, Glimelius B, van Krieken JH, Leer JW and van de Velde CJ (2001). Preoperative radiotherapy combined with total mesorectal excision for resectable rectal cancer. *N Engl J Med* 345(9):638-646.
- 11 Nagtegaal ID, van de Velde CJ, van der Worp E, Kapiteijn E, Quirke P and van Krieken JH (2002). Macroscopic evaluation of rectal cancer resection specimen: clinical significance of the pathologist in quality control. *J Clin Oncol* 20(7):1729-1734.
- 12 den Dulk M, Putter H, Collette L, Marijnen CAM, Folkesson J, Bosset JF, Rodel C, Bujko K, Pahlman L and van de Velde CJH (2009). The abdominoperineal resection itself is associated with an adverse outcome: the European experience based on a pooled analysis of five European randomised clinical trials on rectal cancer. *Eur J Cancer* 45(7):1175-1183.
- 13 Stelzner S, Koehler C, Stelzer J, Sims A and Witzigmann H (2011). Extended abdominoperineal excision vs. standard abdominoperineal excision in rectal cancer--a systematic overview. *Int J Colorectal Dis* 26(10):1227-1240.
- 14 West NP, Anderin C, Smith KJ, Holm T and Quirke P (2010). Multicentre experience with extralevator abdominoperineal excision for low rectal cancer. *Br J Surg* 97(4):588-599.
- 15 Battersby NJ, How P, Moran B, Stelzner S, West NP, Branagan G, Strassburg J, Quirke P, Tekkis P, Pedersen BG, Gudgeon M, Heald B and Brown G (2016). Prospective validation of a low rectal cancer magnetic resonance imaging staging system and development of a local recurrence risk stratification model: the MERCURY II study. *Ann Surg* 263(4):751-760.
- 16 Quirke P, Thorpe H, Dewberry S, Brown J, Jayne D, Guillou P, MRC CLASICC Trialists (2008). *Prospective assessment of the quality of surgery in the MRC CLASICC trial evidence for variation in the plane of surgery in colon cancer, local recurrence and survival*. Available from: <http://abstracts.ncri.org.uk/abstract/prospective-assessment-of-the-quality-of-surgery-in-the-mrc-clasicc-trial-evidence-for-variation-in-the-plane-of-surgery-in-colon-cancer-local-recurrence-and-survival-4/> (Accessed 22nd April 2020).
- 17 West NP, Morris EJ, Rotimi O, Cairns A, Finan PJ and Quirke P (2008). Pathology grading of colon cancer surgical resection and its association with survival: a retrospective observational study. *Lancet Oncol* 9(9):857-865.
- 18 Gouvas N, Agalianos C, Papaparaskeva K, Perrakis A, Hohenberger W and Xynos E (2016). Surgery along the embryological planes for colon cancer: a systematic review of complete mesocolic excision. *Int J Colorectal Dis* 31(9):1577-1594.

- 19 Kang H, O'Connell JB, Maggard MA, Sack J and Ko CY (2005). A 10-year outcomes evaluation of mucinous and signet-ring cell carcinoma of the colon and rectum. *Dis Colon Rectum* 48(6):1161-1168.
- 20 Kakar S, Deng G, Smyrk TC, Cun L, Sahai V and Kim YS (2012). Loss of heterozygosity, aberrant methylation, BRAF mutation and KRAS mutation in colorectal signet ring cell carcinoma. *Mod Pathol* 25(7):1040-1047.
- 21 Pyo JS, Sohn JH and Kang G (2016). Medullary carcinoma in the colorectum: a systematic review and meta-analysis. *Hum Pathol* 53:91-96.
- 22 Garcia-Solano J, Perez-Guillermo M, Conesa-Zamora P, Acosta-Ortega J, Trujillo-Santos J, Cerezuela-Fuentes P and Makinen MJ (2010). Clinicopathologic study of 85 colorectal serrated adenocarcinomas: further insights into the full recognition of a new subset of colorectal carcinoma. *Hum Pathol* 41(10):1359-1368.
- 23 Haupt B, Ro JY, Schwartz MR and Shen SS (2007). Colorectal adenocarcinoma with micropapillary pattern and its association with lymph node metastasis. *Mod Pathol* 20(7):729-733.
- 24 Gonzalez RS, Cates JM, Washington MK, Beauchamp RD, Coffey RJ and Shi C (2016). Adenoma-like adenocarcinoma: a subtype of colorectal carcinoma with good prognosis, deceptive appearance on biopsy and frequent KRAS mutation. *Histopathology* 68(2):183-190.
- 25 Milione M, Maisonneuve P, Spada F, Pellegrinelli A, Spaggiari P, Albarello L, Pisa E, Barberis M, Vanoli A, Buzzoni R, Pusceddu S, Concas L, Sessa F, Solcia E, Capella C, Fazio N and La Rosa S (2017). The Clinicopathologic Heterogeneity of Grade 3 Gastroenteropancreatic Neuroendocrine Neoplasms: Morphological Differentiation and Proliferation Identify Different Prognostic Categories. *Neuroendocrinology* 104(1):85-93.
- 26 Chandler I and Houlston RS (2008). Interobserver agreement in grading of colorectal cancers-findings from a nationwide web-based survey of histopathologists. *Histopathology* 52(4):494-499.
- 27 Chapuis PH, Dent OF, Fisher R, Newland RC, Pheils MT, Smyth E and Colquhoun K (1985). A multivariate analysis of clinical and pathological variables in prognosis after resection of large bowel cancer. *Br J Surg* 72(9):698-702.
- 28 Renfro LA, Grothey A, Xue Y, Saltz LB, Andre T, Twelves C, Labianca R, Allegra CJ, Alberts SR, Loprinzi CL, Yothers G and Sargent DJ (2014). ACCENT-based web calculators to predict recurrence and overall survival in stage III colon cancer. *J Natl Cancer Inst* 106(12):1-9.
- 29 Weiser MR, Gonen M, Chou JF, Kattan MW and Schrag D (2011). Predicting survival after curative colectomy for cancer: individualizing colon cancer staging. *J Clin Oncol* 29(36):4796-4802.
- 30 Konishi T, Shimada Y, Lee LH, Cavalcanti MS, Hsu M, Smith JJ, Nash GM, Temple LK, Guillem JG, Paty PB, Garcia-Aguilar J, Vakiani E, Gonen M, Shia J and Weiser MR (2018). Poorly differentiated clusters predict colon cancer recurrence: an in-depth comparative analysis of invasive-front prognostic markers. *Am J Surg Pathol* 42(6):705-714.
- 31 Ueno H, Kajiwara Y, Shimazaki H, Shinto E, Hashiguchi Y, Nakanishi K, Maekawa K, Katsurada Y, Nakamura T, Mochizuki H, Yamamoto J and Hase K (2012). New criteria for histologic grading of colorectal cancer. *Am J Surg Pathol* 36(2):193-201.

- 32 Kakar S, Aksoy S, Burgart LJ and Smyrk TC (2004). Mucinous carcinoma of the colon: correlation of loss of mismatch repair enzymes with clinicopathologic features and survival. *Mod Pathol* 17(6):696-700.
- 33 Yoshioka Y, Togashi Y, Chikugo T, Kogita A, Taguri M, Terashima M, Mizukami T, Hayashi H, Sakai K, de Velasco MA, Tomida S, Fujita Y, Tokoro T, Ito A, Okuno K and Nishio K (2015). Clinicopathological and genetic differences between low-grade and high-grade colorectal mucinous adenocarcinomas. *Cancer* 121(24):4359-4368.
- 34 Kojima M, Shimazaki H, Iwaya K, Nakamura T, Kawachi H, Ichikawa K, Sekine S, Ishiguro S, Shimoda T, Kushima R, Yao T, Fujimori T, Hase K, Watanabe T, Sugihara K, Lauwers GY and Ochiai A (2017). Intramucosal colorectal carcinoma with invasion of the lamina propria: a study by the Japanese Society for Cancer of the Colon and Rectum. *Hum Pathol* 66:230-237.
- 35 Jass JR, O'Brien MJ, Riddell RH and Snover DC (2007). Recommendations for the reporting of surgically resected specimens of colorectal carcinoma. *Hum Pathol* 38(4):537-545.
- 36 Puppa G, Maisonneuve P, Sonzogni A, Masullo M, Capelli P, Chilosi M, Menestrina F, Viale G and Pelosi G (2007). Pathological assessment of pericolonic tumor deposits in advanced colonic carcinoma: relevance to prognosis and tumor staging. *Mod Pathol* 20(8):843-855.
- 37 Shepherd NA, Baxter KJ and Love SB (1997). The prognostic importance of peritoneal involvement in colonic cancer: a prospective evaluation. *Gastroenterology* 112(4):1096-1102.
- 38 Gunderson LL, Jessup JM, Sargent DJ, Greene FL and Stewart AK (2010). Revised TN categorization for colon cancer based on national survival outcomes data. *J Clin Oncol* 28(2):264-271.
- 39 Kirsch R, Messenger DE, Shepherd NA, Dawson H and Driman DK (2018). Wide variability in assessment and reporting of colorectal cancer specimens among North American pathologists: results of a Canada-US Survey. *Can J of Pathol* 11(1):58-69.
- 40 Liang WY, Chang WC, Hsu CY, Arnason T, Berger D, Hawkins AT, Sylla P and Lauwers GY (2013). Retrospective evaluation of elastic stain in the assessment of serosal invasion of pT3N0 colorectal cancers. *Am J Surg Pathol* 37(10):1565-1570.
- 41 Kojima M, Nakajima K, Ishii G, Saito N and Ochiai A (2010). Peritoneal elastic laminal invasion of colorectal cancer: the diagnostic utility and clinicopathologic relationship. *Am J Surg Pathol* 34(9):1351-1360.
- 42 Grin A, Messenger DE, Cook M, O'Connor BI, Hafezi S, El-Zimaity H and Kirsch R (2013). Peritoneal elastic lamina invasion: limitations in its use as a prognostic marker in stage II colorectal cancer. *Hum Pathol* 44(12):2696-2705.
- 43 Puppa G, Shepherd NA, Sheahan K and Stewart CJR (2011). Peritoneal elastic lamina invasion in colorectal cancer: the answer to a controversial area of pathology? *Am J Surg Pathol* 35(3):465-468.
- 44 Bori R, Sejben I, Svebis M, Vajda K, Marko L, Pajkos G and Cserni G (2009). Heterogeneity of pT3 colorectal carcinomas according to the depth of invasion. *Pathol Oncol Res* 15(3):527-532.
- 45 Merkel S, Mansmann U, Siassi M, Papadopoulos T, Hohenberger W and Hermanek P (2001). The prognostic inhomogeneity in pT3 rectal carcinomas. *Int J Colorectal Dis* 16(5):298-304.

- 46 Freedman LS, Macaskill P and Smith AN (1984). Multivariate analysis of prognostic factors for operable rectal cancer. *Lancet* 2(8405):733-736.
- 47 Betge J, Pollheimer MJ, Lindtner RA, Kornprat P, Schlemmer A, Rehak P, Vieth M, Hoefler G and Langner C (2012). Intramural and extramural vascular invasion in colorectal cancer: prognostic significance and quality of pathology reporting. *Cancer* 118(3):628-638.
- 48 Roxburgh CS, McMillan DC, Anderson JH, McKee RF, Horgan PG and Foulis AK (2010). Elastica staining for venous invasion results in superior prediction of cancer-specific survival in colorectal cancer. *Ann Surg* 252(6):989-997.
- 49 Talbot IC, Ritchie S, Leighton M, Hughes AO, Bussey HJ and Morson BC (1981). Invasion of veins by carcinoma of rectum: method of detection, histological features and significance. *Histopathology* 5(2):141-163.
- 50 Howlett CJ, Tweedie EJ and Driman DK (2009). Use of an elastic stain to show venous invasion in colorectal carcinoma: a simple technique for detection of an important prognostic factor. *J Clin Pathol* 62(11):1021-1025.
- 51 Kirsch R, Messenger DE, Riddell RH, Pollett A, Cook M, Al-Haddad S, Streutker CJ, Divaris DX, Pandit R, Newell KJ, Liu J, Price RG, Smith S, Parfitt JR and Driman DK (2013). Venous invasion in colorectal cancer: impact of an elastin stain on detection and interobserver agreement among gastrointestinal and nongastrointestinal pathologists. *Am J Surg Pathol* 37(2):200-210.
- 52 Roxburgh CS and Foulis AK (2011). The prognostic benefits of routine staining with elastica to increase detection of venous invasion in colorectal cancer specimens. *J Clin Pathol* 64(12):1142.
- 53 Messenger DE, Driman DK and Kirsch R (2012). Developments in the assessment of venous invasion in colorectal cancer: implications for future practice and patient outcome. *Hum Pathol* 43(7):965-973.
- 54 Kojima M, Shimazaki H, Iwaya K, Kage M, Akiba J, Ohkura Y, Horiguchi S, Shomori K, Kushima R, Ajioka Y, Nomura S and Ochiai A (2013). Pathological diagnostic criterion of blood and lymphatic vessel invasion in colorectal cancer: a framework for developing an objective pathological diagnostic system using the Delphi method, from the Pathology Working Group of the Japanese Society for Cancer of the Colon and Rectum. *J Clin Pathol* 66(7):551-558.
- 55 Santos C, Lopez-Doriga A, Navarro M, Mateo J, Biondo S, Martinez Villacampa M, Soler G, Sanjuan X, Paules MJ, Laquente B, Guino E, Kreisler E, Frago R, Germa JR, Moreno V and Salazar R (2013). Clinicopathological risk factors of Stage II colon cancer: results of a prospective study. *Colorectal Dis* 15(4):414-422.
- 56 Lim SB, Yu CS, Jang SJ, Kim TW, Kim JH and Kim JC (2010). Prognostic significance of lymphovascular invasion in sporadic colorectal cancer. *Dis Colon Rectum* 53(4):377-384.
- 57 van Wyk HC, Roxburgh CS, Horgan PG, Foulis AF and McMillan DC (2014). The detection and role of lymphatic and blood vessel invasion in predicting survival in patients with node negative operable primary colorectal cancer. *Crit Rev Oncol Hematol* 90(1):77-90.
- 58 Ueno H, Shirouzu K, Eishi Y, Yamada K, Kusumi T, Kushima R, Ikegami M, Murata A, Okuno K, Sato T, Ajioka Y, Ochiai A, Shimazaki H, Nakamura T, Kawachi H, Kojima M, Akagi Y and Sugihara K (2013). Characterization of perineural invasion as a component of colorectal cancer staging. *Am J Surg Pathol* 37(10):1542-1549.

- 59 Liebig C, Ayala G, Wilks J, Verstovsek G, Liu H, Agarwal N, Berger DH and Albo D (2009). Perineural invasion is an independent predictor of outcome in colorectal cancer. *J Clin Oncol* 27(31):5131-5137.
- 60 Knijn N, Mogk SC, Teerenstra S, Simmer F and Nagtegaal ID (2016). Perineural invasion is a strong prognostic factor in colorectal cancer: a systematic review. *Am J Surg Pathol* 40(1):103-112.
- 61 Huh JW, Kim HR and Kim YJ (2010). Prognostic value of perineural invasion in patients with stage II colorectal cancer. *Ann Surg Oncol* 17(8):2066-2072.
- 62 Wijesuriya RE, Deen KI, Hewavisenthi J, Balawardana J and Perera M (2005). Neoadjuvant therapy for rectal cancer down-stages the tumor but reduces lymph node harvest significantly. *Surg Today* 35(6):442-445.
- 63 Chang GJ, Rodriguez-Bigas MA, Skibber JM and Moyer VA (2007). Lymph node evaluation and survival after curative resection of colon cancer: systematic review. *J Natl Cancer Inst* 99(6):433-441.
- 64 Sloothaak DA, Sahami S, van der Zaag-Loonen HJ, van der Zaag ES, Tanis PJ, Bemelman WA and Buskens CJ (2014). The prognostic value of micrometastases and isolated tumour cells in histologically negative lymph nodes of patients with colorectal cancer: a systematic review and meta-analysis. *Eur J Surg Oncol* 40(3):263-269.
- 65 Nagtegaal ID, Knijn N, Hugen N, Marshall HC, Sugihara K, Tot T, Ueno H and Quirke P (2017). Tumor deposits in colorectal cancer: improving the value of modern staging-a systematic review and meta-analysis. *J Clin Oncol* 35(10):1119-1127.
- 66 Zlobec I and Lugli A (2010). Epithelial mesenchymal transition and tumor budding in aggressive colorectal cancer: tumor budding as oncotarget. *Oncotarget* 1(7):651-661.
- 67 Pai RK, Cheng YW, Jakubowski MA, Shadrach BL, Plesec TP and Pai RK (2017). Colorectal carcinomas with submucosal invasion (pT1): analysis of histopathological and molecular factors predicting lymph node metastasis. *Mod Pathol* 30(1):113-122.
- 68 Beaton C, Twine CP, Williams GL and Radcliffe AG (2013). Systematic review and meta-analysis of histopathological factors influencing the risk of lymph node metastasis in early colorectal cancer. *Colorectal Dis* 15(7):788-797.
- 69 Ueno H, Hase K, Hashiguchi Y, Shimazaki H, Yoshii S, Kudo SE, Tanaka M, Akagi Y, Suto T, Nagata S, Matsuda K, Komori K, Yoshimatsu K, Tomita Y, Yokoyama S, Shinto E, Nakamura T and Sugihara K (2014). Novel risk factors for lymph node metastasis in early invasive colorectal cancer: a multi-institution pathology review. *J Gastroenterol* 49(9):1314-1323.
- 70 Suh JH, Han KS, Kim BC, Hong CW, Sohn DK, Chang HJ, Kim MJ, Park SC, Park JW, Choi HS and Oh JH (2012). Predictors for lymph node metastasis in T1 colorectal cancer. *Endoscopy* 44(6):590-595.
- 71 Tateishi Y, Nakanishi Y, Taniguchi H, Shimoda T and Umemura S (2010). Pathological prognostic factors predicting lymph node metastasis in submucosal invasive (T1) colorectal carcinoma. *Mod Pathol* 23(8):1068-1072.
- 72 van Wyk HC, Park J, Roxburgh C, Horgan P, Foulis A and McMillan DC (2015). The role of tumour budding in predicting survival in patients with primary operable colorectal cancer: a systematic review. *Cancer Treat Rev* 41(2):151-159.

- 73 Petrelli F, Pezzica E, Cabiddu M, Coinu A, Borgonovo K, Ghilardi M, Lonati V, Corti D and Barni S (2015). Tumour budding and survival in stage II colorectal cancer: a systematic review and pooled analysis. *J Gastrointest Cancer* 46(3):212-218.
- 74 Rogers AC, Winter DC, Heeney A, Gibbons D, Lugli A, Puppa G and Sheahan K (2016). Systematic review and meta-analysis of the impact of tumour budding in colorectal cancer. *Br J Cancer* 115(7):831-840.
- 75 Lugli A, Kirsch R, Ajioka Y, Bosman F, Cathomas G, Dawson H, El Zimaity H, Flejou JF, Hansen TP, Hartmann A, Kakar S, Langner C, Nagtegaal I, Puppa G, Riddell R, Ristimaki A, Sheahan K, Smyrk T, Sugihara K, Terris B, Ueno H, Vieth M, Zlobec I and Quirke P (2017). Recommendations for reporting tumor budding in colorectal cancer based on the International Tumor Budding Consensus Conference (ITBCC) 2016. *Mod Pathol* 30(9):1299-1311.
- 76 Maas M, Nelemans PJ, Valentini V, Das P, Rodel C, Kuo LJ, Calvo FA, Garcia-Aguilar J, Glynne-Jones R, Haustermans K, Mohiuddin M, Pucciarelli S, Small W, Jr., Suarez J, Theodoropoulos G, Biondo S, Beets-Tan RG and Beets GL (2010). Long-term outcome in patients with a pathological complete response after chemoradiation for rectal cancer: a pooled analysis of individual patient data. *Lancet Oncol* 11(9):835-844.
- 77 Rodel C, Martus P, Papadoupolos T, Fuzesi L, Klimpfnger M, Fietkau R, Liersch T, Hohenberger W, Raab R, Sauer R and Wittekind C (2005). Prognostic significance of tumor regression after preoperative chemoradiotherapy for rectal cancer. *J Clin Oncol* 23(34):8688-8696.
- 78 Hermanek P, Merkel S and Hohenberger W (2013). Prognosis of rectal carcinoma after multimodal treatment: ypTNM classification and tumor regression grading are essential. *Anticancer Res* 33(2):559-566.
- 79 Gavioli M, Luppi G, Losi L, Bertolini F, Santantonio M, Falchi AM, D'Amico R, Conte PF and Natalini G (2005). Incidence and clinical impact of sterilized disease and minimal residual disease after preoperative radiochemotherapy for rectal cancer. *Dis Colon Rectum* 48(10):1851-1857.
- 80 Ruo L, Tickoo S, Klimstra DS, Minsky BD, Saltz L, Mazumdar M, Paty PB, Wong WD, Larson SM, Cohen AM and Guillem JG (2002). Long-term prognostic significance of extent of rectal cancer response to preoperative radiation and chemotherapy. *Ann Surg* 236(1):75-81.
- 81 Ryan R, Gibbons D, Hyland JM, Treanor D, White A, Mulcahy HE, O'Donoghue DP, Moriarty M, Fennelly D and Sheahan K (2005). Pathological response following long-course neoadjuvant chemoradiotherapy for locally advanced rectal cancer. *Histopathology* 47(2):141-146.
- 82 Cross SS, Bull AD and Smith JH (1989). Is there any justification for the routine examination of bowel resection margins in colorectal adenocarcinoma? *J Clin Pathol* 42(10):1040-1042.
- 83 Nagtegaal ID and Quirke P (2008). What is the role for the circumferential margin in the modern treatment of rectal cancer? *J Clin Oncol* 26(2):303-312.
- 84 Birbeck KF, Macklin CP, Tiffin NJ, Parsons W, Dixon MF, Mapstone NP, Abbott CR, Scott N, Finan PJ, Johnston D and Quirke P (2002). Rates of circumferential resection margin involvement vary between surgeons and predict outcomes in rectal cancer surgery. *Ann Surg* 235(4):449-457.

- 85 Ng IO, Luk IS, Yuen ST, Lau PW, Pritchett CJ, Ng M, Poon GP and Ho J (1993). Surgical lateral clearance in resected rectal carcinomas. A multivariate analysis of clinicopathologic features. *Cancer* 71(6):1972-1976.
- 86 Adam IJ, Mohamdee MO, Martin IG, Scott N, Finan PJ, Johnston D, Dixon MF and Quirke P (1994). Role of circumferential margin involvement in the local recurrence of rectal cancer. *Lancet* 344(8924):707-711.
- 87 Quirke P, Durdey P, Dixon MF and Williams NS (1986). Local recurrence of rectal adenocarcinoma due to inadequate surgical resection. Histopathological study of lateral tumour spread and surgical excision. *Lancet* 2(8514):996-999.
- 88 Scott N, Jamali A, Verbeke C, Ambrose NS, Botterill ID and Jayne DG (2008). Retroperitoneal margin involvement by adenocarcinoma of the caecum and ascending colon: what does it mean? *Colorectal Dis* 10(3):289-293.
- 89 Bateman AC, Carr NJ and Warren BF (2005). The retroperitoneal surface in distal caecal and proximal ascending colon carcinoma: the Cinderella surgical margin? *J Clin Pathol* 58(4):426-428.
- 90 The Royal College of Pathologists (2018). *Dataset for histopathological reporting of colorectal cancer*. Available from: <https://www.rcpath.org/uploads/assets/c8b61ba0-ae3f-43f1-85ffd3ab9f17cfe6/G049-Dataset-for-histopathological-reporting-of-colorectal-cancer.pdf> (Accessed 22nd April 2020).
- 91 Le DT, Durham JN, Smith KN, Wang H, Bartlett BR, Aulakh LK, Lu S, Kemberling H, Wilt C, Luber BS, Wong F, Azad NS, Rucki AA, Laheru D, Donehower R, Zaheer A, Fisher GA, Crocenzi TS, Lee JJ, Greten TF, Duffy AG, Ciombor KK, Eyring AD, Lam BH, Joe A, Kang SP, Holdhoff M, Danilova L, Cope L, Meyer C, Zhou S, Goldberg RM, Armstrong DK, Bever KM, Fader AN, Taube J, Housseau F, Spetzler D, Xiao N, Pardoll DM, Papadopoulos N, Kinzler KW, Eshleman JR, Vogelstein B, Anders RA and Diaz LA, Jr. (2017). Mismatch repair deficiency predicts response of solid tumors to PD-1 blockade. *Science* 357(6349):409-413.
- 92 Le DT, Uram JN, Wang H, Bartlett BR, Kemberling H, Eyring AD, Skora AD, Luber BS, Azad NS, Laheru D, Biedrzycki B, Donehower RC, Zaheer A, Fisher GA, Crocenzi TS, Lee JJ, Duffy SM, Goldberg RM, de la Chapelle A, Koshiji M, Bhajee F, Huebner T, Hruban RH, Wood LD, Cuka N, Pardoll DM, Papadopoulos N, Kinzler KW, Zhou S, Cornish TC, Taube JM, Anders RA, Eshleman JR, Vogelstein B and Diaz LA, Jr. (2015). PD-1 blockade in tumors with mismatch-repair deficiency. *N Engl J Med* 372(26):2509-2520.