

Carcinoma of the Thyroid Histopathology Reporting Guide



Family/Last name

Date of birth

Given name(s)

Patient identifiers

Date of request

Accession/Laboratory number

Elements in **black text** are CORE. Elements in **grey text** are NON-CORE.

indicates multi-select values indicates single select values

SCOPE OF THIS DATASET

CLINICAL INFORMATION (select all that apply) (Note 1)

- Information not provided
- Previous history of thyroid tumour or related abnormality, *specify*
- Relevant biopsy/cytology results, *specify*
- Imaging findings, *specify*
- Previous surgery/therapy, *specify*
- Relevant familial history, *specify*
- Presence of clinical syndrome, *specify*
- Other, *specify*

OPERATIVE PROCEDURE (select all that apply) (Note 2)

- Not specified
- Total thyroidectomy
- Near total thyroidectomy
- Hemithyroidectomy
- Lobectomy
- Isthmusectomy
- Partial excision,^a *specify type if possible*
- Lymph node dissection
- Other, *specify*

^a Anything less than a lobectomy excluding isthmusectomy, including substernal excision.

OPERATIVE FINDINGS (Note 3)

- Not specified
- Intra-operative macroscopic evidence of extrathyroidal extension**
 - Yes, *specify location and tissue invaded*
 - No
 - Information not available
- Intra-operative impression of completeness of excision**
 - R0/R1
 - R2, *specify location*
 - Information not available
- Other, *specify***

SPECIMEN(S) SUBMITTED (select all that apply) (Note 4)

- Not specified
- Thyroid gland
 - Left Right Isthmus
- Parathyroid gland(s)
- Lymph node(s), specify site(s) and laterality
- Other, specify site(s) and laterality

TUMOUR FOCALITY (Note 5)

(For the most clinically relevant tumour)

- Unifocal
- Multifocal, specify number of tumours in specimen (if >5 state such but no need to specify the number)
- Cannot be assessed, specify

TUMOUR SITE (select all that apply) (Note 6)

(For the most clinically relevant tumour)

- Not specified
- Lobe
 - Left Right
- Isthmus
- Pyramidal lobe
- Soft tissue or muscle, specify site(s) and laterality
- Other, specify site(s) and laterality

TUMOUR DIMENSIONS (Note 7)

Maximum tumour dimension (largest tumour)

mm

Additional dimensions (largest tumour)

mm x mm

- Cannot be assessed, specify

HISTOLOGICAL TUMOUR TYPE (select all that apply) (Note 8)

(Value list from the World Health Organization Classification of Tumours: Pathology and Genetics of Tumours of Endocrine Organs (2017))

- Papillary thyroid carcinoma
 - Classic (usual, conventional)
 - Columnar cell variant
 - Cribriform-morular variant
 - Diffuse sclerosing variant
 - Encapsulated variant
 - Encapsulated/well demarcated follicular variant with invasion
 - Infiltrative follicular variant
 - Hobnail variant
 - Microcarcinoma
 - Oncocytic variant
 - Solid variant
 - Tall cell variant
 - Warthin-like variant
 - Other variant, specify
- Follicular thyroid carcinoma (FTC)
 - FTC, minimally invasive
 - FTC, encapsulated angioinvasive
 - FTC, widely invasive
- Hürthle (oncocytic) cell tumours
 - Hürthle cell carcinoma, minimally invasive
 - Hürthle cell carcinoma, encapsulated angioinvasive
 - Hürthle cell carcinoma, widely invasive
- Poorly differentiated thyroid carcinoma
- Anaplastic thyroid carcinoma
- Squamous cell carcinoma
- Medullary thyroid carcinoma
- Mixed medullary and follicular thyroid carcinoma
- Mucoepidermoid carcinoma
- Sclerosing mucoepidermoid carcinoma with eosinophilia
- Mucinous carcinoma
- Spindle epithelial tumour with thymus-like differentiation
- Intrathyroid thymic carcinoma
- Other, specify

MITOTIC ACTIVITY^b (Note 9)

- Not identified/low (<3 mitoses/2 mm²)
- High (≥3 mitoses/2 mm²)

Number of mitoses per 2 mm²

- Cannot be assessed

^b 2 mm² approximates 10 HPFs on some microscopes.

HISTOLOGICAL TUMOUR GRADE (Note 10)

- Well-differentiated
- Poorly differentiated
- Undifferentiated/anaplastic

TUMOUR ENCAPSULATION/CIRCUMSCRIPTION (Note 11)

- Encapsulated
 Infiltrative
 Other, *specify*

CAPSULAR INVASION (Note 12)

- Not applicable
 Uncertain
 Not identified
 Present
 Cannot be assessed, *specify*

LYMPHOVASCULAR INVASION (Note 13)

- Not identified
 Present, for encapsulated neoplasms, *specify*
- Focal, <4 foci
 Extensive, ≥4 foci

Extrathyroid lymphovascular invasion

- Not identified
 Present
 Cannot be assessed, *specify*

NECROSIS (Note 14)

- Not identified
 Present

EXTRATHYROIDAL EXTENSION (select all that apply) (Note 15)

- Cannot be assessed
 Not identified
 Invasion into perithyroid fibroadipose tissue
 Invasion into skeletal muscle
 Invasion into subcutaneous soft tissue, larynx, trachea, oesophagus or recurrent laryngeal nerve
 Invasion into prevertebral fascia or encasing the carotid artery or mediastinal vessel

MARGIN STATUS (Note 16)

- Not involved
 Distance of tumour to closest margin mm
- Involved, *specify (anterior or posterior)*
- Cannot be assessed, *specify*

LYMPH NODE STATUS (Note 17)

- No nodes submitted or found
 Number of lymph nodes examined
- Not involved
 Involved
 Number of positive lymph nodes
- Number cannot be determined

Location of involved lymph nodes, *specify*

Greatest dimension of largest lymph node with metastasis mmGreatest dimension of largest metastatic focus in lymph node mm**Extranodal extension**

- Not identified
 Present
 Cannot be determined

C-CELL HYPERPLASIA (Note 18)*(Medullary carcinoma only)*

- Not identified
 Present
 Unilateral
 Bilateral

COEXISTENT PATHOLOGY (select all that apply) (Note 19)

- None identified
 Nodular hyperplasia
 Diffuse hyperplasia
 Dyshormonogenetic goitre
 Chronic lymphocytic thyroiditis
 Follicular adenoma
 Hürthle cell adenoma
 Noninvasive follicular thyroid neoplasm with papillary-like nuclear features (NIFTP)
 Other, *specify*

PARATHYROID GLAND STATUS (Note 20)

- Not identified
 Present
 Number of parathyroid gland(s) found
- Normal
 Involved by carcinoma
 Hypercellular/enlarged

ANCILLARY STUDIES (Note 21)

- Not performed
- Performed, *specify*

▼

| |
|--|
| |
| |

HISTOLOGICALLY CONFIRMED DISTANT METASTASES (Note 22)

- Not identified
- Not assessed
- Present, *specify site(s)*

▼

| |
|--|
| |
| |

PATHOLOGICAL STAGING (UICC TNM 8th edition)^c (Note 23)

TNM Descriptors (only if applicable) (select all that apply)

- m - multiple primary tumours
- r - recurrent
- y - post-therapy

Primary tumour (pT)^d

- TX Primary tumour cannot be assessed
- T1 Tumour 2 cm or less in greatest dimension, limited to the thyroid
 - T1a Tumour 1 cm or less in greatest dimension, limited to the thyroid
 - T1b Tumour more than 1 cm but not more than 2 cm in greatest dimension, limited to the thyroid
- T2 Tumour more than 2 cm but not more than 4 cm in greatest dimension, limited to the thyroid
- T3 Tumour more than 4 cm in greatest dimension, limited to the thyroid or with gross extrathyroidal extension invading only strap muscles (sternohyoid, sternothyroid, or omohyoid muscles)
 - T3a Tumour more than 4 cm in greatest dimension, limited to the thyroid
 - T3b Tumour of any size with gross extrathyroidal extension invading strap muscles (sternohyoid, sternothyroid, or omohyoid muscles)
- T4^e Includes gross extrathyroidal extension into major neck structures
 - T4a Tumour extends beyond the thyroid capsule and invades any of the following: subcutaneous soft tissues, larynx, trachea, oesophagus, recurrent laryngeal nerve
 - T4b Tumour invades prevertebral fascia, mediastinal vessels, or encases carotid artery

^d Including papillary, follicular, poorly differentiated, Hürthle cell and anaplastic carcinomas.

^e T4 has been added for clarity from AJCC TNM 8th edition.

Regional lymph nodes (pN)

- NX Regional lymph nodes cannot be assessed
- N0 No regional lymph node metastasis
- N1 Regional lymph node metastasis
 - N1a Metastasis in level VI (pretracheal, paratracheal, and prelaryngeal/Delphian lymph nodes) or upper/superior mediastinum
 - N1b Metastasis in other unilateral, bilateral or contralateral cervical (levels I, II, III, IV or V) or retropharyngeal

^c Reproduced with permission. Source: UICC TNM Classification of Malignant Tumours, 8th Edition, eds by James D. Brierley, Mary K. Gospodarowicz, Christian Wittekind. 2016, Publisher Wiley-Blackwell.

Definitions

CORE elements

CORE elements are those which are essential for the clinical management, staging or prognosis of the cancer. These elements will either have evidentiary support at Level III-2 or above (based on prognostic factors in the NHMRC levels of evidence¹). In rare circumstances, where level III-2 evidence is not available an element may be made a CORE element where there is unanimous agreement in the expert committee. An appropriate staging system e.g., Pathological TNM staging would normally be included as a CORE element.

The summation of all CORE elements is considered to be the minimum reporting standard for a specific cancer.

NON-CORE elements

NON-CORE elements are those which are unanimously agreed should be included in the dataset but are not supported by level III-2 evidence. These elements may be clinically important and recommended as good practice but are not yet validated or regularly used in patient management.

Key information other than that which is essential for clinical management, staging or prognosis of the cancer such as macroscopic observations and interpretation, which are fundamental to the histological diagnosis and conclusion e.g., macroscopic tumour details, may be included as either CORE or NON-CORE elements by consensus of the Dataset Authoring Committee.

[↑ Back](#)

Scope

The dataset has been developed for the pathology reporting of thyroid resection specimens for carcinoma. Core needle biopsies and metastasis to the thyroid gland are not included. Non-invasive follicular thyroid neoplasm with papillary-like nuclear features (NIFTP), tumours of uncertain malignant potential (UMP), thyroid carcinomas arising from struma ovarii, thyroid carcinomas arising in thyroglossal duct cysts, sarcoma and lymphoma are not covered in the dataset.

This dataset is designed for the reporting of a total thyroidectomy or a single laterality specimen i.e., left or right. If both are submitted separately or if surgeries are done at different time points (e.g., completion thyroidectomy after initial lobectomy), then separate datasets should be completed. If multiple carcinomas are found in the same specimen, the dataset should be completed for the most clinical relevant tumour which is the one with the highest T stage and/or the one that has the most aggressive histologic features. For example, in the case of a papillary thyroid carcinoma with gross extension into muscle associated with a papillary carcinoma without adverse histologic features, the dataset should be filled for the tumour with gross extra-thyroid extension. The less aggressive tumour should be reported with a description limited to basic histopathologic features (such as size and location) under the tumour focality element. If tumours of different lineage coincide in the same specimen, then a dataset should be completed for each of these tumours. For example, if a lobectomy contains separate medullary and papillary carcinoma, a dataset should be completed for each of these carcinomas.

[↑ Back](#)

Note 1 – Clinical information (Non-core)

Any clinical information relevant to the thyroid disease should be recorded.

If a pre-operative fine needle aspiration (FNA) or core biopsy has been performed, this should be recorded and the results of that biopsy briefly stated. If imaging has been performed, this should be recorded and the results briefly stated.

Previous thyroid surgery or medical treatments like anti-thyroid drug or radioactive iodine should be noted. Previous exposure of the neck to radiotherapy (e.g., for treatment of Hodgkin lymphoma) should be noted. The indication for performing the surgery should be recorded as many thyroid cancers are found incidentally in thyroid specimens removed for a purpose other than cancer.

Family history of thyroid cancers or features of other endocrine tumours or syndromes should be recorded. It is worth noting that gastrointestinal manifestations of an endocrine syndrome may present before identification of an endocrine tumour.

Clinical or biochemical evidence of hyperthyroidism or hypothyroidism should be noted.

↑ Back

Note 2 – Operative procedure (Core)

The thyroid gland ordinarily is composed of a right and a left lobe lying adjacent and lateral to the upper trachea and oesophagus. An isthmus connects both lobes, and in some cases a pyramidal lobe is present extending cephalad anterior to the thyroid cartilage. Surgical management of thyroid tumours consists of either a lobectomy (removal of a lobe), a hemithyroidectomy (resection of lobe and isthmus), subtotal thyroidectomy or total thyroidectomy. Cases with lobectomy followed by completion thyroidectomy in the same operative procedure should be classified as total thyroidectomies. Other procedures include completion thyroidectomy, central compartment or lateral neck node dissection.

↑ Back

Note 3 – Operative findings (Core)

It is expected that the surgeon provides information in regard to the presence or absence of gross extrathyroidal extension (ETE) at the time of the surgical procedure, as well as to the completeness of excision. Gross ETE is a crucial element in the most recent staging systems.^{2,3} The pathologist should indicate if the intra-operative data on gross ETE or margin completeness is not available at the time of pathology reporting.

↑ Back

Note 4 – Specimen(s) submitted (Core)

The nature of the specimen and laterality (in lobectomy specimens and node dissection) must be reported.

↑ Back

Note 5 – Tumour focality (Core and Non-core)

Multifocality (defined as more than one tumour focus) is not uncommon in patients with papillary carcinoma and medullary carcinoma and should be reported.

↑ Back

Note 6 – Tumour site (Core)

The thyroid may give rise to multiple foci of carcinoma in the same gland, designated as per the American Joint Committee on Cancer (AJCC) and Union for International Cancer Control (UICC) guidelines with the descriptor “(m)”.^{2,3} The designation of the tumour site and this dataset are applicable to the dominant excised carcinoma. The dominant tumour is defined as the most clinically relevant tumour because of its aggressiveness and/or its higher T stage. As such, it is often but not necessarily, the largest tumour. In cases of multiple lesions, the tumour characteristics of a second focus may be relevant and contribute to patient management, particularly if they are of a different histologic type (i.e., tumour 1 is papillary carcinoma and tumour 2 is medullary carcinoma). A second dataset should be generated for these instances. For additional tumour foci that do not alter management, only basic histopathological features (such as size and location) may be reported at the pathologist’s discretion.

↑ Back

Note 7 – Tumour dimensions (Core and Non-core)

The dimension is that of the microscopically proven dominant tumour, based upon a reconciliation of the imaging, macroscopic and microscopic findings. The dominant tumour is defined as the most clinically relevant tumour because of its aggressiveness and/or its higher T stage. As such, it is often, but not necessarily, the largest tumour. Tumour size has an impact on prognosis and is a component of TNM staging. For example, papillary carcinomas measuring 1 cm or less are associated with an excellent prognosis, while tumours measuring over 4 cm are associated with a worse prognosis.⁴ If the exact tumour size cannot be measured, the report should mention the reason such as specimen fragmentation or a grossly positive margin.

↑ Back

Note 8 – Histological tumour type (Core)

All tumours of the thyroid should be given a type based on the most recent edition of the World Health Organization (WHO) Classification of Tumours of Endocrine Organs.⁵

Papillary carcinoma

Papillary carcinoma is the most common carcinoma type and consists of numerous named variants, though only a few of these currently have sufficient evidence to be considered clinically and biologically relevant. Thus efforts should be made to flag or document the following variants when present:

- Classic (usual, conventional)
- Encapsulated/well demarcated follicular variant with invasion

- Infiltrative follicular variant
- Tall cell variant
- Cribriform-morular variant
- Diffuse sclerosing variant
- Encapsulated variant
- Microcarcinoma

Classical papillary thyroid carcinoma (PTC), tall cell and microcarcinoma variants

Classic (usual, conventional) papillary carcinoma is the most common and “default” variant of papillary carcinoma. Tall cell variant of papillary carcinoma is a more aggressive variant that has a higher prevalence of *BRAF* mutations and is more frequently refractory to radioactive iodine therapy.⁶⁻⁸ Papillary microcarcinomas are defined by their size (≤ 1 cm) and are extremely indolent and often incidental.⁵ In this dataset, it is recommended but not required that they are subtyped according to their cytoarchitectural features (e.g., papillary microcarcinoma, classical)

Follicular variant and related lesions

Follicular variant of papillary carcinoma is important to document because it has recently been substratified based on outcome into completely encapsulated/well demarcated and infiltrative follicular variants which completely or partially lack a capsule. Infiltrative follicular variants have a behaviour similar to classic papillary carcinoma, particularly in terms of propensity for nodal metastasis, while the behaviour of encapsulated/well circumscribed follicular variant is more indolent, especially if non-invasive.^{9,10}

Many non-invasive encapsulated/well circumscribed follicular variants of papillary thyroid carcinoma can now be reclassified under the new designation NIFTP. This shift in nomenclature arose as an effort to encourage conservative management of these lesions given their extremely low risk of structural recurrence.¹¹ It is noteworthy that the impact of this change worldwide varies according to countries. For example, many cases designated as NIFTP today were labelled in parts of Asia including Australia, as follicular adenomas and thus this new designation will have little effect on the practice of these pathologists. NIFTP remains an actionable surgical disease, albeit with a more conservative approach. As NIFTP is not overtly malignant, it is technically not required to report these under this cancer protocol. However it is encouraged to include them in the overall pathology report, though only limited parameters are relevant, namely size, laterality, and margin status.

It must be noted that not all tumours previously designated as non-invasive follicular variant of papillary thyroid carcinoma would qualify as NIFTP.¹¹ Several exclusionary criteria have been put forth in the initial publication of this entity in order to ensure that the NIFTP category remains indolent¹¹ and are as follows: solid/trabecular or insular growth $\geq 30\%$, $\geq 1\%$ true papillary growth (for more explanation see below), psammoma bodies, tumour necrosis, ≥ 3 mitosis/10 high power fields (HPFs) at 400x magnification, tall cell, columnar, or cribriform morular morphology. A key requirement for a NIFTP diagnosis is that the entire lesion border has been submitted for histologic evaluation. When a tumour fulfils these inclusion and exclusion criteria, NIFTP designation is appropriate. Of note, subcentimeter NIFTP and NIFTP with oncocytic features have been shown to have an outcome similar to NIFTP.^{12,13}

Multifocal NIFTP has not been well validated yet. In view of the small number of articles on these NIFTP scenarios, some pathologists do not label these unusual forms of this entity as NIFTP. In these situations, our opinion is that the designation, NIFTP, is not absolutely contraindicated. NIFTP is still an evolving diagnosis, and certain problematic areas have already been noted such as the quantification of true papillae. Because the initial criterion of $<1\%$ ¹¹ papillae was noted to be subjective and difficult to apply, there was a suggestion that even 1 well-formed papilla as defined above should be considered exclusionary.¹⁴ Studies are underway to resolve this issue. When an

encapsulated non-invasive follicular patterned lesion with PTC nuclei does not fulfil the NIFTP inclusion criteria, they can be labelled as encapsulated variant. This variant is defined in the most recent WHO as an architecturally and cytologically typical PTC that is totally encapsulated but in the opinion of this expert panel it can be used to label encapsulated non-invasive follicular patterned lesions with PTC nuclei that do not meet the NIFTP criteria.⁵

If an encapsulated follicular patterned tumour has questionable capsular/vascular invasion, the term of uncertain malignant potential (UMP) is used as a qualifier. These tumours are not required to be reported using this thyroid cancer protocol since their malignant potential has not been demonstrated yet. When the nuclear features of PTC are absent, these lesions are labelled as follicular tumour of uncertain malignant potential (FTUMP) while if PTC nuclei are questionable or present the designation well differentiated tumour of uncertain malignant potential (WTUMP) is used.⁵

Diffuse sclerosing variant and cribriform-morular variants

The cribriform morular variant is a biologically distinct variant characterized by *APC* or beta-catenin mutations and shows an association with familial adenomatous polyposis coli, in some cases preceding recognition of colon polyps or other extracolonic manifestations.¹⁵ Diffuse sclerosing variant is a locoregionally aggressive variant with a high rate of nodal metastasis and locoregional recurrence, though overall survival is good possibly because of the young age of the patients. Nonetheless, this variant appears to necessitate more aggressive initial surgical management including more extensive node dissection.¹⁶

Other variants that may have prognostic and therapeutic value but are rare and not well validated include:

- Clear cell
- Hobnail variant
- Oncocytic or oxyphilic
- Solid

Follicular and Hürthle (oncocytic) cell carcinomas

Follicular carcinoma is a well-differentiated carcinoma type defined by invasiveness in the absence of diagnostic nuclear features of papillary thyroid carcinoma. The diagnosis of follicular carcinoma and its distinction from follicular adenoma primarily depends on the identification of invasion of the tumour capsule and/or vascular spaces.

The most recent WHO classification subdivide these carcinomas into minimally invasive (capsular invasion (CI) only), encapsulated angioinvasive (any focus of vascular invasion) and widely invasive. The latter is defined as grossly apparent extensive invasion of the thyroid and/or extra-thyroid tissue with often prominent vascular invasion.⁵ These widely invasive carcinomas are often characterized by loss of encapsulation and multiple invasive fronts radiating from the epicenter of the tumour. Hürthle cell carcinoma is defined as a tumour composed of 75% of oncocytes lacking the nuclear features of papillary carcinoma demonstrating capsular and/or vascular invasion.⁵ In the most recent WHO classification of endocrine tumours, Hürthle cell carcinoma is no longer considered a variant of follicular carcinoma because of different (overall more aggressive) behaviour, different molecular profile and less radioactive iodine avidity.⁵ The definition of minimally invasive, angioinvasive and widely invasive Hürthle cell carcinoma mirrors those of follicular carcinoma.

Although pathologists can diagnose benign from malignant thyroid tumours with very high accuracy, there are extremely rare cases with distant metastasis in a setting of non-invasive follicular and

Hürthle cell carcinoma even after complete sampling of the tumour capsule.¹⁷ There are also very rare instances of regional nodal metastases without primary thyroid carcinoma found.¹⁸

While the majority of thyroid cancers are well differentiated, a subset are poorly differentiated (historically known as insular, or trabecular, carcinoma) or undifferentiated (anaplastic). These tumour types represent progression to a more aggressive phenotype and are often seen with co-existent or antecedent well-differentiated carcinoma. While detailed histomorphologic review is beyond the scope of this protocol, salient features of both tumour types are listed below.

Poorly differentiated thyroid carcinomas (PDTC)

Poorly differentiated thyroid carcinomas (PDTC) have a prognosis in between the well differentiated indolent papillary thyroid carcinoma and the often fatal anaplastic carcinoma. According to the most recent WHO classification, poorly differentiated carcinomas are tumours that display a solid, trabecular, and/or insular growth pattern, and show 1 or more of the following: 3 or more mitoses per 10 HPF, tumour necrosis, and nuclear convolution (without other nuclear features seen in papillary carcinoma).^{5,19} As defined, PDTC is not the only tumour type that has prognostic features intermediate between well-differentiated and undifferentiated (anaplastic) carcinoma.⁵ Other tumour types, including tall cell papillary carcinoma, can have guarded prognosis. Grading (based on high mitotic count and necrosis as used at Memorial Sloan-Kettering Cancer Center) identifies aggressive thyroid tumours of intermediate prognosis, regardless of their cytoarchitectural features.^{5,20} Of note, encapsulated poorly differentiated thyroid carcinomas appear to have a more favourable prognosis than unencapsulated tumours, particularly if they show no capsular or vascular invasion with adequate sampling.^{20,21}

Anaplastic (undifferentiated) carcinoma

Undifferentiated carcinoma represents the most extreme form of tumour progression and consists of a high-grade malignancy with spindled, pleomorphic, squamoid, or even rhabdoid morphology.²² Undifferentiated carcinoma is almost invariably rapidly lethal. A better differentiated component such as PTC or Hürthle cell carcinoma may be found and its presence should be mentioned.

↑ Back

Note 9 – Mitotic activity (Core)

The mitotic status should be reported in every thyroid carcinoma since it is an essential defining criterion for PDTC regardless of the definition used for this entity.^{19,20} The vast majority of thyroid carcinomas have a very low mitotic rate and a mitotic count is required only in those cases with elevated mitotic activity (≥ 3 mitoses/2 mm²). Mitotic count should be performed in the area of highest mitotic activity in 10 consecutive HPFs.^{21,23} The Ki-67 proliferation rate has been shown to correlate with outcome.^{24,25} It has not been utilized in the commonly used definitions of poorly differentiated thyroid carcinomas and thus is not a required element. It can however guide the pathologist to the area of highest mitotic activity.

↑ Back

Note 10 – Histological tumour grade (Non-core)

The grade in thyroid carcinomas of follicular cell origin (including both papillary and follicular carcinoma) impacts outcome significantly. It can however, be deduced from the histologic type along with increased mitotic activity and tumour necrosis, therefore this item is designated as non-core.

↑ Back

Note 11 – Tumour encapsulation/circumscription (Core)

The presence of a fibrous capsule or a well demarcated tumour border (i.e., well circumscribed tumour edge directly adjacent to benign thyroid parenchyma with no intervening capsule) is a crucial element in thyroid carcinomas. In follicular and Hürthle cell tumours, the invasion of the capsule and its vessels define malignancy.⁵ Even in high grade tumours such as poorly differentiated carcinoma, the presence of a capsule was shown to convey a better outcome.²⁰ When a tumour infiltrates the surrounding non-neoplastic parenchyma and is not completely encapsulated/well demarcated, it should be labeled as infiltrative. The infiltrative papillary carcinomas are usually different from their encapsulated counterparts in regard to metastatic spread (propensity for nodal rather than distant metastasis) and genetic mutations (*BRAFV600E* rather than RAS mutations).²⁶

↑ Back

Note 12 – Capsular invasion (Core)

There is no consensus as to the definition of capsular invasion (CI). While there is universal agreement that complete transgression of the capsule constitutes CI,²⁷ other authorities do not require complete transgression of the capsule.²⁸ Figure 1 depicts the various histologic appearances associated with the presence or absence of CI. According to Chan (2007),²⁷ a given neoplasm should not be diagnosed as carcinoma if complete capsular penetration cannot be proven after extensive sampling except in the following circumstance. This situation occurs when a satellite tumour nodule, morphologically similar to the main tumour, is lying just outside the tumour capsule (Figure 1e). This appearance results from failure to identify the point of capsular penetration. It is noteworthy that not all authors agree that these satellite nodules represent CI.²⁹ In equivocal cases of CI, the entire capsule, irrespective of tumour size, should be processed in the attempt to clarify whether CI is present. Deeper sections of the representative paraffin block(s) should be performed in the areas of concern in order to exclude CI.²⁷ Despite enhanced histologic examination, there are cases where the presence of CI is questionable. In this instance the term uncertain CI should be used. There is no need to report on the number of foci of CI since it has not been shown to have clinical value.

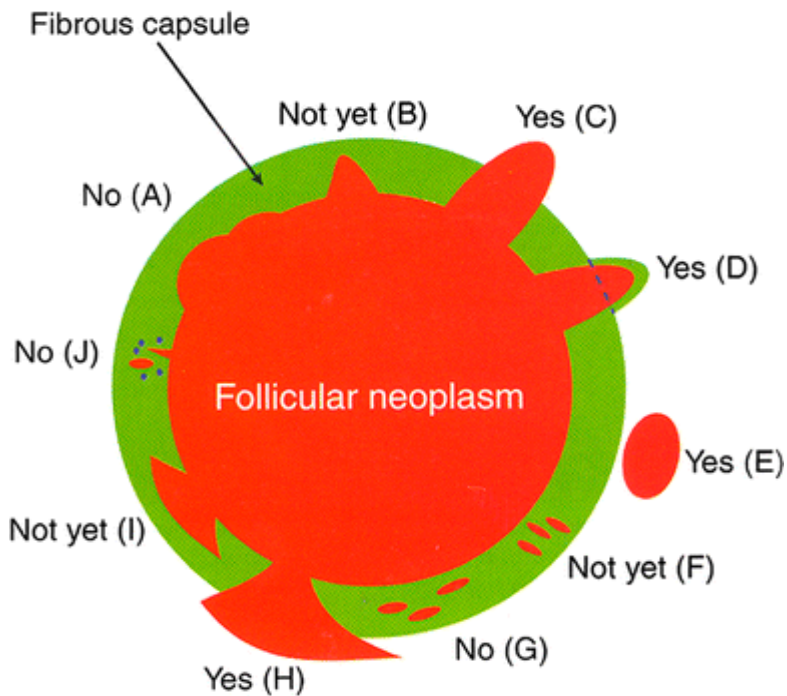


Figure 1: Capsular invasion

Capsular invasion (CI): Schematic drawing for the interpretation of the presence or absence of CI. The diagram depicts a follicular neoplasm (orange) surrounded by a fibrous capsule (green). **a** bosselation on the inner aspect of the capsule does not represent CI; **b** sharp tumour bud invades into but not through the capsule suggesting CI requiring deeper sections to exclude or confirm the presence of CI; **c** tumour totally transgresses the capsule invading beyond the outer contour of the capsule qualifying as CI; **d** tumour clothed by thin (probably new) fibrous capsule but already extending beyond an imaginary (dotted) line drawn through the outer contour of the capsule qualifying as CI; **e** satellite tumour nodule with similar features (architecture, cytomorphology) to the main tumour lying outside the capsule qualifying as CI; **f** Follicles aligned perpendicular to the capsule suggesting invasion requiring deeper sections to exclude or confirm the presence of CI; **g** Follicles aligned parallel to the capsule do not represent CI; **h** Mushroom-shaped tumour with total transgression of the capsule qualifies as CI; **i** mushroom-shaped tumour within but not through the capsule suggests invasion requiring deeper sections to exclude or confirm the presence of CI; **j** neoplastic follicles in the fibrous capsule with a degenerated appearance accompanied by lymphocytes and siderophages does not represent CI but rather capsular rupture related to prior FNA. Reproduced with permission from Chan J (2007). *Tumours of the thyroid and parathyroid glands*. Diagnostic Histopathology of Tumours. Fletcher CDM. Churchill Livingstone Elsevier, Philadelphia.²⁷

↑ Back

Note 13 – Lymphovascular invasion (Core and Non-core)

Since it is very difficult to differentiate vascular invasion from lymphatic invasion, the term lymphovascular invasion (LVI) is used in the pathology report to indicate invasion of vascular structures that may be lymphatic and/or blood vessels. The majority of authors agree that LVI should involve capsular or extra-capsular vessels in encapsulated tumours (Figure 2). In infiltrative tumours partially encapsulated or totally lacking a capsule, LVI can be present within the tumour nodule. These images (Figure 2) depict intracapsular LVI with tumour thrombus attached to the vessel wall, covered by endothelium or associated with fibrin. Tumour thrombus covered by endothelial cells qualifies as LVI (Figure 2b). However, endothelialization is not a requirement if the tumour is attached to the vessel wall (Figure 2c) or admixed with a fibrin thrombus (Figure 2d). If the tumour is

encapsulated, intra-tumoural or subcapsular vessels do not qualify for LVI and should not be interpreted as such (Figure 2a). One study has raised the caveat that tumour cells within vascular lumina unassociated with thrombus, and tumour cells underlying intact endothelium could represent “pseudoinvasion” given the fenestrated, endothelial network of endocrine organs.³⁰ When this more stringent criterion of LVI is applied, the incidence of LVI in differentiated thyroid carcinoma decreased drastically from 7-62%³¹⁻³⁵ to 3%,³⁰ while the risk of distant metastasis in association with the mere existence of LVI becomes 35%. This latter approach has not been validated by additional studies and may fail to identify a significant proportion of thyroid tumours with LVI, focal or extensive, that should be classified as carcinoma based on the presence of invasion, and that may benefit from appropriate risk stratification and/or additional therapies.

The consensus opinion is that the criteria used in Figure 2 to define LVI should be utilized. In regard to the extent of LVI, several papers have shown that the presence of 4-5 foci of LVI in encapsulated follicular/Hürthle cell carcinoma confers a much worse outcome than lower number of LVI foci.³⁶⁻³⁸ The most recent American Thyroid Association (ATA) guidelines classify a patient in a high risk category, if having 4 foci or more of vascular invasion (VI), while focal vascular invasion (VI) (<4 foci) in an intrathyroidal follicular carcinoma will put the patient in low risk group.³⁹ More importantly, the National Comprehensive Cancer Network (NCCN) 2019 guidelines have defined minimal vascular invasion as a few foci (1-4) of VI, and does not mandate radioiodine (RAI) administration in an intrathyroidal, well defined, follicular or Hürthle cell carcinoma, with minimal VI.⁴⁰ Consequently, it is important to report the extent of LVI in encapsulated thyroid carcinoma by counting the foci of LVI. It is noteworthy that most papers that validated the importance of LVI cutoffs have counted individual vessel sections invaded by tumour separately, as different foci. In regard to PTC, the presence of LVI was shown to impart poorer outcome.³⁴ Furthermore any focus of VI in PTC will put the patient in an intermediate risk category according to the most recent ATA guidelines.³⁹ It is therefore mandatory to report on the status of LVI in PTC (i.e., core item). There is no evidence that the number of LVI foci impact on prognosis in non-encapsulated PTC. Counting the LVI foci in non-encapsulated PTC is therefore not a core item. It is however a core item in those PTC who are completely encapsulated.

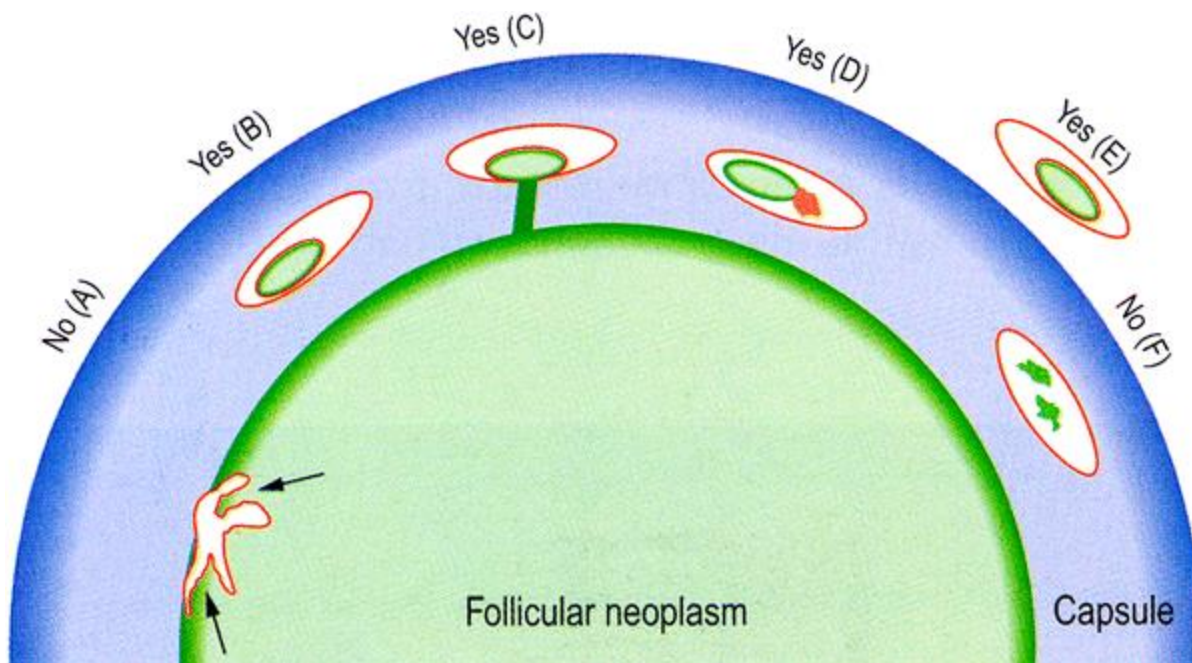


Figure 2: Lymphovascular invasion (LVI)

Schematic drawing for the interpretation of the presence or absence of LVI. The diagram depicts a follicular neoplasm (green) surrounded by a fibrous capsule (blue). **a** Bulging of tumour into vessels within the tumour proper does not constitute LVI. **b** Tumour thrombus covered by endothelial cells in intracapsular vessel qualifies as LVI. **c** Tumour thrombus in intracapsular vessel considered as LVI

since it is attached to the vessel wall. **d** Although not endothelialized, this tumour thrombus qualifies for LVI because it is accompanied by a fibrin thrombus. **e** Endothelialized tumour thrombus in vessel outside the tumour capsule represents LVI **f** Artefactual dislodgement of tumour manifesting as irregular tumour fragments into vascular lumen unaccompanied by endothelial covering or fibrin thrombus. Reproduced with permission from Chan J (2007). *Tumours of the thyroid and parathyroid glands*. Diagnostic Histopathology of Tumours. Fletcher CDM. Churchill Livingstone Elsevier, Philadelphia.²⁷

↑ Back

Note 14 – Necrosis (Core)

Tumour necrosis should be reported in every thyroid carcinoma since it is an essential defining criterion for PDTC regardless of the definition used for this entity.^{19,20} Tumour necrosis is defined as coagulative or comedo-necrosis and should be differentiated from infarct-like necrosis related to previous FNA or ischemic changes within the tumour. Reactive changes seen in the latter two situations such as hyalinization or fibrosis, haemorrhage, hemosiderin laden macrophages, cholesterol clefts or calcification, should be separated from coagulative necrosis.

↑ Back

Note 15 – Extrathyroidal extension (Core)

Extrathyroidal extension (ETE), defined as tumour extension beyond the thyroid capsule into the adjacent soft tissue, is a common pathologic finding detected in 23.5% of all papillary thyroid carcinomas.⁴¹ ETE has long been considered as an adverse prognostic factor with an increased risk of recurrence and mortality.⁴¹⁻⁴⁴ It can be further subdivided into two categories: 1) minimal (or microscopic) ETE, which is invasion into the immediate perithyroidal soft tissue, detected solely at microscopic level and not appreciated clinically or grossly at the time of surgery; and 2) extensive (or gross) ETE that is defined as gross direct extension of the carcinoma into strap muscles (e.g., sternohyoid, sternothyroid, thyrohyoid, and omohyoid muscles), subcutaneous tissue, adjacent viscera (e.g., larynx, trachea, and oesophagus), or recurrent laryngeal nerve, and is typically established clinically by imaging or during the operation. These two categories of ETE bear different prognostic values: the risk of recurrence associated with minor extrathyroidal extension is approximately 3 to 9%,⁴⁵⁻⁵¹ compared with 23 to 40% risk of recurrence in patients with gross ETE.^{45,46,48-50,52,53} Furthermore, several recent studies have shown that microscopic ETE is not an independent predictor for persistent disease, recurrence free survival and disease specific survival.^{47,48,51,53-55} NCCN 2019 guidelines recommend completion thyroidectomy and post-operative radioactive iodine (RAI) for lesions with gross ETE, while the administration of 30 mCi of iodine 131 is considered optional for patients with a primary tumour of <4 cm, clinical M0 and minor ETE.⁴⁰ Histologically, the thyroid gland is devoid of a well-defined capsule in many areas along its periphery, and the follicles are often intermingled with adipose tissue or even skeletal muscle.⁵⁶ Therefore, the very definition of microscopic ETE is problematic and subjective, and a universally accepted pathologic criterion for ETE is lacking. The fact that microscopic ETE is associated with poor interobserver agreement⁵⁶ and does not affect recurrence and survival raise concerns of whether microscopic ETE alone is sufficient to upstage a patient. Because of all the above, in the most recent AJCC and UICC 8th editions, microscopic ETE has been removed entirely from the staging system of differentiated thyroid carcinoma.^{2,3} Gross ETE invading strap muscles only, by a tumour of any size, will be staged as pT3b, while gross ETE with invasion into subcutaneous soft tissue, larynx, trachea, oesophagus, or recurrent laryngeal nerve will be staged as pT4a. In view of the above, the

pathologists' role is 1) to mention in their report the ETE seen histologically (whether microscopic or gross) and 2) communicate with the surgeon in regard to staging since the determination of gross ETE is done intra-operatively.

↑ Back

Note 16 – Margin status (Core and Non-core)

The margin status of a surgical resection for thyroid carcinoma is a core element and can be divided into three categories: a R0 resection (microscopically negative margin), a R1 resection (grossly complete resection with microscopically positive margin), and a R2 resection (grossly positive margin or incomplete resection).² The macroscopic status of the margins should be communicated to the pathologist by the operating surgeon. Histologically, a positive margin is defined by the presence of tumour cells at the inked tissue border and/or the outer aspect of the thyroid gland.⁵⁷⁻⁶⁰ Several recent studies have shown that microscopically positive margin is not an independent predictor for recurrence and disease free survival, especially after adjusting for tumour stage and ETE.⁵⁸⁻⁶⁰ Taken these into consideration, the current ATA guideline has only included incomplete R2 resection into the risk stratification as a feature of high risk lesions.³⁹ In contrast, the NCCN 2019 guideline has included any positive resection margin as one of the criteria to recommend completion thyroidectomy.⁴⁰ Lang et al (2016) have shown that a microscopic positive posterior margin is an independent predictor for recurrence free survival with a 23-fold risk of recurrence, while a positive anterior margin did not pose a significant risk for recurrence.⁵⁸ However, studies are scant on the prognostic effect of the positive margin location, hence, this is non-core. Nevertheless, we encourage pathologists to ink the anterior and posterior margins differently when processing thyroid specimens and document the status of anterior and posterior margins separately in the pathology report. There is no data to date on the prognostic value of close margins as an independent or co-variable. Therefore reporting distance of tumour to margin is non-core.

↑ Back

Note 17 – Lymph node status (Core)

Increasing evidence has shown that various characteristics of nodal metastases, e.g., number, size, and extranodal extension (ENE), may provide additional prognostic information. Thus, detailed features of nodal disease ought to be included in the pathology report, and be considered in risk stratification and staging systems.^{54,61-68} A recent meta-analysis by Randolph et al (2012) has shown that small volume subclinical microscopic pathologic N1 disease, i.e., five or fewer subcentimeter metastatic lymph nodes, conveys little prognostic impact on recurrence free survival and disease specific survival in PTC, compared with clinically evident macroscopic nodal disease involving more than 5 lymph nodes, especially those with ENE.⁶¹ The greatest dimension of the largest metastatic deposit in a lymph node should be measured. It is accepted it can be difficult to distinguish multiple small metastases in one large deposit. Many authors recommend measuring the greatest dimension end to end in a single slide including discontinuous deposits.⁶⁹ Taking this data into consideration, the NCCN 2019 guidelines no longer recommend completion thyroidectomy and post-operative RAI in small volume pN1a disease, i.e., <5 involved nodes with metastasis <2 mm in largest dimension.⁴⁰ Histologic features of the nodal metastasis that have been incorporated in the ATA initial risk stratifications included number of involved lymph nodes (>5 is considered as intermediate risk) and size of the metastatic lymph nodes (≥3 cm as high risk). The presence of psammoma bodies alone in a node is subject to controversy. While some practicing pathologists do not consider these as

metastasis, we are in agreement with the College of American Pathologists in considering these lymph nodes as positive for metastatic carcinoma.²³

Extranodal extension is not an uncommon finding, being reported in up to 12% of PTC overall and 33% of nodal metastatic PTC.^{54,65} Similar to ETE, a well-defined, consensus, histologic diagnostic criterion for ENE is currently lacking.^{23,70} A recent study by Du et al (2016) has shown that involvement of perinodal adipose tissue appears to be the most consistent diagnostic criteria of ENE, being considered by eleven participating endocrine pathologists as ENE.⁷⁰ However, the overall agreement in diagnosing ENE is only fair among expert pathologists.⁷⁰ Nevertheless, studies have repeatedly demonstrated the association between ENE and persistent and/or recurrence disease.^{54,61-67} Hence, it is important to document ENE in the pathology report of a differentiated thyroid carcinoma.

A seven compartment nomenclature is used to define anatomic lymph nodes compartments. Central neck refers to level VI (peri-thyroidal, paralaryngeal, paratracheal, and prelaryngeal (Delphian)) and VII (upper mediastinal). Lateral neck refers to level I (submental/submandibular), II (upper jugular), III (mid jugular), IV (lower jugular) and V (posterior triangle).⁷¹

At the current time, no additional special techniques should be used other than routine histology for the assessment of nodal metastases (i.e., sentinel lymph node-type protocols are not advocated). However, confirmation by immunohistochemical staining, including thyroglobulin for papillary carcinoma and calcitonin and neuroendocrine markers (e.g., chromogranins, synaptophysin) for medullary carcinoma, may be required.

↑ Back

Note 18 – C-cell hyperplasia (Non-core)

The presence of C-cell hyperplasia may suggest hereditary disease and should therefore be reported in specimens harbouring medullary thyroid carcinoma.

↑ Back

Note 19 – Coexistent pathology (Core)

The presence of chronic lymphocytic thyroiditis, follicular adenoma, Hürthle cell adenoma, NIFTP and nodular hyperplasia for example can help explain the clinical/imaging/cytologic findings.

↑ Back

Note 20 – Parathyroid gland status (Core)

The number and status of the parathyroid glands in the specimen should be mentioned for surgical quality assurance purposes.

↑ Back

Note 21 – Ancillary studies (Non-core)

Ancillary studies may be used to determine lineage, disease classification or subclassification; as prognostic biomarkers; or to indicate the likelihood of patient response to specific biological therapies.

In cases in which the diagnosis is suspected to be medullary carcinoma, immunostaining for calcitonin, chromogranin, synaptophysin, carcinoembryonic antigen (CEA) and thyroglobulin may be performed to confirm the diagnosis. The calcitonin, CEA, chromogranin and synaptophysin immunostains are also helpful to identify C-cell hyperplasia.

Thyroglobulin, thyroid transcription factor-1 (TTF-1) and PAX8 may indicate that a tumour is of follicular cell origin. TTF-1 is more sensitive than thyroglobulin however, TTF-1 can be positive in other cancers such as lung adenocarcinoma and small cell carcinoma of any primary site. Anaplastic thyroid carcinoma is negative for thyroglobulin, positive focally for TTF-1 in a small percentage of cases, but labels for PAX-8 in a substantial number of cases.⁷²

It is not possible to differentiate benign and malignant thyroid tumours by using immunohistochemistry. Although cytokeratin 19, other high molecular weight cytokeratins and some other markers have been demonstrated to have stronger positivity in thyroid carcinomas than benign thyroid lesions, there are many exceptions and the interpretation has to be taken in the context of the morphology of the lesion.

Molecular analyses are currently being performed to identify targets in tumour refractory to radioactive iodine therapy. Immunostain for *BRAFV600E* mutation is an easy to perform, robust and rapid assay to select patients for *BRAF* inhibitor therapy.

↑ Back

Note 22 – Histologically confirmed distant metastases (Core)

The presence of histologically confirmed distant metastasis is a key component of staging.^{2,3}

↑ Back

Note 23 – Pathological staging (Core)

The staging applies to all tumour types, including anaplastic carcinoma, which hitherto had automatically been staged as stage 4 irrespective of all other details.

The UICC TNM 8th edition staging applies to carcinomas and includes papillary, follicular, poorly differentiated, Hürthle cell (oncocytic), anaplastic, and medullary carcinoma.³

Multifocal tumours (≥ 2 foci) of all histological types should be designated (m), with the largest and/or most invasive focus determining the classification, e.g., pT2(m).

↑ Back

References

- 1 Merlin T, Weston A and Tooher R (2009). Extending an evidence hierarchy to include topics other than treatment: revising the Australian 'levels of evidence'. *BMC Med Res Methodol* 9:34.
- 2 Amin MB, Edge S, Greene FL, Byrd DR, Brookland RK, Washington MK, Gershenwald JE, Compton CC, Hess KR, Sullivan DC, Jessup JM, Brierley JD, Gaspar LE, Schilsky RL, Balch CM, Winchester DP, Asare EA, Madera M, Gress DM and Meyer LR (eds) (2017). *AJCC Cancer Staging Manual. 8th ed.* Springer., New York.
- 3 International Union against Cancer (2017). *TNM Classification of Malignant Tumours (8th Edition)*. Brierley JD, Gospodarowicz MK and Wittekind C (eds). Wiley-Blackwell., New York.
- 4 Machens A, Holzhausen HJ and Dralle H (2005). The prognostic value of primary tumor size in papillary and follicular thyroid carcinoma. *Cancer* 103(11):2269-2273.
- 5 Lloyd R, Osamura R, Klöppel G and Rosai J (eds) (2017). *WHO Classification of Tumours of Endocrine Organs, 4th ed.* IARC Press, Lyon.
- 6 Rivera M, Ghossein RA, Schoder H, Gomez D, Larson SM and Tuttle RM (2008). Histopathologic characterization of radioactive iodine-refractory fluorodeoxyglucose-positron emission tomography-positive thyroid carcinoma. *Cancer* 113(1):48-56.
- 7 Morris LG, Shaha AR, Tuttle RM, Sikora AG and Ganly I (2010). Tall-cell variant of papillary thyroid carcinoma: a matched-pair analysis of survival. *Thyroid* 20(2):153-158.
- 8 Nikiforov YE and Nikiforova MN (2011). Molecular genetics and diagnosis of thyroid cancer. *Nat Rev Endocrinol* 7(10):569-580.
- 9 Rivera M, Tuttle RM, Patel S, Shaha A, Shah JP and Ghossein RA (2009). Encapsulated papillary thyroid carcinoma: a clinico-pathologic study of 106 cases with emphasis on its morphologic subtypes (histologic growth pattern). *Thyroid* 19(2):119-127.
- 10 Liu J, Singh B, Tallini G, Carlson DL, Katabi N, Shaha A, Tuttle RM and Ghossein RA (2006). Follicular variant of papillary thyroid carcinoma: a clinicopathologic study of a problematic entity. *Cancer* 107(6):1255-1264.
- 11 Nikiforov YE, Seethala RR, Tallini G, Baloch ZW, Basolo F, Thompson LD, Barletta JA, Wenig BM, Al Ghuzlan A, Kakudo K, Giordano TJ, Alves VA, Khanafshar E, Asa SL, El-Naggar AK, Gooding WE, Hodak SP, Lloyd RV, Maytal G, Mete O, Nikiforova MN, Nose V, Papotti M, Poller DN, Sadow PM, Tischler AS, Tuttle RM, Wall KB, LiVolsi VA, Randolph GW and Ghossein RA (2016). Nomenclature Revision for Encapsulated Follicular Variant of Papillary Thyroid Carcinoma: A Paradigm Shift to Reduce Overtreatment of Indolent Tumors. *JAMA Oncol* 2(8):1023-1029.
- 12 Xu B, Farhat N, Barletta JA, Hung YP, Biase D, Casadei GP, Onenerk AM, Tuttle RM, Roman BR, Katabi N, Nose V, Sadow P, Tallini G, Faquin WC and Ghossein R (2018). Should subcentimeter non-invasive encapsulated, follicular variant of papillary thyroid carcinoma be included in the noninvasive follicular thyroid neoplasm with papillary-like nuclear features category? *Endocrine* 59(1):143-150.

- 13 Xu B, Reznik E, Tuttle RM, Knauf J, Fagin JA, Katabi N, Dogan S, Aleynick N, Seshan V, Middha S, Enepekides D, Casadei GP, Solaroli E, Tallini G, Ghossein R and Ganly I (2019). Outcome and molecular characteristics of non-invasive encapsulated follicular variant of papillary thyroid carcinoma with oncocytic features. *Endocrine* 64(1):97-108.
- 14 Lloyd RV, Asa SL, LiVolsi VA, Sadow PM, Tischler AS, Ghossein RA, Tuttle RM and Nikiforov YE (2018). The evolving diagnosis of noninvasive follicular thyroid neoplasm with papillary-like nuclear features (NIFTP). *Hum Pathol* 74:1-4.
- 15 Cameselle-Teijeiro J and Chan JK (1999). Cribriform-morular variant of papillary carcinoma: a distinctive variant representing the sporadic counterpart of familial adenomatous polyposis-associated thyroid carcinoma? *Mod Pathol* 12(4):400-411.
- 16 Regalbuto C, Malandrino P, Tumminia A, Le Moli R, Vigneri R and Pezzino V (2011). A diffuse sclerosing variant of papillary thyroid carcinoma: clinical and pathologic features and outcomes of 34 consecutive cases. *Thyroid* 21(4):383-389.
- 17 Glomski K, Nose V, Faquin WC and Sadow PM (2017). Metastatic Follicular Thyroid Carcinoma and the Primary Thyroid Gross Examination: Institutional Review of Cases from 1990 to 2015. *Endocr Pathol* 28(2):177-185.
- 18 Xu B, Scognamiglio T, Cohen PR, Prasad ML, Hasanovic A, Tuttle RM, Katabi N and Ghossein RA (2017). Metastatic thyroid carcinoma without identifiable primary tumor within the thyroid gland: a retrospective study of a rare phenomenon. *Hum Pathol* 65:133-139.
- 19 Volante M, Collini P, Nikiforov YE, Sakamoto A, Kakudo K, Katoh R, Lloyd RV, LiVolsi VA, Papotti M, Sobrinho-Simoes M, Bussolati G and Rosai J (2007). Poorly differentiated thyroid carcinoma: the Turin proposal for the use of uniform diagnostic criteria and an algorithmic diagnostic approach. *Am J Surg Pathol* 31(8):1256-1264.
- 20 Hiltzik D, Carlson DL, Tuttle RM, Chuai S, Ishill N, Shaha A, Shah JP, Singh B and Ghossein RA (2006). Poorly differentiated thyroid carcinomas defined on the basis of mitosis and necrosis: a clinicopathologic study of 58 patients. *Cancer* 106(6):1286-1295.
- 21 Rivera M, Ricarte-Filho J, Patel S, Tuttle M, Shaha A, Shah JP, Fagin JA and Ghossein RA (2010). Encapsulated thyroid tumors of follicular cell origin with high grade features (high mitotic rate/tumor necrosis): a clinicopathologic and molecular study. *Hum Pathol* 41(2):172-180.
- 22 Nikiforov YE and Seethala RR (2012). *Anaplastic (undifferentiated) carcinoma*. In *Diagnostic Pathology and Molecular Genetics of the Thyroid: Second Edition*. Diagnostic Pathology and Molecular Genetics of the Thyroid: Second Edition. Nikiforov YE, Biddinger PW and Thompson LDR (eds). Lippincott Williams and Wilkins, Philadelphia.
- 23 College of American Pathologists (2019). *Protocol for the Examination of Specimens From Patients With Carcinomas of the Thyroid Gland*. Available from: <https://www.cap.org/protocols-and-guidelines/cancer-reporting-tools/cancer-protocol-templates> (Accessed 1st May 2019).
- 24 Saltman B, Singh B, Hedvat CV, Wreesmann VB and Ghossein R (2006). Patterns of expression of cell cycle/apoptosis genes along the spectrum of thyroid carcinoma progression. *Surgery* 140(6):899-905; discussion 905-896.

- 25 Kakudo K, Wakasa T, Ohta Y, Yane K, Ito Y and Yamashita H (2015). Prognostic classification of thyroid follicular cell tumors using Ki-67 labeling index: risk stratification of thyroid follicular cell carcinomas. *Endocr J* 62(1):1-12.
- 26 Rivera M, Ricarte-Filho J, Knauf J, Shaha A, Tuttle M, Fagin JA and Ghossein RA (2010). Molecular genotyping of papillary thyroid carcinoma follicular variant according to its histological subtypes (encapsulated vs infiltrative) reveals distinct BRAF and RAS mutation patterns. *Mod Pathol* 23(9):1191-1200.
- 27 Chan J (2007). Tumours of the thyroid and parathyroid glands. In: *Diagnostic Histopathology of Tumours*. Fletcher CDM. Churchill Livingstone Elsevier, Philadelphia.
- 28 Thompson LD, Wieneke JA, Paal E, Frommelt RA, Adair CF and Heffess CS (2001). A clinicopathologic study of minimally invasive follicular carcinoma of the thyroid gland with a review of the English literature. *Cancer* 91(3):505-524.
- 29 Suster S (2006). Thyroid tumors with a follicular growth pattern: problems in differential diagnosis. *Arch Pathol Lab Med* 130(7):984-988.
- 30 Mete O and Asa SL (2011). Pathological definition and clinical significance of vascular invasion in thyroid carcinomas of follicular epithelial derivation. *Mod Pathol* 24(12):1545-1552.
- 31 Xu B, Wang L, Tuttle RM, Ganly I and Ghossein R (2015). Prognostic impact of extent of vascular invasion in low-grade encapsulated follicular cell-derived thyroid carcinomas: a clinicopathologic study of 276 cases. *Hum Pathol* 46(12):1789-1798.
- 32 Cao J, Hu JL, Chen C, Wang QL, Fang XH, Zhang Y and Ge MH (2016). Vascular invasion is an independent prognostic factor for distant recurrence-free survival in papillary thyroid carcinoma: a matched-case comparative study. *J Clin Pathol* 69(10):872-877.
- 33 Kim HJ, Sung JY, Oh YL, Kim JH, Son YI, Min YK, Kim SW and Chung JH (2014). Association of vascular invasion with increased mortality in patients with minimally invasive follicular thyroid carcinoma but not widely invasive follicular thyroid carcinoma. *Head Neck* 36(12):1695-1700.
- 34 Wreesmann VB, Nixon IJ, Rivera M, Katabi N, Palmer F, Ganly I, Shaha AR, Tuttle RM, Shah JP, Patel SG and Ghossein RA (2015). Prognostic value of vascular invasion in well-differentiated papillary thyroid carcinoma. *Thyroid* 25(5):503-508.
- 35 Falvo L, Catania A, D'Andrea V, Marzullo A, Giustiniani MC and De Antoni E (2005). Prognostic importance of histologic vascular invasion in papillary thyroid carcinoma. *Ann Surg* 241(4):640-646.
- 36 Collini P, Sampietro G and Pilotti S (2004). Extensive vascular invasion is a marker of risk of relapse in encapsulated non-Hurthle cell follicular carcinoma of the thyroid gland: a clinicopathological study of 18 consecutive cases from a single institution with a 11-year median follow-up. *Histopathology* 44(1):35-39.
- 37 Ghossein RA, Hiltzik DH, Carlson DL, Patel S, Shaha A, Shah JP, Tuttle RM and Singh B (2006). Prognostic factors of recurrence in encapsulated Hurthle cell carcinoma of the thyroid gland: a clinicopathologic study of 50 cases. *Cancer* 106(8):1669-1676.

- 38 Lang W, Choritz H and Hundeshagen H (1986). Risk factors in follicular thyroid carcinomas. A retrospective follow-up study covering a 14-year period with emphasis on morphological findings. *Am J Surg Pathol* 10(4):246-255.
- 39 Haugen BR, Alexander EK, Bible KC, Doherty GM, Mandel SJ, Nikiforov YE, Pacini F, Randolph GW, Sawka AM, Schlumberger M, Schuff KG, Sherman SI, Sosa JA, Steward DL, Tuttle RM and Wartofsky L (2016). 2015 American Thyroid Association Management Guidelines for Adult Patients with Thyroid Nodules and Differentiated Thyroid Cancer: The American Thyroid Association Guidelines Task Force on Thyroid Nodules and Differentiated Thyroid Cancer. *Thyroid* 26(1):1-133.
- 40 National Comprehensive Cancer Network. *Thyroid Cancer* (Version 2.2019). Available from: https://www.nccn.org/professionals/physician_gls/pdf/thyroid.pdf (Accessed 1st November 2019).
- 41 Ortiz S, Rodriguez JM, Soria T, Perez-Flores D, Pinero A, Moreno J and Parrilla P (2001). Extrathyroid spread in papillary carcinoma of the thyroid: clinicopathological and prognostic study. *Otolaryngol Head Neck Surg* 124(3):261-265.
- 42 Andersen PE, Kinsella J, Loree TR, Shaha AR and Shah JP (1995). Differentiated carcinoma of the thyroid with extrathyroidal extension. *Am J Surg* 170(5):467-470.
- 43 Carcangiu ML, Zampi G, Pupi A, Castagnoli A and Rosai J (1985). Papillary carcinoma of the thyroid. A clinicopathologic study of 241 cases treated at the University of Florence, Italy. *Cancer* 55(4):805-828.
- 44 McConahey WM, Hay ID, Woolner LB, van Heerden JA and Taylor WF (1986). Papillary thyroid cancer treated at the Mayo Clinic, 1946 through 1970: initial manifestations, pathologic findings, therapy, and outcome. *Mayo Clin Proc* 61(12):978-996.
- 45 Ito Y, Tomoda C, Uruno T, Takamura Y, Miya A, Kobayashi K, Matsuzuka F, Kuma K and Miyauchi A (2006). Prognostic significance of extrathyroid extension of papillary thyroid carcinoma: massive but not minimal extension affects the relapse-free survival. *World J Surg* 30(5):780-786.
- 46 Jukkola A, Bloigu R, Ebeling T, Salmela P and Blanco G (2004). Prognostic factors in differentiated thyroid carcinomas and their implications for current staging classifications. *Endocr Relat Cancer* 11(3):571-579.
- 47 Nixon IJ, Ganly I, Patel S, Palmer FL, Whitcher MM, Tuttle RM, Shaha AR and Shah JP (2011). The impact of microscopic extrathyroid extension on outcome in patients with clinical T1 and T2 well-differentiated thyroid cancer. *Surgery* 150(6):1242-1249.
- 48 Radowsky JS, Howard RS, Burch HB and Stojadinovic A (2014). Impact of degree of extrathyroidal extension of disease on papillary thyroid cancer outcome. *Thyroid* 24(2):241-244.
- 49 Riemann B, Kramer JA, Schmid KW, Dralle H, Dietlein M, Schicha H, Sauerland C, Frankewitsch T and Schober O (2010). Risk stratification of patients with locally aggressive differentiated thyroid cancer. Results of the MSDS trial. *Nuklearmedizin* 49(3):79-84.

- 50 Ito Y, Tomoda C, Uruno T, Takamura Y, Miya A, Kobayashi K, Matsuzuka F, Kuma K and Miyauchi A (2006). Minimal extrathyroid extension does not affect the relapse-free survival of patients with papillary thyroid carcinoma measuring 4 cm or less over the age of 45 years. *Surg Today* 36(1):12-18.
- 51 Shin JH, Ha TK, Park HK, Ahn MS, Kim KH, Bae KB, Kim TH, Choi CS, Kim TK, Bae SK and Kim SH (2013). Implication of minimal extrathyroidal extension as a prognostic factor in papillary thyroid carcinoma. *Int J Surg* 11(9):944-947.
- 52 Fukushima M, Ito Y, Hirokawa M, Miya A, Shimizu K and Miyauchi A (2010). Prognostic impact of extrathyroid extension and clinical lymph node metastasis in papillary thyroid carcinoma depend on carcinoma size. *World J Surg* 34(12):3007-3014.
- 53 Xu B, Ibrahimasic T, Wang L, Sabra MM, Migliacci JC, Tuttle RM, Ganly I and Ghossein R (2016). Clinicopathologic Features of Fatal Non-Anaplastic Follicular Cell-Derived Thyroid Carcinomas. *Thyroid* 26(11):1588-1597.
- 54 Kim JW, Roh JL, Gong G, Cho KJ, Choi SH, Nam SY and Kim SY (2017). Extent of Extrathyroidal Extension as a Significant Predictor of Nodal Metastasis and Extranodal Extension in Patients with Papillary Thyroid Carcinoma. *Ann Surg Oncol* 24(2):460-468.
- 55 Rivera M, Ricarte-Filho J, Tuttle RM, Ganly I, Shaha A, Knauf J, Fagin J and Ghossein R (2010). Molecular, morphologic, and outcome analysis of thyroid carcinomas according to degree of extrathyroid extension. *Thyroid* 20(10):1085-1093.
- 56 Su HK, Wenig BM, Haser GC, Rowe ME, Asa SL, Baloch Z, Du E, Faquin WC, Fellegara G, Giordano T, Ghossein R, LiVolsi VA, Lloyd R, Mete O, Ozbek U, Rosai J, Suster S, Thompson LD, Turk AT and Urken ML (2016). Inter-Observer Variation in the Pathologic Identification of Minimal Extrathyroidal Extension in Papillary Thyroid Carcinoma. *Thyroid* 26(4):512-517.
- 57 Hong CM, Ahn BC, Park JY, Jeong SY, Lee SW and Lee J (2012). Prognostic implications of microscopic involvement of surgical resection margin in patients with differentiated papillary thyroid cancer after high-dose radioactive iodine ablation. *Ann Nucl Med* 26(4):311-318.
- 58 Lang BH, Shek TW and Wan KY (2016). Does microscopically involved margin increase disease recurrence after curative surgery in papillary thyroid carcinoma? *J Surg Oncol* 113(6):635-639.
- 59 Kluijfhout WP, Pasternak JD, Kwon JS, Lim J, Shen WT, Gosnell JE, Khanafshar E, Duh QY and Suh I (2016). Microscopic Positive Tumor Margin Does Not Increase the Risk of Recurrence in Patients with T1-T2 Well-Differentiated Thyroid Cancer. *Ann Surg Oncol* 23(5):1446-1451.
- 60 Wang LY, Ghossein R, Palmer FL, Nixon IJ, Tuttle RM, Shaha AR, Shah JP, Patel SG and Ganly I (2015). Microscopic Positive Margins in Differentiated Thyroid Cancer Is Not an Independent Predictor of Local Failure. *Thyroid* 25(9):993-998.
- 61 Randolph GW, Duh QY, Heller KS, LiVolsi VA, Mandel SJ, Steward DL, Tufano RP and Tuttle RM (2012). The prognostic significance of nodal metastases from papillary thyroid carcinoma can be stratified based on the size and number of metastatic lymph nodes, as well as the presence of extranodal extension. *Thyroid* 22(11):1144-1152.

- 62 Wu MH, Shen WT, Gosnell J and Duh QY (2015). Prognostic significance of extranodal extension of regional lymph node metastasis in papillary thyroid cancer. *Head Neck* 37(9):1336-1343.
- 63 Alpert EH, Wenig BM, Dewey EH, Su HK, Dos Reis L and Urken ML (2015). Size distribution of metastatic lymph nodes with extranodal extension in patients with papillary thyroid cancer: a pilot study. *Thyroid* 25(2):238-241.
- 64 Moritani S (2014). Impact of invasive extranodal extension on the prognosis of patients with papillary thyroid carcinoma. *Thyroid* 24(12):1779-1783.
- 65 Lango M, Flieder D, Arrangoiz R, Veloski C, Yu JQ, Li T, Burtness B, Mehra R, Galloway T and Ridge JA (2013). Extranodal extension of metastatic papillary thyroid carcinoma: correlation with biochemical endpoints, nodal persistence, and systemic disease progression. *Thyroid* 23(9):1099-1105.
- 66 Ito Y, Hirokawa M, Jikuzono T, Higashiyama T, Takamura Y, Miya A, Kobayashi K, Matsuzuka F, Kuma K and Miyauchi A (2007). Extranodal tumor extension to adjacent organs predicts a worse cause-specific survival in patients with papillary thyroid carcinoma. *World J Surg* 31(6):1194-1201.
- 67 Asanuma K, Kusama R, Maruyama M, Fujimori M and Amano J (2001). Macroscopic extranodal invasion is a risk factor for tumor recurrence in papillary thyroid cancer. *Cancer Lett* 164(1):85-89.
- 68 Ricarte-Filho J, Ganly I, Rivera M, Katabi N, Fu W, Shaha A, Tuttle RM, Fagin JA and Ghossein R (2012). Papillary thyroid carcinomas with cervical lymph node metastases can be stratified into clinically relevant prognostic categories using oncogenic BRAF, the number of nodal metastases, and extra-nodal extension. *Thyroid* 22(6):575-584.
- 69 Bullock MJ, Beitler JJ, Carlson DL, Fonseca I, Hunt JL, Katabi N, Sloan P, Taylor SM, Williams MD and Thompson LDR (2019). Data Set for the Reporting of Nodal Excisions and Neck Dissection Specimens for Head and Neck Tumors: Explanations and Recommendations of the Guidelines From the International Collaboration on Cancer Reporting. *Arch Pathol Lab Med* 143(4):452-462.
- 70 Du E, Wenig BM, Su HK, Rowe ME, Haser GC, Asa SL, Baloch Z, Faquin WC, Fellegara G, Giordano T, Ghossein R, LiVolsi VA, Lloyd R, Mete O, Ozbek U, Rosai J, Suster S, Thompson LD, Turk AT and Urken ML (2016). Inter-Observer Variation in the Pathologic Identification of Extranodal Extension in Nodal Metastasis from Papillary Thyroid Carcinoma. *Thyroid* 26(6):816-819.
- 71 Tuttle RM, Morris LF, Haugen BR, Shah JT, Sosa JA, Rohren E, Subramaniam RM, Hunt JL and Perrier ND (2017). Thyroid- differentiated and anaplastic carcinoma. In: *AJCC Cancer Staging Manual 8th edition*. Amin MB, Edge S, Greene FL, Byrd DR, Brookland RK, Washington MK, Gershenwald JE, Compton CC, Hess KR, Sullivan DC, Jessup JM, Brierley JD, Gaspar LE, Schilsky RL, Balch CM, Winchester DP, Asare EA, Madera M, Gress DM and Meyer LR (eds). Springer., New York
- 72 Nonaka D, Tang Y, Chiriboga L, Rivera M and Ghossein R (2008). Diagnostic utility of thyroid transcription factors Pax8 and TTF-2 (FoxE1) in thyroid epithelial neoplasms. *Mod Pathol* 21(2):192-200.