



# Hepatoblastoma Histopathology Reporting Guide

Family/Last name Date of birth Given name(s) Patient identifiers Date of request Accession/Laboratory number Elements in **black text** are **CORE**. Elements in **grey text** are **NON-CORE**.

SCOPE OF THIS DATASET

 indicates multi-select values  indicates single select values**CLINICAL INFORMATION** (Note 1)*(Applicable to primary resections only)* Information not provided**Age (years)** 0-<1  ≥1-<8  ≥8**Serum alpha fetoprotein (AFP) level at diagnosis (ng/mL)** Information not provided <100 100-1.2 million >1.2 million**Preoperative chemotherapy** Information not provided No known preoperative therapy Preoperative therapy given, *specify***History of prematurity** Yes  No**Associated genetic syndromes, malformations or other conditions, specify****PRETEXT clinical staging, specify****Low birth weight (<1,500 grams)** Yes  No**Other clinical information, specify****OPERATIVE PROCEDURE** (Note 2) Not specified Right lobectomy Extended right lobectomy Medial segmentectomy Left lateral segmentectomy Total left lobectomy Orthotopic liver transplant Non-anatomic/wedge resection Other, *specify***TUMOUR SITE** (Note 3) Not specified Left lobe Right lobe Other, *specify***TUMOUR FOCALITY** (Note 4) Cannot be determined Unifocal MultifocalSpecify number of tumours **TUMOUR DIMENSIONS<sup>a</sup>** (Note 5)**Nodule 1**Greatest dimension  mmAdditional dimensions  mm ×  mm**Nodule 2**Greatest dimension  mmAdditional dimensions  mm ×  mm**Nodule 3**Greatest dimension  mmAdditional dimensions  mm ×  mm Cannot be assessed, *specify*<sup>a</sup> Specify for each nodule.**BLOCK IDENTIFICATION KEY** (Note 6)*(List overleaf or separately with an indication of the nature and origin of all tissue blocks)*

**HISTOLOGICAL TUMOUR TYPE** (select all that apply) (Note 7)

(Value list based on the World Health Organization Classification of Paediatric Tumours (2023))

- Hepatoblastoma, epithelial type, fetal pattern (mitotically inactive/well differentiated, well-differentiated fetal)
- Hepatoblastoma, epithelial type, fetal pattern (mitotically active/crowded)
- Hepatoblastoma, epithelial type, embryonal pattern
- Hepatoblastoma, epithelial type, pleomorphic pattern (poorly differentiated)
- Hepatoblastoma, epithelial type, macrotrabecular pattern
- Hepatoblastoma, epithelial type, small cell undifferentiated pattern
- Hepatoblastoma, epithelial and mesenchymal type, without teratoid features
- Hepatoblastoma, epithelial and mesenchymal type, with teratoid features
- Hepatocellular neoplasm, NOS
- Hepatoblastoma, other (i.e., blastemal, cholangioblastic), specify

**TREATMENT EFFECT** (Note 8)

- Not identified
- Present

Percentage of tumour necrosis  %

**MARGIN STATUS** (Note 9)

- Cannot be assessed
- No viable tumour at the margin

Distance of tumour from closest margin  mm

Specify closest margin(s), if possible

- Viable tumour present at the margin

Specify margin(s), if possible

**LYMPHOVASCULAR INVASION** (Note 10)

- Indeterminate
- Not identified
- Present

**LYMPH NODE STATUS** (Note 11)

- Cannot be assessed
- No nodes submitted or found

Number of lymph nodes examined

- Not involved
- Involved

Number of involved lymph nodes

- Number cannot be determined

Location of involved lymph nodes, specify

**COEXISTENT PATHOLOGY** (Note 12)

- None identified
- Present, specify

**ANCILLARY STUDIES** (Note 13)

- Not performed
- Performed (select all that apply)

- Beta-catenin immunohistochemistry
- Glypican 3
- INI 1
- Other immunohistochemical stains, specify test(s) and result(s)

- Other, record test(s), methodology and results

Representative blocks for ancillary studies, specify those blocks best representing tumour and/or normal tissue for further study

**HISTOLOGICALLY CONFIRMED DISTANT METASTASES**

(Note 14)

- Not applicable  
 Not identified  
 Present (select all that apply)

- Lung  
 Brain  
 Bone  
 Other, specify site(s)


**PATHOLOGICAL STAGING** (Note 15)**Children's Oncology Group (COG) staging<sup>b</sup>**

- Stage I Tumour completely resected, margins grossly and microscopically negative for tumour
- Stage II Tumour grossly resected with evidence of microscopic residual tumour
- Microscopic residual tumour present at hepatic resection margin
  - Microscopic residual tumour present at extrahepatic resection margin
  - Intraoperative tumour spill
- Stage III Unresectable tumour<sup>c</sup>
- Tumour within explant
  - Macroscopic tumour visible at resection margin(s)
  - Regional lymph node metastasis present

<sup>b</sup> Czauderna P, Lopez-Terrada D, Hiyama E, Häberle B, Malogolowkin MH, Meyers RL. Hepatoblastoma state of the art: pathology, genetics, risk stratification, and chemotherapy. *Curr Opin Pediatr.* 2014 Feb;26(1): 19-28.

<sup>c</sup> Tumours that are considered by the attending surgeon not to be resectable without undue risk to the patient, tumours within explanted livers, partially resected tumours with macroscopic tumour left at margin, or tumours with regional lymph node metastasis (regional lymph nodes include hilar, hepatoduodenal ligament, or caval lymph nodes).

## Definitions

### CORE elements

CORE elements are those which are essential for the clinical management, staging or prognosis of the cancer. These elements will either have evidentiary support at Level III-2 or above (based on prognostic factors in the National Health and Medical Research Council (NHMRC) levels of evidence<sup>1</sup>). In rare circumstances, where level III-2 evidence is not available an element may be made a CORE element where there is unanimous agreement by the Dataset Authoring Committee (DAC). An appropriate staging system e.g., Pathological TNM staging would normally be included as a CORE element.

Non-morphological testing e.g., molecular or immunohistochemical testing is a growing feature of cancer reporting. However, in many parts of the world this type of testing is limited by the available resources. In order to encourage the global adoption of ancillary tests for patient benefit, International Collaboration on Cancer Reporting (ICCR) includes the most relevant ancillary testing in ICCR Datasets as CORE elements, especially when they are necessary for the diagnosis. Where the technical capability does not yet exist, laboratories may consider temporarily using these data elements as NON-CORE items.

The summation of all CORE elements is considered to be the minimum reporting standard for a specific cancer.

### NON-CORE elements

NON-CORE elements are those which are unanimously agreed should be included in the dataset but are not supported by level III-2 evidence. These elements may be clinically important and recommended as good practice but are not yet validated or regularly used in patient management.

Key information other than that which is essential for clinical management, staging or prognosis of the cancer such as macroscopic observations and interpretation, which are fundamental to the histological diagnosis and conclusion e.g., macroscopic tumour details, may be included as either CORE or NON-CORE elements by consensus of the DAC.

 [Back](#)

## Scope

The dataset has been developed for the pathological reporting of resection specimens of paediatric hepatoblastoma, including tumours in the hepatocellular neoplasm not otherwise specified (HCN-NOS) category. It is not applicable to hepatocellular carcinomas (HCC) nor to other primary or metastatic paediatric neoplasms of the liver.

The authors of this dataset can be accessed [here](#).

 [Back](#)

## **Note 1 – Clinical information (Core and Non-core)**

Clinical information can be provided by the clinician, included in the pathology request form, pathology report, or patient medical record.

### **Age (Core)**

Hepatoblastoma occurs most often in infants and young children between six months and four years of age, with a median age of onset of 18 months. Occasionally, cases are diagnosed in neonates, and in less than 10% of cases, hepatoblastomas are diagnosed prenatally.<sup>2</sup>

### **Serum alpha fetoprotein (AFP) level at diagnosis (Core)**

Alpha-fetoprotein (AFP) is elevated in more than 90% of patients with hepatoblastoma and is a useful diagnostic biomarker also used to monitor response to therapy and disease progression, however, elevated serum AFP can be detected in other tumours. Given physiologic high AFP levels at birth and during the first months of life, correct reference values should be used in infants up to two years of age.<sup>3</sup> An AFP level less than 100 nanograms per millilitre (ng/mL) was previously considered an adverse prognostic factor and associated with small cell undifferentiated (SCU) histology. However, a recent Children's Oncology Group (COG) study suggests that once malignant rhabdoid tumours are excluded, SCU histology is not a poor prognostic variable and AFP levels less than 100 ng/mL in patients with SCU histology are rare.<sup>4</sup>

### **Preoperative chemotherapy (Core)**

It would be important to know if the patient has received prior chemotherapy in order to correctly evaluate histological findings in hepatoblastoma specimens.

### **History of prematurity (Non-core)**

There is extensive evidence supporting the association of hepatoblastoma and extreme prematurity,<sup>5,6</sup> with a risk increase by 15- to 40-fold in children with very low birth weight (less than 1,500 grams).<sup>7</sup>

### **Associated genetic syndromes, malformations or other conditions (Non-core)**

Several congenital abnormalities, constitutional genetic syndromes, malformations, and other clinical conditions have been associated with hepatoblastoma.<sup>8</sup> Increased incidence warranting surveillance is seen in patients with Beckwith-Wiedemann syndrome, hemihypertrophy syndromes, Trisomy 18 and other rare syndromes.<sup>5,9</sup> However, the majority of hepatoblastomas appear to be sporadic.

### **PRETEXT clinical staging (Non-core)**

The TNM staging system is not used for hepatoblastoma. In North America, the COG staging system, based on postoperative evaluation, was historically used. Stage I pure fetal hepatoblastoma with complete surgical resection can be cured with excellent long-term survival with surgery alone and without the need for adjuvant chemotherapy.<sup>10</sup> The PRETEXT (PRE-Treatment EXTent of disease) clinical staging system is based on radiological analysis of tumour location, described by involvement of surgical liver segments, and extrahepatic extent and was designed by the International Childhood Liver Tumour Strategy Group (SIOPEL).<sup>11</sup> Based on multiparameter analysis, including PRETEXT, four risk groups have currently been adopted in the ongoing prospective international clinical trial for the risk stratification of children with hepatoblastoma.<sup>12</sup>

### Other clinical information, including low birth weight (Non-core)

Additionally, other non-core items such as low birth weight, or other clinical findings also enhance the completeness of specimen context.

↑ Back

### Note 2 – Operative procedure (Core)

Information regarding the nature of the operative procedure should be provided, with any additional annotation that may be necessary (Figure 1). The various surgical procedures listed include those that attempt primary resection or resection post chemotherapy, and the judicious use of transplant where necessary due to overall improved outcome for conventionally nonresectable cases. Should the operative specimen not be one typically submitted for hepatoblastoma resection/transplantation, this needs to be clearly indicated.

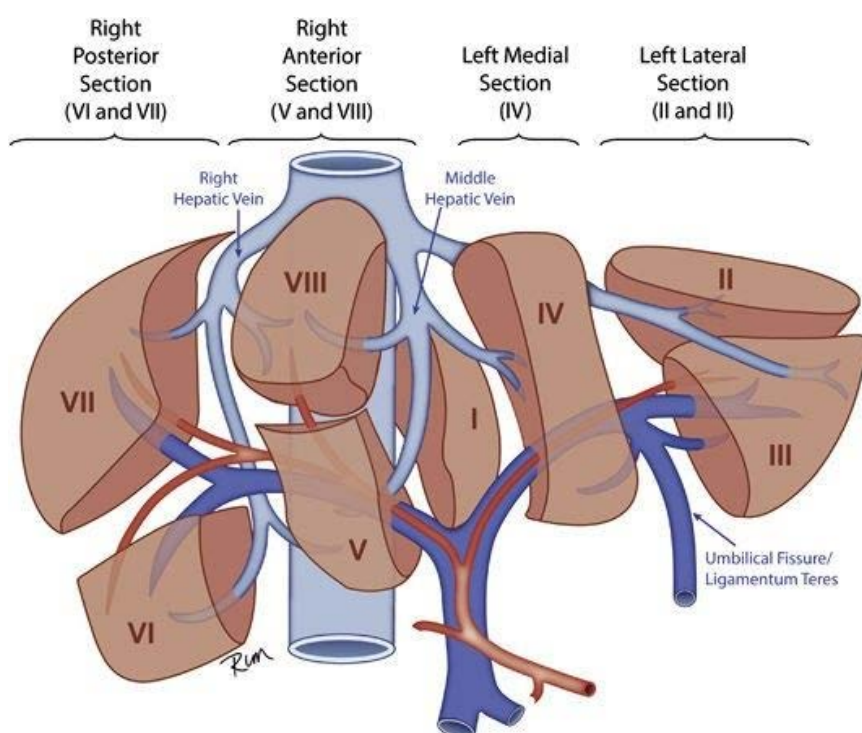


Figure 1: PRETEXT is distinct from Couinaud 8-segment (I–VIII) anatomic division of the liver. PRETEXT defines 4 ‘Sections’. Boundaries of each section defined by the right and middle hepatic veins, and umbilical fissure. This figure was published in *Modern Pathology* (2014), 27, Dolores López-Terrada et al, Towards an international pediatric liver tumor consensus classification: proceedings of the Los Angeles COG liver tumors symposium, pages 472-491, Copyright Elsevier.<sup>13</sup>

↑ Back

### **Note 3 – Tumour site (Core)**

Hepatoblastoma usually presents as a single mass, involving the right lobe (55-60%), the left lobe (15%) or both lobes of the liver.<sup>14</sup> It is important to know the location of the tumour to determine surgical resectability.

**↑ Back**

### **Note 4 – Tumour focality (Core and Non-core)**

Hepatoblastoma is an aggressive embryonal tumour with a historically high mortality of approximately 76% reported in the early 1980s.<sup>15,16</sup> However, recent advances in chemotherapy and the development of new surgical techniques have dramatically improved the prognosis of these children to up to 90% in some regions.<sup>17</sup> Tumour-specific adverse prognostic factors include high stage using the COG surgical or PRETEXT staging systems, certain histologic subtypes, vascular invasion and multifocality.<sup>16,18-20</sup>

It has been shown that multifocal disease is an independent factor associated with worse event free survival and overall survival.<sup>18</sup> For these reason, it has been recommended that the presence of multifocality should be a component of prognostic stratification.<sup>18,20</sup>

**↑ Back**

### **Note 5 – Tumour dimensions (Core and Non-core)**

Hepatoblastoma often presents as a single, large expansive mass compressing the surrounding liver, which is generally architecturally and functionally normal. Occasionally, intrahepatic dissemination via portal veins leads to multiple discrete nodules, but most cases have only contiguous extension. Evaluation of the extent of hepatic involvement and metastases is of most importance in the management of children with hepatoblastoma. The PRETEXT system,<sup>21</sup> developed by the SIOPEL, is currently the primary mode for determining stage and assigning risk categorisation, given its strong prognostic value, as documented by the Children's Hepatic tumours International Collaboration (CHIC) Group in 2017.<sup>12</sup>

**↑ Back**

### **Note 6 – Block identification key (Non-core)**

The origin/designation of all tissue blocks should be recorded. This information should ideally be documented in the final pathology report and is particularly important should the need for internal or external review arise. The reviewer needs to be clear about the origin of each block in order to provide an informed specialist opinion. If this information is not included in the final pathology report, it should be available on the laboratory computer system and relayed to the reviewing pathologist. It may be useful to have a digital image of the specimen and record of the origin of the tumour blocks in some cases.

Recording the origin/designation of tissue blocks also facilitates retrieval of blocks for further immunohistochemical or molecular analysis, research studies or clinical trials.

**↑ Back**

## Note 7 – Histological tumour type (Core)

Histologic diagnosis of paediatric hepatoblastoma is based on the 2023 World Health Organization (WHO) Classification of Paediatric Tumours, 5<sup>th</sup> edition (Table 1).<sup>22</sup>

**Table 1: World Health Organization classification of paediatric liver tumours.**<sup>22</sup>

Descriptor	ICD-O codes <sup>a</sup>
Hepatoblastoma	8970/3
Fibrolamellar variant of hepatocellular carcinoma	8171/3
Paediatric hepatocellular carcinoma	8170/3
Mesenchymal hamartoma	
Calcifying nested stromal-epithelial tumour	8975/1
Embryonal sarcoma of the liver	8991/3
Hepatic congenital haemangioma	9120/0
Hepatic infantile haemangioma	9131/0
Hepatic angiosarcoma	9120/3

<sup>a</sup> These morphology codes are from the International Classification of Diseases for Oncology, third Edition, second revision (ICD-O-3.2).<sup>23</sup> Behaviour is coded /0 for benign tumours; /1 for unspecified, borderline, or uncertain behaviour; /2 for carcinoma in situ and grade III intraepithelial neoplasia; /3 for malignant tumours, primary site; and /6 for malignant tumours, metastatic site.

© World Health Organization/International Agency for Research on Cancer. Reproduced with permission.

### Hepatoblastoma

#### Epithelial patterns: Fetal, mitotically inactive/well-differentiated

This pattern is characterised by uniform-appearing round to polygonal cells with small central nuclei and clear or pale eosinophilic cytoplasm that may give the tumour a light-cell/dark-cell pattern. Nucleoli are usually inconspicuous. It may show interspersed extramedullary hematopoiesis (EMH). A low mitotic rate ( $\leq 2$  mitoses per 10 high power fields (HPF)) is a requisite for this pattern.

The designation of ‘pure fetal hepatoblastoma’ (PFH) is restricted to primary resection specimen only when the entire (100%) tumour is composed of well-differentiated/ mitotically inactive fetal hepatoblastoma pattern with no other epithelial or mesenchymal elements. This is an unusual histologic variant and is the least common amongst the histologic subgroups of hepatoblastoma in its pure form (PFH).

Differentiating this pattern from the uninvolved adjacent liver may be sometimes challenging and may require immunohistochemistry (IHC), particularly in very young patients. Well differentiated fetal (WDF) areas show a 1-2+ fine stippled pericanalicular (cytoplasmic) staining pattern with glypican-3 (GPC3), an oncofetal protein expressed in the normal neonatal/early infant liver, and variable nuclear beta-catenin staining. Glutamine synthetase (GS) is usually diffusely positive in tumour cells, as opposed to a pericentral zonal distribution in the non-tumoral liver. SALL4 is negative in this histologic pattern.

#### Epithelial patterns: Fetal, mitotically active/crowded

This is the most common hepatoblastoma pattern seen in biopsy and resection specimens. Cells are similar those in WDF pattern but generally show more granular cytoplasm and larger nuclei. Mitotic activity is readily identified ( $>2$  mitoses/10 HPF). EMH is frequently encountered. Nuclear beta-catenin staining is



frequently seen in the tumour cells but never diffuse, with variable cytoplasmic staining. GPC3 shows a 2-3+ coarse diffuse cytoplasmic staining pattern. GS also shows diffuse strong staining and SALL4 is negative.

#### Epithelial patterns: Embryonal

This pattern is composed of hyperchromatic cells with high nuclear-to-cytoplasmic ratio, oval to angulated nuclei, sometimes with single nucleoli, and scant cytoplasm. Mitoses are frequent. A subtle or abrupt transition from crowded fetal to embryonal pattern can be seen. Tumour cells may be arranged in rosettes and tubular structures. Nuclear staining for beta-catenin is more diffusely seen than in fetal patterns. GPC3 is typically strongly positive (3+ staining), with the exception of some primitive embryonal components that may be negative for GPC3. GS usually shows variable staining. SALL4 frequently shows strong nuclear positivity.

#### Epithelial patterns: Pleomorphic

This pattern is characterised by pleomorphic tumour cells with variation in nuclear size and shape that may or may not meet criteria for anaplasia as defined by Wilms tumours. Tumour cells may demonstrate giant cell transformation. GPC3 and beta-catenin (nuclear) staining are usually positive in these areas.

#### Epithelial patterns: Macrotrabecular

Unlike the epithelial patterns noted above (i.e., fetal, embryonal, pleomorphic), the macrotrabecular pattern is an architectural pattern, with arrangement of cells in trabeculae five cells thick and greater. The original descriptions of 20-cell-thick plates were problematic and most cases represented HCC, not hepatoblastoma. If most or the entire tumour shows macrotrabecular arrangement, then consideration should be given to HCN-NOS or HCC.

#### Epithelial patterns: Small cell undifferentiated (SCU)

This has been the most controversial cell type in hepatoblastoma, given its initially reported association with adverse prognosis. Earlier studies included a 'pure SCU hepatoblastoma' category which were subsequently found to represent INI1-negative malignant rhabdoid tumours carrying *SMARCB1* mutations or other alterations. Otherwise, foci of SCU in otherwise conventional hepatoblastoma no longer appear to be significant as results of the last COG trial showed no prognostic value to this histologic pattern.<sup>4</sup> Nests of small blue cells with scant mitoses are often identified within areas of embryonal pattern hepatoblastoma. More frequently, nests of cells with similar morphology to SCU are seen in areas of crowded fetal and at the periphery of nodules of hepatoblastoma, and are designated blastemal component. It is possible that the two patterns (SCU and blastemal) are related and portend the same primitive cells in hepatoblastoma capable of multidirectional differentiation. The full significance of these patterns is still to be determined, but should be recognised as primitive components of hepatoblastoma that are not seen in either HCN-NOS or HCC. SCU and blastemal cells show nuclear expression of beta-catenin and co-expression of cytokeratins (keratin cocktails, CK19, CK7) and vimentin.

#### Other epithelial patterns

Other epithelial patterns of hepatoblastoma include squamoid, glandular and biliary-like profiles at the edges of tumour nodules, distinct from the reactive biliary/ductular proliferation seen at the junction with normal liver in post-therapy resection specimens. The biliary profiles of cholangioblastic pattern hepatoblastoma show nuclear beta-catenin staining as opposed to the reactive profiles which show only membranous staining. Cholangioblastic pattern cells are positive for CK19 and keratin cocktails, and less often CK7 expression.

## Mesenchymal hepatoblastoma

The 2014 International Pediatric Liver Tumour Consensus Classification noted this component as part of a mixed epithelial-mesenchymal hepatoblastoma with or without teratoid elements.<sup>13</sup> It is unusual to find a pure mesenchymal hepatoblastoma, except in a rare situation post-treatment when epithelial elements have responded to therapy and only the mesenchymal elements remain (mainly osteoid and bone). Other mesenchymal elements noted include cartilage, mature or immature, muscle or rhabdomyoblastic areas with desmin and myogenin/myoD1 staining, and spindle cell mesenchyme. Nuclear beta-catenin staining may be seen in any of the mesenchymal components. GPC3 and SALL4 are usually negative in mesenchymal components but can highlight epithelial components.

Presence of neural elements such as primitive neuroepithelium, melanin, glial or ganglion cells may all represent features of teratoid differentiation in hepatoblastoma. Other unusual components that may be present in teratoid hepatoblastoma include glandular elements admixed with primitive neuroepithelium with cytoplasmic supranuclear and subnuclear vacuolation in the glandular epithelium resembling yolk sac tumour. These glands are not the same as the occasional intestinal type glands that may be seen in epithelial HB. They seem to occur in the vicinity of immature neuroepithelium, much like those seen in immature teratomas but can be differentiated from the latter by their nuclear beta-catenin expression. These glands are also GPC3 and SALL4 positive. The neuroepithelial elements show variable nuclear staining for beta-catenin and SALL4, and are negative for GPC3. They usually show multilayering when arranged in rosette form, helping to differentiate them from embryonal rosettes.

## Hepatocellular neoplasm not otherwise specified (HCN-NOS)

Hepatocellular neoplasm not otherwise specified (HCN-NOS) are malignant hepatocellular tumours that are difficult to classify. The usual differential diagnosis is hepatoblastoma versus HCC. Nuclear beta-catenin immunoreactivity is present. This provisional entity was created to include lesions previously described as highly aggressive tumours with overlapping features of epithelial hepatoblastoma and HCC,<sup>13</sup> and are currently not classifiable as reported by SIOPEL and COG studies. HCN-NOS occur most frequently in older children presenting with very high AFP levels, and no predisposition to hepatic disease. The 'NOS' nomenclature reflects the necessity to highlight the provisional nature of this category until molecular studies better define their biology.

Hepatoblastoma or well-differentiated HCC type cells in a macrotrabecular or nested pattern, as well as pleomorphic or multinucleated cells may be present in HCN-NOS tumours. Beta-catenin nuclear immunopositivity further supports the biologic relationship of these tumours with hepatoblastoma. Furthermore, recent molecular profiling of a series of HCN-NOS revealed biological features common to both hepatoblastoma and HCC, and showed that tumours exhibiting these features had poor outcomes irrespective of patient age, emphasising the importance of molecular testing and the study of early therapeutic intervention in patients with HCN-NOS tumours.<sup>24</sup>

Hepatocellular neoplasm not otherwise specified (HCN-NOS) are currently treated as hepatoblastoma and not as HCC in the Paediatric Hepatic International Tumour Trial (PHITT).

 **Back**

## **Note 8 – Treatment effect (Non-core)**

The extent of tumour necrosis following neoadjuvant chemotherapy has been reported as an independent prognostic factor in newly diagnosed hepatoblastoma.<sup>25</sup> However, it has not been confirmed in large clinical studies and so this element is considered non-core. Grossly these are well-demarcated areas of congestion/

haemorrhage, calcifications and fibrosis. However, it is difficult to predict whether these areas present necrosis or viable hepatoblastoma components and therefore adequate sampling with a photographic tumour block diagram is useful.

Histological features include coagulative-type necrosis, cystic degenerative changes, a fibrohistiocytic response with haemosiderin-laden and/or foamy macrophages.

Also noted are:

- Focal, so-called peliosis-like changes with densely packed erythrocytes in various stages of degeneration surrounded by a thick fibrous wall showing no endothelial lining.
- Rounded pools of blood within epithelial tumour sinusoids (so-called peliotic-like foci).<sup>19</sup>
- Bands of fibrosis adjacent to viable tumour/necrosis often containing ductular proliferations.
- Increased osteoid formation and/or squamous/keratin formations often eliciting a foreign body-type granulomatous response in mixed hepatoblastoma.

Chemotherapy effect on viable hepatoblastoma cells includes either differentiation into fetal epithelial hepatoblastoma or into pleomorphic/HCC-like features. For all components, immunostaining for beta catenin and glypican 3 is valuable.

 **Back**

## **Note 9 – Margin status (Core)**

Due to the overall rarity of hepatoblastoma, there are only few published studies regarding the predictive value of positive tumour margins or the distance of tumour to various margins in disease recurrence or prognosis, and their conclusions have not been uniform.<sup>26-28</sup> However, it is the consensus opinion of the DAC that tumour involvement of the margin or distance from the margins be considered a core element. It is recommended that the surgeon be consulted to determine critical foci within margins for microscopic evaluation.<sup>29</sup> Grossly positive margins should be confirmed microscopically and documented, with the margin specified, if possible. If the margins are grossly free of tumour, sampling of the margin in the region closest to the nearest identified tumour nodule should be performed and the tumour distance to the margin should be documented, with the margin specified if possible. In cases with multiple nodules, documentation of the location of the tumour nodule(s) and margin status may be important in correlating with imaging findings,<sup>30,31</sup> particularly for those nodules that may not have been radiographically apparent on preoperative imaging.

 **Back**

## **Note 10 – Lymphovascular invasion (Core)**

Macroscopic portal and hepatic venous involvement may have prognostic significance, and therefore should be reported, typically by preoperative imaging.<sup>12,20</sup> Pathologic vascular invasion has been investigated in a limited number of studies. A retrospective study found that patients with invasion identified by microscopic examination were more likely to be older, present with metastatic disease, and have a worse three year overall survival.<sup>32</sup> Another retrospective study reported the presence of either macroscopic or microscopic lymphovascular invasion resulted in a significantly decreased disease-free survival period, when compared to those that did not demonstrate lymphovascular invasion.<sup>33</sup> Other studies support the association between lymphovascular invasion and survival.<sup>34-36</sup> Given the preliminary evidence in the literature that vascular

invasion as a whole may be prognostic in hepatoblastoma, the consensus opinion of the DAC is that macroscopic lymphovascular invasion be reported when identified, and that microscopic intratumoral and extratumoral vascular invasion be recorded at the discretion of the pathologist, but not required to be reported, until further evidence is available.

↑ Back

## Note 11 – Lymph node status (Core)

Lymph node metastases are not common in hepatoblastoma. Regional lymph nodes of the hepatic region include the hilar, hepatoduodenal ligament, and caval lymph nodes, which are likely to be sampled at the time of surgical resection or transplant. Nodal involvement of the inferior phrenic lymph nodes or other lymph nodes distal to the hilar, hepatoduodenal ligament, and caval lymph nodes is considered distant metastasis.<sup>21</sup>

↑ Back

## Note 12 – Coexistent pathology (Non-core)

Hepatoblastoma usually arises in ‘healthy’ livers, therefore, coexistent pathology could be helpful to differentiate hepatoblastoma from HCC, which often occurs in patients with chronic viral hepatitis, congenital metabolic/cholestatic diseases, and other miscellaneous disorders. Tumour mass effect should not be confused with underlying liver disease in hepatoblastoma. Some hepatoblastoma cases, however, may be associated with underlying liver diseases of which clinical impact have not been well evaluated yet.

Although coexistent pathology is considered as a non-core element, the following findings are recommended to be reported, if present:

- Fibrosis: portal/periportal/bridging/cirrhosis
- Inflammation: portal/lobular/interface, mild/moderate/severe
- Steatosis: proportion/type/distribution
- Cholestasis: canalicular/hepatocellular
- Other factors: vascular abnormalities, parenchymal abnormalities such as nodular regenerative hyperplasia, etc.

↑ Back

## Note 13 – Ancillary studies (Core and Non-core)

Beta-catenin IHC for the demonstration of nuclear or nuclear and cytoplasmic translocation in the various epithelial components, especially the embryonal type, is important diagnostically and can be useful for its differential diagnosis. Glypican 3 IHC is also useful for the diagnosis of hepatoblastoma and to confirm hepatocellular differentiation. Finally, INI1 serves to exclude the diagnosis of malignant rhabdoid tumour in hepatoblastomas with small cell undifferentiated areas. For these reasons, the three above-mentioned markers may be critical for the diagnosis of hepatoblastoma and are regarded as core elements.

Resection specimens of hepatoblastoma patients do not usually cause major differential diagnostic problems. However, IHC may be required for diagnosis in several instances, including when the tumour histology of the resection specimen differs from the biopsy post chemotherapy, to highlight viable tumour areas, and to distinguish different tumor components.

Other IHC markers may be considered as optional, such as SALL4, for the detection of immature tumour areas, mostly representing embryonal hepatoblastoma; cytokeratin 19, for highlighting cholangioblastic differentiation; and vimentin, for SCU areas. Molecular studies are currently not considered core elements in the reporting of hepatoblastoma resection specimens as the evidence is still emerging. However, single gene tests, targeted next generation sequencing studies, or other genomic or profiling studies such as SNP arrays, may provide a comprehensive molecular profile, or be diagnostically or prognostically useful for these tumours that are known for their low mutational burden, and for the diagnosis of HCN-NOS or HCC.<sup>37</sup>

**↑ Back**

## **Note 14 – Histologically confirmed distant metastases (Core)**

Documentation of known metastatic disease is an important part of the pathology report. Such information, if available, should be recorded with as much detail as is available, including the site, whether the specimen is a histopathology or cytopathology specimen and with reference to any relevant prior surgical pathology or cytopathology specimens.

If distant sites are sampled and pathologically shown to be negative, metastatic disease is 'not identified', whereas if sampling is not performed, this section is 'not applicable'.

**↑ Back**

## **Note 15 – Pathological staging (Non-core)**

Currently, no pathologic staging system is clinically applicable in hepatoblastoma. Historically, COG pathologic staging was used in the United States which combines data from imaging and pathologic data from surgical resection, which is still useful to pathologists reviewing the specimens.<sup>38</sup> COG pathologic staging has been clinically replaced by the PRETEXT/POSTTEXT staging system, which is strictly based on imaging data.<sup>39</sup>

PRETEXT/POSTTEXT staging uses computed tomography and magnetic resonance imaging exclusively to determine the location and extent of hepatic involvement of hepatoblastoma pre-treatment (PRETEXT) based on the Couinaud's system of segmentation of the liver.<sup>21,39</sup> PRETEXT is based on cross-sectional imaging assessment of the extent of tumour involvement of the four main sections of the liver: right posterior section (Couinaud 6 and 7); right anterior section (Couinaud 5 and 8); left medial section (Couinaud 4a and 4b); and left lateral section (Couinaud 2 and 3). PRETEXT assignment to groups I-IV (PRETEXT I, II, III, or IV) is determined by the number of contiguous uninvolved sections of the liver. Annotation factors are additionally assigned to indicate vascular involvement, nodal involvement, caudate involvement, tumour multifocality, rupture, and metastases.

**↑ Back**

## References

- 1 Merlin T, Weston A and Tooher R (2009). Extending an evidence hierarchy to include topics other than treatment: revising the Australian 'levels of evidence'. *BMC Med Res Methodol* 9:34.
- 2 Sallam A, Paes B and Bourgeois J (2005). Neonatal hepatoblastoma: two cases posing a diagnostic dilemma, with a review of the literature. *Am J Perinatol* 22(8):413-419.
- 3 Blohm ME, Vesterling-Hörner D, Calaminus G and Göbel U (1998). Alpha 1-fetoprotein (AFP) reference values in infants up to 2 years of age. *Pediatr Hematol Oncol* 15(2):135-142.
- 4 Trobaugh-Lotrario A, Katzenstein HM, Ranganathan S, Lopez-Terrada D, Krailo MD, Piao J, Chung N, Randazzo J, Malogolowkin MH, Furman WL, McCarville EB, Towbin AJ, Tiao GM, Dunn SP, Langham MR, McGahren ED, Feusner J, Rodriguez-Galindo C, Meyers RL, O'Neill AF and Finegold MJ (2022). Small Cell Undifferentiated Histology Does Not Adversely Affect Outcome in Hepatoblastoma: A Report From the Children's Oncology Group (COG) AHEP0731 Study Committee. *J Clin Oncol* 40(5):459-467.
- 5 Spector LG and Birch J (2012). The epidemiology of hepatoblastoma. *Pediatr Blood Cancer* 59(5):776-779.
- 6 Heck JE, Meyers TJ, Lombardi C, Park AS, Cockburn M, Reynolds P and Ritz B (2013). Case-control study of birth characteristics and the risk of hepatoblastoma. *Cancer Epidemiol* 37(4):390-395.
- 7 Spector LG, Puumala SE, Carozza SE, Chow EJ, Fox EE, Horel S, Johnson KJ, McLaughlin CC, Reynolds P, Behren JV and Mueller BA (2009). Cancer risk among children with very low birth weights. *Pediatrics* 124(1):96-104.
- 8 Nussbaumer G and Benesch M (2022). Hepatoblastoma in molecularly defined, congenital diseases. *Am J Med Genet A* 188(9):2527-2535.
- 9 Mussa A, Duffy KA, Carli D, Ferrero GB and Kalish JM (2019). Defining an optimal time window to screen for hepatoblastoma in children with Beckwith-Wiedemann syndrome. *Pediatr Blood Cancer* 66(1):e27492.
- 10 Malogolowkin MH, Katzenstein HM, Meyers RL, Krailo MD, Rowland JM, Haas J and Finegold MJ (2011). Complete surgical resection is curative for children with hepatoblastoma with pure fetal histology: a report from the Children's Oncology Group. *J Clin Oncol* 29(24):3301-3306.
- 11 Aronson DC, Schnater JM, Staalman CR, Weverling GJ, Plaschkes J, Perilongo G, Brown J, Phillips A, Otte JB, Czuderna P, MacKinlay G and Vos A (2005). Predictive value of the pretreatment extent of disease system in hepatoblastoma: results from the International Society of Pediatric Oncology Liver Tumor Study Group SIOPEL-1 study. *J Clin Oncol* 23(6):1245-1252.
- 12 Meyers RL, Maibach R, Hiyama E, Häberle B, Krailo M, Rangaswami A, Aronson DC, Malogolowkin MH, Perilongo G, von Schweinitz D, Ansari M, Lopez-Terrada D, Tanaka Y, Alaggio R, Leuschner I, Hishiki T, Schmid I, Watanabe K, Yoshimura K, Feng Y, Rinaldi E, Saraceno D, Derosa M and Czuderna P (2017). Risk-stratified staging in paediatric hepatoblastoma: a unified analysis from the Children's Hepatic tumors International Collaboration. *Lancet Oncol* 18(1):122-131.

- 13 López-Terrada D, Alaggio R, de Dávila MT, Czauderna P, Hiyama E, Katzenstein H, Leuschner I, Malogolowkin M, Meyers R, Ranganathan S, Tanaka Y, Tomlinson G, Fabrè M, Zimmermann A and Finegold MJ (2014). Towards an international pediatric liver tumor consensus classification: proceedings of the Los Angeles COG liver tumors symposium. *Mod Pathol* 27(3):472-491.
- 14 Weinberg AG and Finegold MJ (1983). Primary hepatic tumors of childhood. *Hum Pathol* 14(6):512-537.
- 15 Lack EE, Neave C and Vawter GF (1982). Hepatoblastoma. A clinical and pathologic study of 54 cases. *Am J Surg Pathol* 6(8):693-705.
- 16 Ranganathan S, Lopez-Terrada D and Alaggio R (2020). Hepatoblastoma and Pediatric Hepatocellular Carcinoma: An Update. *Pediatr Dev Pathol* 23(2):79-95.
- 17 Kahla JA, Siegel DA, Dai S, Lupo PJ, Foster JH, Scheurer ME and Heczey AA (2022). Incidence and 5-year survival of children and adolescents with hepatoblastoma in the United States. *Pediatr Blood Cancer* 69(10):e29763.
- 18 Saettini F, Conter V, Provenzi M, Rota M, Giraldi E, Foglia C, Cavalleri L and D'Antiga L (2014). Is multifocality a prognostic factor in childhood hepatoblastoma? *Pediatr Blood Cancer* 61(9):1593-1597.
- 19 Wang LL, Filippi RZ, Zurakowski D, Archibald T, Vargas SO, Voss SD, Shamberger RC, Davies K, Kozakewich H and Perez-Atayde AR (2010). Effects of neoadjuvant chemotherapy on hepatoblastoma: a morphologic and immunohistochemical study. *Am J Surg Pathol* 34(3):287-299.
- 20 Maibach R, Roebuck D, Brugieres L, Capra M, Brock P, Dall'Igna P, Otte JB, De Camargo B, Zsiros J, Zimmermann A, Aronson D, Childs M, Scopinaro M, Morland B, Plaschkes J, Czauderna P and Perilongo G (2012). Prognostic stratification for children with hepatoblastoma: the SIOPEL experience. *Eur J Cancer* 48(10):1543-1549.
- 21 Towbin AJ, Meyers RL, Woodley H, Miyazaki O, Weldon CB, Morland B, Hiyama E, Czauderna P, Roebuck DJ and Tiao GM (2018). 2017 PRETEXT: radiologic staging system for primary hepatic malignancies of childhood revised for the Paediatric Hepatic International Tumour Trial (PHITT). *Pediatr Radiol* 48(4):536-554.
- 22 WHO Classification of Tumours Editorial Board (ed) (2023). *Paediatric Tumours, WHO Classification of Tumours, 5th edition, Volume 7*. IARC Publications, Lyon.
- 23 Fritz A, Percy C, Jack A, Shanmugaratnam K, Sobin L, Parkin DM and Whelan S (eds) (2020). *International Classification of Diseases for Oncology, Third edition, Second revision ICD-O-3.2*. Available from: [http://www.iacr.com.fr/index.php?option=com\\_content&view=category&layout=blog&id=100&Itemid=577](http://www.iacr.com.fr/index.php?option=com_content&view=category&layout=blog&id=100&Itemid=577) (Accessed 16th December 2022).
- 24 Sumazin P, Peters TL, Sarabia SF, Kim HR, Urbicain M, Hollingsworth EF, Alvarez KR, Perez CR, Pozza A, Najaf Panah MJ, Epps JL, Scorsone K, Zorman B, Katzenstein H, O'Neill AF, Meyers R, Tiao G, Geller J, Ranganathan S, Rangaswami AA, Woodfield SE, Goss JA, Vasudevan SA, Heczey A, Roy A, Fisher KE, Alaggio R, Patel KR, Finegold MJ and López-Terrada DH (2022). Hepatoblastomas with carcinoma features represent a biological spectrum of aggressive neoplasms in children and young adults. *J Hepatol* 77(4):1026-1037.

- 25 Venkatramani R, Wang L, Malvar J, Dias D, Sposto R, Malogolowkin MH and Mascarenhas L (2012). Tumor necrosis predicts survival following neo-adjuvant chemotherapy for hepatoblastoma. *Pediatr Blood Cancer* 59(3):493-498.
- 26 Aronson DC, Weeda VB, Maibach R, Czauderna P, Dall'Igna P, de Ville de Goyet J, Branchereau S, Perilongo G, Brock P, Zsiros J, Semeraro M, Chardot C, Wildhaber B, Morland B and Brugières L (2019). Microscopically positive resection margin after hepatoblastoma resection: what is the impact on prognosis? A Childhood Liver Tumours Strategy Group (SIOPEL) report. *Eur J Cancer* 106:126-132.
- 27 Younes A, Elgendy A, Fadel S, Romeih M, Elwakeel M, Salama A, Azer M and Ahmed G (2021). Surgical Resection of Hepatoblastoma: Factors Affecting Local Recurrence. *Eur J Pediatr Surg* 31(5):432-438.
- 28 Ren X, Li H, Diao M, Chen L, Xu H and Li L (2019). Results of surgical resections with positive margins for children with hepatoblastoma: Case series from a single Asian center. *Pediatr Blood Cancer* 66(1):e27479.
- 29 Ren X, Li H, Diao M, Xu H and Li L (2020). Impact of microscopically margin-positive resection on survival in children with hepatoblastoma after hepatectomy: a retrospective cohort study. *Int J Clin Oncol* 25(4):765-773.
- 30 Fonseca A, Gupta A, Shaikh F, Ramphal R, Ng V, McGilvray I and Gerstle JT (2018). Extreme hepatic resections for the treatment of advanced hepatoblastoma: Are planned close margins an acceptable approach? *Pediatr Blood Cancer* 65(2).
- 31 Dicken BJ, Bigam DL and Lees GM (2004). Association between surgical margins and long-term outcome in advanced hepatoblastoma. *J Pediatr Surg* 39(5):721-725.
- 32 Shi Y, Commander SJ, Masand PM, Heczey A, Goss JA and Vasudevan SA (2017). Vascular invasion is a prognostic indicator in hepatoblastoma. *J Pediatr Surg* 52(6):956-961.
- 33 von Schweinitz D, Hecker H, Schmidt-von-Arndt G and Harms D (1997). Prognostic factors and staging systems in childhood hepatoblastoma. *Int J Cancer* 74(6):593-599.
- 34 Fuchs J, Rydzynski J, Von Schweinitz D, Bode U, Hecker H, Weinel P, Bürger D, Harms D, Erttmann R, Oldhafer K and Mildenerger H (2002). Pretreatment prognostic factors and treatment results in children with hepatoblastoma: a report from the German Cooperative Pediatric Liver Tumor Study HB 94. *Cancer* 95(1):172-182.
- 35 Whitlock RS, Patel KR, Yang T, Nguyen HN, Masand P and Vasudevan SA (2022). Pathologic correlation with near infrared-indocyanine green guided surgery for pediatric liver cancer. *J Pediatr Surg* 57(4):700-710.
- 36 Li J, Li H, Wu H, Niu H, Li H, Pan J, Yang J, Tan T, Hu C, Xu T, Zhang X, Zheng M, Li K, Zou Y and Yang T (2020). Outcomes of children with hepatoblastoma who underwent liver resection at a tertiary hospital in China: a retrospective analysis. *BMC Pediatr* 20(1):200.
- 37 Lee H, El Jabbour T, Ainechi S, Gay LM, Elvin JA, Vergilio JA, Suh J, Ramkissoon SH, Ali SM, Schrock A, Fabrizio D, Frampton G, Nazeer T, Miller VA, Stephens PJ and Ross JS (2017). General paucity of genomic alteration and low tumor mutation burden in refractory and metastatic hepatoblastoma: comprehensive genomic profiling study. *Hum Pathol* 70:84-91.



- 38 Czauderna P, Lopez-Terrada D, Hiyama E, Häberle B, Malogolowkin MH and Meyers RL (2014). Hepatoblastoma state of the art: pathology, genetics, risk stratification, and chemotherapy. *Curr Opin Pediatr* 26(1):19-28.
- 39 University of Birmingham (2022). *Paediatric Hepatic International Tumour Trial (PHITT)*. Available from: <https://clinicaltrials.gov/ct2/show/NCT03017326> (Accessed 8th November 2022).