

Family/Last name

Date of birth

Given name(s)

Patient identifiers

Date of request

Accession/Laboratory number

Elements in **black text** are **CORE**. Elements in **grey text** are **NON-CORE**.

indicates multi-select values indicates single select values

SCOPE OF THIS DATASET

CLINICAL INFORMATION (Note 1)

Information not provided

Imaging evidence of lung mass

Information not provided

Not identified

Present, *describe*

Clinical or imaging evidence of advanced disease

Information not provided

Not identified

Present, *describe*

Other clinical information, specify

SPECIMEN TYPE (select all that apply) (Note 2)

Small biopsy specimens

Bronchoscopic forceps biopsy

Number of biopsies

Core needle biopsy

Gauge of needle

Number of cores

Cryobiopsy

Number of biopsies

Surgical biopsy (e.g., supraclavicular nodal metastasis, pathological bone fracture, a brain metastasis)

Other, *specify*

Cytopathology specimens

Sputum

Bronchial brushings

Bronchial washings

Bronchoalveolar lavage (BAL)

Fine needle aspiration biopsy (FNAB) (Percutaneous)

FNAB (Endoscopic)

Transbronchial

Approach not specified

Transesophageal

Pleural fluid

Pericardial fluid

Imprints of biopsy specimens

Other, *specify*

SITE(S) OF SAMPLING (select all that apply) (Note 3)

Lung

Left

Upper lobe

Lower lobe

Other (e.g., hilar mass),
specify

Right

Upper lobe

Middle lobe

Lower lobe

Other, *specify*

Extrapulmonary sites

Other site 1, *specify*

Other site 2, *specify*

Nodal sites^a

10 Hilar

11 Interlobar

12 Lobar

7 Subcarinal

Other, *specify*

2L Upper Paratracheal (left)

2R Upper Paratracheal (right)

4L Lower Paratracheal (left)

4R Lower Paratracheal (right)

^a Nodes accessible via EBUS.

ROSE (Note 4)

(Applicable to cytopathology specimens only)

Not performed

Performed

Performed via telecytopathology

Type (select all that apply)

FNAB

Other (e.g., imprint of core needle biopsy), specify

	Name of site assessed	Number of passes	Number of slides	Type of stain used	Adequate/ Inadequate	Provisional diagnosis by cytopathologist (verbatim)	Core biopsy taken at this site
Site 1							
Site 2							
Site 3							
Site 4							
Site 5							
Site 6							

Contact details of proceduralist

Site, specify

DESCRIPTION AND DISTRIBUTION OF SAMPLED MATERIAL (Note 5)

Fluid (if applicable)

COLLECTION MEDIA

- None (specimen only) RPMI
 Saline Formalin
 Liquid based cytopathology, specify type

Other, specify

Volume mL

Description of fluid (e.g., colour, presence of blood, viscosity, presence of particulate matter), specify

Slides made from fluid received in laboratory

Number of air-dried slides

Number of alcohol-fixed slides

Direct smears submitted to laboratory

Number of air-dried slides

Number of alcohol-fixed slides

Distribution (select all that apply)

- Flow cytometry
 Molecular
 Cell block, specify identifier
 Core biopsy, specify identifier and block number
 Other (e.g., microbiology and tissue bank), specify

CATEGORY (Note 6)

(Applicable to cytopathology specimens only)
(Values based on the World Health Organization (WHO) Reporting System for Lung Cytopathology (2022))

- Inadequate/Insufficient/Non diagnostic
 Benign
 Normal lymphocytes
 Adequate number Inadequate number
 Atypical, explain reasons for this category and which malignancies are considered in the differential diagnosis
 Suspicious for malignancy, explain reasons for this category and which malignancies are considered in the differential diagnosis

Complete for 2nd specimen if applicable.
If more specimens have been submitted print additional pages.

Site, specify

DESCRIPTION AND DISTRIBUTION OF SAMPLED MATERIAL (Note 5)

Fluid (if applicable)

COLLECTION MEDIA

- None (specimen only) RPMI
 Saline Formalin
 Liquid based cytopathology, specify type

Other, specify

Volume mL

Description of fluid (e.g., colour, presence of blood, viscosity, presence of particulate matter), specify

Slides made from fluid received in laboratory

Number of air-dried slides

Number of alcohol-fixed slides

Direct smears submitted to laboratory

Number of air-dried slides

Number of alcohol-fixed slides

Distribution (select all that apply)

- Flow cytometry
 Molecular
 Cell block, specify identifier
 Core biopsy, specify identifier and block number
 Other (e.g., microbiology and tissue bank), specify

CATEGORY (Note 6)

(Applicable to cytopathology specimens only)
(Values based on the World Health Organization (WHO) Reporting System for Lung Cytopathology (2022))

- Inadequate/Insufficient/Non diagnostic
 Benign
 Normal lymphocytes
 Adequate number Inadequate number
 Atypical, explain reasons for this category and which malignancies are considered in the differential diagnosis
 Suspicious for malignancy, explain reasons for this category and which malignancies are considered in the differential diagnosis

TUMOUR TYPE (Note 7)

(Applicable to all histopathology specimens and those cytopathology specimens categorised as Malignant)
(Values based on the WHO Reporting System for Lung Cytopathology (2022))

- Squamous cell carcinoma
- Adenocarcinoma, list patterns if possible
- Adenocarcinoma with pure lepidic pattern (an invasive component cannot be excluded)
- Invasive mucinous adenocarcinoma, list patterns if possible
- Mucinous adenocarcinoma with pure lepidic pattern (an invasive component cannot be excluded)
- Adenocarcinoma with colloid features
- Adenocarcinoma with fetal features
- Adenocarcinoma with enteric features
- Non-small cell carcinoma, favour squamous cell carcinoma
- Non-small cell carcinoma, favour adenocarcinoma
- Non-small cell carcinoma NOS
- Morphological squamous cell and adenocarcinoma patterns both present: non-small cell carcinoma NOS. (Refer to the results of Immunohistochemistry (IHC). Note: as adenocarcinoma and squamous components are both present, this could represent adenosquamous carcinoma, but that diagnosis requires a resection specimen)
- Morphological squamous cell or adenocarcinoma patterns not present, but immunohistochemical stains favour separate squamous and adenocarcinoma components: non-small cell carcinoma NOS. (Refer to the results of IHC stains. Note: this could represent adenosquamous carcinoma, but that diagnosis requires a resection specimen)
- Non-small cell carcinoma with spindle cell and/or giant cell carcinoma
 - Adenocarcinoma or squamous carcinoma present (Note: this could represent a pleomorphic carcinoma, but that diagnosis requires a resection specimen)
 - Adenocarcinoma and squamous carcinoma absent
- Carcinoid tumour (neuroendocrine tumour)
- Small cell carcinoma
- Non-small cell carcinoma with neuroendocrine morphology and positive neuroendocrine markers, possible large cell neuroendocrine carcinoma
- Neoplasm, specific diagnosis not possible, explain

REPRESENTATIVE MATERIAL FOR ANCILLARY STUDIES

(Note 8)

Core needle biopsy block number and in cytopathology cases the direct smear number, cell block identifier or other identifier (e.g., liquid based cytology (LBC)), specify



Specimen type used, specify

Cellularity

- Very low (<100)
- Low (100-2,000)
- Intermediate (>2,000-5,000)
- High (>5,000)

OR describe

Tumour fraction %

Necrosis %

ANCILLARY STUDIES

Diagnostic immunohistochemical/immunocytochemical markers (Note 9)

(Applicable to cell block and/or core needle biopsy, or smears/cytospins)

- Not performed
- Pending
- Performed

Material used for testing

- Cell block
- Direct smear or cytospin
- Small biopsy
- Other, specify

Results

Positive antibodies	
Negative antibodies	
Equivocal antibodies	

ANCILLARY STUDIES continued

Molecular data (Note 10)

- Not performed
- Pending
- Performed

- ▼ Material used for testing
- Cell block
 - Direct smear
 - Core needle biopsy
 - Other, *specify*

TEST PERFORMED (select all that apply)

EGFR result

- Indeterminate
- Variant not identified
- Variant present, *specify*

ALK result

- Indeterminate
- IHC negative
- IHC positive
- Variant not identified
- Variant present, *specify*

ROS1 result

- Indeterminate
- Variant not identified
- Variant present, *specify*

RET result

- Indeterminate
- Variant not identified
- Variant present, *specify*

NTRK result

- Indeterminate
- Variant not identified
- Variant present, *specify*

BRAF result

- Indeterminate
- Variant not identified
- Variant present, *specify*

KRAS result

- Indeterminate
- Variant not identified
- Variant present, *specify*

MET Exon 14 skipping

- Indeterminate
- Variant not identified
- Variant present, *specify*

MET Amplification result

- Indeterminate
- Variant not identified
- Variant present, *specify*

HER2 Mutation result

- Indeterminate
- Variant not identified
- Variant present, *specify*

Immuno-oncological data

PD-L1 result

- Indeterminate

Percentage tumour cells positive %

Antibody clone used

Other, record test(s), methodology and results

Definitions

CORE elements

CORE elements are those which are essential for the clinical management, staging or prognosis of the cancer. These elements will either have evidentiary support at Level III-2 or above (based on prognostic factors in the National Health and Medical Research Council (NHMRC) levels of evidence¹). In rare circumstances, where level III-2 evidence is not available an element may be made a CORE element where there is unanimous agreement by the Dataset Authoring Committee (DAC).

Non-morphological testing e.g., molecular or immunohistochemical analysis is a growing feature of cancer reporting. However, in many parts of the world this type of testing is limited by the available resources. In order to encourage the global adoption of ancillary tests for patient benefit, International Collaboration on Cancer Reporting (ICCR) recommends that some ancillary testing in ICCR Datasets be included as CORE elements. Where the technical capability does not yet exist, laboratories may consider temporarily using these data elements as NON-CORE items.

The summation of all CORE elements is the recommended minimum reporting standard for a specific cancer.

NON-CORE elements

NON-CORE elements are those which are unanimously agreed should be included in the dataset but are not supported by level III-2 evidence. These elements may be clinically important and recommended as good practice but are not yet validated or regularly used in patient management.

Key information other than that which is essential for clinical management, staging or prognosis of the cancer such as macroscopic observations and interpretation, which are fundamental to the histological diagnosis and conclusion e.g., macroscopic tumour details, may be included as either CORE or NON-CORE elements by consensus of the DAC.

↑ Back

Scope

The dataset has been developed for small diagnostic biopsy specimens and cytopathological specimens of lung cancer. It can also be used for benign tumours or other non-neoplastic specimens at the discretion of the cytopathologist/pathologist. In these cases, the 'Other' responses will be used in many situations and not all elements will be applicable. This flexibility of usage allows for a laboratory to use the one data set report for all lung biopsy specimens, whether or not the final report is one of cancer or a benign tumour or inflammatory process.

The dataset is constructed to include all information that is required for an ideal final report. However, it can be used for provisional reports that are issued before all testing is completed, so as to meet clinical and client needs prior to the issuing of a final all-encompassing report. Again, this flexibility allows for the one dataset to be used for all lung specimens, and unused sections can simply be deleted or preferably annotated as 'results to follow'. It also includes a section for documentation of results from molecular analyses, when undertaken.

The dataset is also applicable to biopsy or excision specimens of metastatic lesions from a primary lung cancer, e.g., a brain metastasis resection or pathological fracture that may be the initial and possibly only diagnostic material from a patient.

Surgical resections of primary lung carcinomas are covered in the ICCR Lung Cancer Dataset.²

Mesothelioma is excluded from the scope of this dataset – refer to the ICCR Mesothelioma in the pleura and peritoneum dataset.³

Details of synchronous primary tumours should be reported in separate datasets.

This dataset aligns with the 2021 World Health Organization (WHO) Classification of Thoracic Tumours, 5th edition,⁴ and to the 2022 WHO System for Reporting Lung Cytopathology, 1st edition.⁵

This dataset is a collaboration between ICCR and the International Association of Cytology (IAC).

↑ Back

Note 1 – Clinical Information (Non-core)

Clinical and imaging information should ideally be provided with the specimen for correlation with findings in small biopsies, both cytopathology and core needle biopsy (CNB), to achieve the optimal diagnosis. If a mass is present on clinical or imaging evidence, further details should be recorded wherever possible, such as whether it is a ground glass opacity, or a solid or sub-solid mass, or a cavitating lesion. This information is important for later pathological correlation.

If there is clinical or imaging evidence of advanced disease, such as, regional lymphadenopathy, a pleural effusion or distant metastases, this should be described.

↑ Back

Note 2 – Specimen type (Core and Non-core)

More than one specimen type is commonly taken in the investigation of suspected lung cancer; all specimens should be documented in the report. For cytopathology samples, it is recommended to make a cell block to ensure that tumour is preserved to facilitate immunohistochemistry (IHC) and molecular testing, where possible. Fine needle aspiration biopsy (FNAB) is defined as a biopsy taken with a needle that is 22 gauge or finer. However, with this understanding, it is not essential to record the gauge of FNAB and CNB in lung biopsies.

For primary and metastatic sites, core biopsies or cytopathology samples such as FNAB, may be used for diagnostic purposes. While most biopsies are not surgical, incisional or excisional surgical biopsy may be undertaken for diagnostic and/or therapeutic purposes, usually from a metastatic site.

For all specimens, the type and extent of fixation should be closely controlled, in order to ensure that samples remain optimal for molecular analysis.

↑ Back

Note 3 – Sites of sampling (Core)

The site(s) of the primary lung cancer should be documented if known (Figure 1). On rare occasions, tumours are either sufficiently diffuse or mediastinal at presentation that primary site or laterality cannot be ascertained, in which case ‘not known’ should be specified under ‘Other’.

Knowledge of the specific nodal stations sampled and involved is important for treatment planning, and should be stated on the request form, labelled slides and specimen containers, and listed in this dataset.

Multiple thoracic nodal stations may be sampled in an effort to clinically stage a patient’s cancer during a single procedure. For example, transbronchial CNB and transbronchial fine needle aspiration biopsy (TBFNAB), most commonly using ultrasound direction of N1 and N2 nodes, may be performed and at the same procedure the tumour itself may be sampled. Each biopsy site should be documented and treated as a separate specimen.

When there are samples from multiple biopsy sites that contain tumour, these should be triaged in relation to optimising the use of tissue for any immunohistochemical/immunocytochemical staining and molecular testing.

If there are both cytopathology and histopathology specimens from the same patient and especially if they are from the same site they should ideally be reported by the same pathologist, or, if different pathologists, the pathologists should consult each other to ensure concordant diagnoses, to cross reference between case numbers and to optimize tissue selection for ancillary testing.

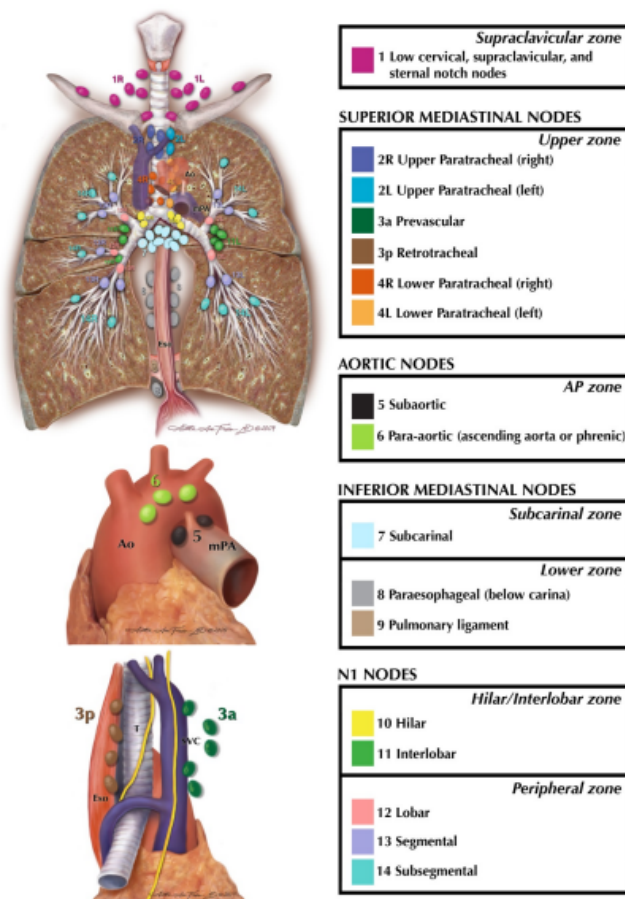


Figure 1: Lymph node map.

Reproduced with permission from Rusch V et al. (2009). The IASLC lung cancer staging project: a proposal for a new international lymph node map in the forthcoming seventh edition of the TNM classification for lung cancer. *J Thorac Oncol* 4(5): 568-577.

↑ Back

Note 4 – ROSE (Core and Non-core)

Rapid onsite evaluation (ROSE) may be used in some settings particularly transthoracic FNAB and endoscopic ultrasound directed FNAB, and if so the name of the proceduralist and their contact details should be recorded, along with the details of the cytopathologist or cyto-scientist/technologist providing the ROSE.

The location or name of each site must be recorded along with the number of passes at that site, the adequacy of material, the number of slides and type of stain used, such as the more common air-dried Giemsa or less common alcohol-fixed rapid haematoxylin-eosin (H&E), Papanicolaou or other. If a cytopathologist is present, then the verbatim provisional diagnosis based on ROSE should also be recorded.

For cyto-scientists/technologists this is generally restricted to making an adequate versus inadequate assessment at each site, rather than a provisional diagnosis.

In addition to classical ROSE which implies that the cytopathologist or a cyto-scientist/technologist is actually in or close to the bronchoscopy suite, telecytopathology may be used for rapid evaluation with the cytopathologist staying in their office and interpreting live video transmitted images or digitally scanned slides ('rapid on-line evaluation' (ROLE)) prepared by a cyto-scientist/technologist or a well-trained clinician on site.⁶

 **Back**

Note 5 – Description and distribution of sampled material (Core)

Fine needle aspiration biopsy (FNAB) and bronchial brush procedures usually yield direct smears, and in FNAB these may undergo rapid onsite evaluation (ROSE) (see **Note 4 ROSE**). The number of air-dried and alcohol-fixed slides should be recorded.

Fluid is routinely collected at bronchial wash, bronchoalveolar lavage and at FNAB where it may represent the whole specimen if a suppurative or necrotic fluid has been aspirated or it may represent the rinsing of the needles and syringes. The fluid type, volume and macroscopic description should be recorded. This includes the type of the liquid based cytopathology (LBC) medium if this is used, as this may impact on next generation sequencing (NGS) studies. Frequently, direct smears or cytospin or LBC slides are prepared from the fluid, and these should be recorded.

The origin/designation of all tissue blocks and cytopathology cell blocks must be recorded. Recording the origin/designation of tissue blocks, cytopathology cell blocks or cytopathological smears facilitates retrieval of blocks and slides for further immunohistochemical or molecular analysis, research studies or clinical trials.

Distribution of the material may occur at ROSE where the material is triaged based on the findings, or in the laboratory immediately the material arrives and can be assessed. The most common FNAB distribution will include using the needle rinsings for flow cytometry if indicated by the presence of only lymphoid material at ROSE, and for preparation of a cell block which is highly recommended in almost every procedure as a source of material for histopathological assessment as well as for IHC or molecular studies in selected cases. At ROSE or if clinical and imaging findings suggest an infectious aetiology, material can be put aside for microbiological testing, and this can be recorded under 'Other'.

 **Back**

Note 6 – Category (Core)

Cytopathology specimens should be categorised as ‘Inadequate/insufficient/non-diagnostic’, ‘Benign’, ‘Atypical’, ‘Suspicious for malignancy’ or ‘Malignant’.³ These categories are defined in the WHO System for Reporting Lung Cytopathology (2022).⁵ If the categories ‘Atypical’ or ‘Suspicious for malignancy’ are used further information detailing why the material is ‘Atypical’ or ‘Suspicious for malignancy’ should be recorded and which specific malignancies are considered in the differential diagnosis. If a lymph node specimen is ‘Benign’, it should be indicated whether or not normal lymphocytes are present to indicate an adequate lymph node sample.

↑ Back

Note 7 – Tumour type (Core)

Tumour type should be recorded for all histopathology specimens and all those cytopathology specimens categorised as Malignant. These should be typed according to the 2021 WHO Classification of Thoracic Tumours⁴ (refer to Tables 1 - 3). Accurate typing of lung carcinoma is important, as histopathology impacts on decisions to proceed with molecular testing (see **Note 10 Molecular data**) and on the most appropriate treatment regimen for patients. A designation of ‘non-small cell carcinoma, not otherwise specified (NSCC, NOS)’, is only acceptable in non-small cell carcinoma (NSCC) specimens that lack morphological evidence of squamous, glandular or neuroendocrine differentiation and that are TTF1 (or Napsin A) and p40 (or CK5/6) negative.^{7,8} While it is beyond the scope of this document to provide a detailed discussion of the pathological features of various histopathological types of lung carcinoma, in poorly differentiated or undifferentiated carcinomas IHC (or a mucin stain for solid pattern adenocarcinoma) can greatly aid in classification and is required, if available, for the diagnosis of non-keratinising squamous cell carcinoma or solid pattern adenocarcinoma.⁴

Precise tumour classification may be hampered by scant viable cells and/or poor tumour differentiation. A multidisciplinary strategy may be required to obtain more informative material for diagnosis and molecular and biomarker testing. If a diagnosis of a specific neoplasm is not possible, further details such as a differential diagnosis should be added to the report, for example, the differential diagnosis of a spindle cell malignancy includes sarcoma, melanoma and sarcomatoid carcinoma. In small biopsy work, both FNAB with cell block and CNB, the range of diagnoses that can be made is limited by the sampling method and amount of material. CNB may give more architectural information. Wherever possible, a specific diagnosis should be given or a differential diagnosis provided.

For cytopathology specimens categorised as ‘Suspicious for malignancy’, the report should describe the features that are regarded as suspicious and provide a differential diagnosis of the suspected malignancy.⁵

Small biopsies and FNAB are sampling techniques and particularly in FNAB may not demonstrate the architectural pattern of a tumour. Classification and subclassification of cancers are possible in many cases by integrating the histopathology, cytopathology and cell block findings with IHC, but the subclassification into adenocarcinoma subtypes may not be possible and requires an intact and good quality small biopsy or excision. In some cases where good FNAB smears are available with or without cell block material, lepidic, papillary, micropapillary or solid subtypes can be described and mentioned as a component of the tumour.⁵

Table 1: Terminology in small biopsy and cytopathology versus resection specimens for adenocarcinoma and squamous cell carcinoma (WHO Classification).³

Morphology/stains	Terminology for small biopsies and cytopathology specimens	Terminology for resection specimens
Morphological squamous cell patterns clearly present	Squamous cell carcinoma	Squamous cell carcinoma
Morphological adenocarcinoma patterns clearly present	Adenocarcinoma (list the patterns in the diagnosis) <ul style="list-style-type: none"> • Lepidic • Acinar • Papillary • Solid • Micropapillary • Other (complex glandular pattern) 	Adenocarcinoma Predominant pattern: <ul style="list-style-type: none"> • Lepidic • Acinar • Papillary • Solid • Micropapillary • Other (complex glandular pattern)
	Adenocarcinoma with lepidic pattern (if pure, list the differential diagnosis per column on the right and add a comment that an invasive component cannot be excluded)	Minimally invasive adenocarcinoma, adenocarcinoma in situ, or an invasive adenocarcinoma with a lepidic component
	Invasive mucinous adenocarcinoma (list the patterns; use the term 'mucinous adenocarcinoma with lepidic pattern' if pure lepidic pattern and mention the differential diagnosis listed in the column on the right)	Invasive mucinous adenocarcinoma
		Minimally invasive adenocarcinoma or adenocarcinoma in situ, mucinous type
	Adenocarcinoma with colloid features	Colloid adenocarcinoma
	Adenocarcinoma with fetal features	Fetal adenocarcinoma
	Adenocarcinoma with enteric features ^a	Enteric adenocarcinoma
Morphological squamous cell patterns not present, but supported by stains (i.e., p40+)	Non-small cell carcinoma, favour squamous cell carcinoma ^b	Squamous cell carcinoma (non-keratinizing pattern may be a component of the tumour) ^b
Morphological adenocarcinoma patterns not present, but supported by special stains (i.e., TTF1+)	Non-small cell carcinoma, favour adenocarcinoma ^b	Adenocarcinoma (solid pattern may be just one component of the tumour) ^b

No clear adenocarcinoma, squamous, or neuroendocrine morphology or staining pattern	Non-small cell carcinoma NOS ^{a,c}	Large cell carcinoma
-------------------------------------------------------------------------------------	---------------------------------------------	----------------------

^a Metastatic carcinomas should be carefully excluded with clinical and appropriate but judicious immunohistochemical examination.

^b The categories do not always correspond to solid-predominant adenocarcinoma or non-keratinizing squamous cell carcinoma, respectively. Poorly differentiated components in adenocarcinoma or squamous cell carcinoma may be sampled.

^c The non-small cell carcinoma NOS pattern can be seen not only in large cell carcinomas but also when the solid, poorly differentiated component of adenocarcinomas or squamous cell carcinomas is sampled but does not express immunohistochemical markers or mucin.

© World Health Organization/International Agency for Research on Cancer. Reproduced with permission.

Table 2: Terminology for small biopsies and cytopathology versus resection specimens for small cell carcinoma, large cell neuroendocrine carcinoma, adenosquamous carcinoma and pleomorphic carcinoma.

Terminology for small biopsies and cytology specimens	Terminology for resection specimens
Small cell carcinoma	Small cell carcinoma
Non-small cell carcinoma with neuroendocrine morphology and positive neuroendocrine markers, possible large cell neuroendocrine carcinoma	Large cell neuroendocrine carcinoma
Morphological squamous cell and adenocarcinoma patterns both present: non-small cell carcinoma NOS Comment that adenocarcinoma and squamous components are present, and that this could represent adenosquamous carcinoma	Adenosquamous carcinoma (if both components ≥10%)
Morphological squamous cell or adenocarcinoma patterns not present, but immunohistochemical stains favour separate squamous and adenocarcinoma components: non-small cell carcinoma NOS Specify the results of the immunohistochemical stains and the interpretation, and comment that this could represent adenosquamous carcinoma, but that diagnosis requires a resection specimen	Adenocarcinoma, squamous cell carcinoma, adenosquamous carcinoma, or large cell carcinoma with unclear immunohistochemical features
Non-small cell carcinoma with spindle cell and/or giant cell carcinoma Mention if adenocarcinoma or squamous carcinoma is present. Comment that this could represent a pleomorphic carcinoma; however, that diagnosis requires a resection specimen.	Pleomorphic, spindle cell and/or giant cell carcinoma

© World Health Organization/International Agency for Research on Cancer. Reproduced with permission.

Table 3: Guidelines for good practice of small biopsies and cytological preparations.

Guidelines for good practice of small biopsies and cytological preparations are as follows:

1. For small biopsies and cytopathology, non-small cell carcinoma should be further classified into a more specific type, such as adenocarcinoma or squamous cell carcinoma, whenever possible.
2. The term 'non-small cell lung carcinoma not otherwise specified (NOS)' should be used infrequently, and only when a more specific diagnosis is not possible.
3. When a diagnosis is made in a small biopsy or cytopathology specimen in conjunction with special studies, it should be clarified whether the diagnosis was established on the basis of light microscopy including mucin stains alone or whether immunohistochemistry (IHC) was diagnostic.
4. The term 'non-squamous cell carcinoma' should not be used by pathologists in diagnostic reports.
5. The classification of adenocarcinoma versus other histopathologies and the terminology in Tables 1 and 2 should be used in routine diagnosis, future research and clinical trials, to ensure a uniform classification of disease cohorts in relation to tumour subtypes, stratified according to diagnoses made by light microscopy alone versus diagnoses requiring IHC.
6. When paired cytopathology and biopsy specimens exist, they should be reviewed together to achieve the most specific and concordant diagnosis.
7. The terms 'adenocarcinoma in situ' and 'minimally invasive adenocarcinoma' should not be used for diagnosis of small biopsies or cytopathology specimens. If a non-invasive pattern is present in a small biopsy, it should be referred to as a lepidic growth pattern. Similarly, if a cytopathology specimen has the attributes of adenocarcinoma in situ, the tumour should be diagnosed as an adenocarcinoma, possibly with a comment that this may represent, at least in part, adenocarcinoma in situ with a lepidic growth pattern.
8. The term 'large cell carcinoma' should not be used for diagnosis in small biopsy or cytopathology specimens and should be restricted to resection specimens where the tumour is thoroughly sampled to exclude a differentiated component.
9. Tumour biopsies that show sarcomatoid features, such as, marked nuclear pleomorphism, malignant giant cells or spindle cell morphology, should be initially classified as above in relation to adenocarcinoma; non-small cell carcinoma, favour adenocarcinoma; squamous cell carcinoma; or non-small cell carcinoma, favour squamous cell carcinoma. This diagnosis may influence management. An additional statement can be made that giant and/or spindle cell features are present. If such features are not present, the term 'non-small cell carcinoma NOS' should be used, again with a comment on the sarcomatoid features.
10. Staining for neuroendocrine immunohistochemical markers should be performed only in cases where there is suspected neuroendocrine morphology.

© World Health Organization/International Agency for Research on Cancer. Reproduced with permission.

↑ Back

Note 8 – Representative material for ancillary studies (Non-core)

In all small biopsies and FNAB record which CNB or FNAB cell block, smear or other preparation contains suitable material for IHC or molecular testing, and to provide a statement as to which would be best utilised for each test.

An indication of tumour content of the sampled material should be recorded. Local guidelines by the molecular pathologist on thresholds of cellularity for further testing should be followed.

A four tiered system for estimating the cellularity of cytopathology or small biopsy specimens is proposed by expert consensus, however, criteria to determine suitability of specimens depends on the assay used and should be tailored to local needs. Generally, at least 100 tumour cells are needed to enable molecular testing

based on extracted ribonucleic acids (DNA or RNA). Similarly, at least 100 tumour cells are required for predictive IHC (PD-L1) and at least 50 for FISH analysis. Most specimens with low cellularity (100-2,000 tumour cells) should be sufficient for NGS using small NGS panels irrespective of the NGS platform, whereas an intermediate cellularity (2,000-5,000 tumour cells) should qualify for all NGS panels but may be insufficient for large RNA panels.

A high cellularity specimen (>5,000 tumour cells) is suitable for any NGS including large RNA panels. Therefore, using four categories to estimate the number of tumour cells (<100, 100-2,000, 2,000-5,000, and >5,000 tumour cells) appears reasonable. Notably, the number of required tumour cells needed for NGS can vary between the different technologies and platforms (e.g., hybrid capture versus amplicon-based method), the size of the panels and whether DNA or RNA is used. Furthermore, a lower number of cells may be needed for ethanol-fixed cytopathological specimens than for Formalin-Fixed Paraffin-Embedded (FFPE) cell blocks or biopsies due to the superior DNA quality and intact nuclei found in the direct smears. On the other hand, serial sections can be prepared from FFPE material allowing for multiplication of the number of tumour cells for extraction of ribonucleic acids.

Irrespective of the number of tumour cells, the tumour cell fraction in a specimen is critical. Tumour fraction is scored as the percentage of viable tumour cell nuclei present expressed as a proportion of all viable cell nuclei present including admixed inflammatory and stromal cells to the nearest 5% or 10% in an area marked for tumour.

An indication of the level of necrosis may be of value. Necrosis may have adverse effects on molecular testing that may be more pronounced with PCR-based assays. Geographical areas of necrosis may be excluded using manual microdissection methods. The testing laboratory may have recommendations with regard to the extent of acceptable necrosis and the need to exclude these regions from the tissue selected for molecular analysis.

 **Back**

Note 9 – Immunohistochemical or immunocytochemical markers (Core)

Immunohistochemical markers must be used for the diagnosis of some subtypes of lung cancer according to the WHO Classification.⁴ Immunohistochemical markers should be used sparingly to try and preserve material for molecular studies that may be indicated.

In morphologically undifferentiated non-small cell lung carcinomas, immunohistochemical markers or a histochemical marker for mucin are required, if available, for the diagnosis of ‘non-small cell carcinoma, favour adenocarcinoma’ with TTF1 or mucin positivity, or ‘NSCC favour squamous cell carcinoma’ when p40 is positive (refer to Table 1).

Neuroendocrine markers such as INSM1, chromogranin and synaptophysin, should only be used when there are morphological features suggestive of neuroendocrine differentiation.

Mucinous adenocarcinomas of the lung can stain for markers that are more commonly associated with carcinomas of the gastrointestinal tract, such as CK20 and CDX-2, and/or fail to stain with markers typically associated with pulmonary carcinoma, such as CK7 and TTF-1.⁹ A combination of CK7, CK20, TTF1 and SATB2 may assist in distinguishing primary lung adenocarcinomas from metastatic colorectal carcinoma.¹⁰ In such cases, exclusion of metastasis from an extrapulmonary primary is best achieved by careful correlation with the radiological distribution of disease and comparison with the primary tumour whenever possible.

Predictive IHC e.g., PD-L1, ALK is covered in **Note 10 Molecular data**.

 **Back**

Note 10 – Molecular data (Core)

Characterisation of molecular markers is essential in advanced stage non-squamous non-small cell lung cancer (NSCLC) and is becoming increasingly important in early stage and locally advanced disease. However, exactly which markers are required and in what context varies in different countries therefore the reporting pathologist should refer to their local guidelines. Molecular data generally becomes available after the reporting of the original biopsy/cytopathology case and in this circumstance, it should be recorded as pending. It is then up to the reporting pathologist to decide if it is recorded on this dataset or as a separate report.

The number of specific molecular markers required for clinical decision making in the advanced stage setting has expanded and changed over time and varies in different countries depending on availability of specific therapies. Currently, for de novo presentation of advanced stage non squamous NSCLC, molecular data on the status of *EGFR*, *BRAF*, *MET* exon14, *KRAS*, *ERBB2 (HER2)*, *RET*, *ALK*, *ROS1*, and *NTRK1-3* are typically required as a minimum.¹¹⁻¹³ Additional emerging predictive markers such as *HER2* copy number status, *MET* copy number status, TMB, *BRAF* non-V600 status, *FGFR* fusion status, *NRG1* fusion status may be requested.

For patients with early stage disease, molecular testing may be required either on the initial biopsy specimen or on a subsequent resection specimen to guide selection of the optimal drug treatment when clinically appropriate. For example, Epidermal Growth Factor Receptor (*EGFR*) mutation status may guide choice of osimertinib therapy in the adjuvant setting for patients with resected lung adenocarcinoma or immune checkpoint inhibitors¹⁴ or be considered for neoadjuvant immunotherapy. Finally, it can help in decision making around consolidation immunotherapy after chemo-radiotherapy.

Expression of PD-L1 protein by IHC is required in early, locally advanced, and advanced stage NSCLC of squamous or non-squamous histopathology.

In addition to molecular testing of material from de novo NSCLC presentations, established patients with oncogene-addicted NSCLC may relapse on kinase inhibitor therapy and understanding the mechanism of drug resistance may assist additional treatment selection. Thus, these patients may need additional molecular testing to identify resistance mechanisms and therapy opportunities.¹⁵ Therefore, communication between oncologists and pathologists is important to place histopathology, cytopathology and molecular testing in clinical context contingent on local processes.

Given the large number of genetic variants requiring evaluation it is increasingly efficient to test for these using a validated NGS approach rather than single-gene testing. The 2018 American Society of Clinical Oncology (ASCO) endorsement of the College of American Pathology (CAP)/International Association for the Study of Lung Cancer (IASLC)/Association for Molecular Pathology (AMP) guidelines¹⁶ reflect drug approvals in 2018 and more up-to-date guidelines have been published by the National Comprehensive Cancer Network (NCCN) and updated by European Society for Medical Oncology (ESMO) in 2020.¹² However, each laboratory will have established protocols for molecular testing based on local availability and clinical urgency, as single gene tests may still be useful under some clinical circumstances, for example, use of FISH for *MET* copy number detection. For some biomarkers IHC is an acceptable screening or testing strategy. Indeed, according to the 2018 IASLC/CAP/AMP guidelines,¹⁶ *ALK* IHC is now considered an equivalent alternative to FISH *ALK* testing. Similar to *ALK* rearrangements, c-ros oncogene 1 (*ROS1*) rearrangements have been identified in a small subset of patients and also show response to *ROS1* inhibitors.¹⁷ A positive result by *ROS1* IHC needs to be confirmed with molecular testing, as *ROS1* IHC is sensitive but not entirely specific for *ROS1* rearrangements. *NTRK1-3* fusions are very uncommon in lung cancer and are ideally identified by NGS methods (preferentially RNA-sequencing). The merits of routine pan-TRK IHC screening are still subject to debate, but there may be a role for pan-TRK IHC in identifying *NTRK*-fusions in those patients whose tumours are otherwise negative for an oncogene driver.¹⁸

 **Back**

References

- 1 Merlin T, Weston A and Tooher R (2009). Extending an evidence hierarchy to include topics other than treatment: revising the Australian 'levels of evidence'. *BMC Med Res Methodol* 9:34.
- 2 International Collaboration on Cancer Reporting (2023). *Lung Cancer Histopathology Reporting Guide. 4th edition*. Available from: <https://www.iccr-cancer.org/datasets/published-datasets/thorax/lung/> (Accessed 28th February 2023).
- 3 International Collaboration on Cancer Reporting (2022). *Mesothelioma in the Pleura and Peritoneum Histopathology Reporting Guide. 3rd edition*. Available from: <http://www.iccr-cancer.org/datasets/published-datasets/thorax/mesothelioma> (Accessed 10th November 2022).
- 4 WHO Classification of Tumours Editorial Board (2021). *Thoracic Tumours, 5th Edition, Volume 5*. IARC Publications, Lyon.
- 5 International Academy of Cytology - International Agency for Research on Cancer - World Health Organization Joint Editorial Board (2022). *WHO Reporting System for Lung Cytopathology*. IAC-IARC-WHO Cytopathology Reporting Systems, 1st Edition, Volume 1. IARC Publications, Lyon.
- 6 Lin O (2018). Telecytology for Rapid On-Site Evaluation: Current Status. *J Am Soc Cytopathol* 7(1):1-6.
- 7 Girard N, Deshpande C, Lau C, Finley D, Rusch V, Pao W and Travis WD (2009). Comprehensive histologic assessment helps to differentiate multiple lung primary nonsmall cell carcinomas from metastases. *Am J Surg Pathol* 33(12):1752-1764.
- 8 Detterbeck FC, Nicholson AG, Franklin WA, Marom EM, Travis WD, Girard N, Arenberg DA, Bolejack V, Donington JS, Mazzone PJ, Tanoue LT, Rusch VW, Crowley J, Asamura H and Rami-Porta R (2016). The IASLC Lung Cancer Staging Project: Summary of Proposals for Revisions of the Classification of Lung Cancers with Multiple Pulmonary Sites of Involvement in the Forthcoming Eighth Edition of the TNM Classification. *J Thorac Oncol* 11(5):639-650.
- 9 Rossi G, Murer B, Cavazza A, Losi L, Natali P, Marchioni A, Migaldi M, Capitanio G and Brambilla E (2004). Primary mucinous (so-called colloid) carcinomas of the lung: a clinicopathologic and immunohistochemical study with special reference to CDX-2 homeobox gene and MUC2 expression. *Am J Surg Pathol* 28(4):442-452.
- 10 Alabdullah B and Hadji-Ashrafy A (2022). Identification of the most specific markers to differentiate primary pulmonary carcinoma from metastatic gastrointestinal carcinoma to the lung. *Diagn Pathol* 17(1):7.
- 11 Lindeman NI, Cagle PT, Aisner DL, Arcila ME, Beasley MB, Bernicker EH, Colasacco C, Dacic S, Hirsch FR, Kerr K, Kwiatkowski DJ, Ladanyi M, Nowak JA, Sholl L, Temple-Smolkin R, Solomon B, Souter LH, Thunnissen E, Tsao MS, Ventura CB, Wynes MW and Yatabe Y (2018). Updated Molecular Testing Guideline for the Selection of Lung Cancer Patients for Treatment With Targeted Tyrosine Kinase Inhibitors: Guideline From the College of American Pathologists, the International Association for the Study of Lung Cancer, and the Association for Molecular Pathology. *J Mol Diagn* 20(2):129-159.
- 12 Dingemans AC, Früh M, Ardizzoni A, Besse B, Faivre-Finn C, Hendriks LE, Lantuejoul S, Peters S, Reguart N, Rudin CM, De Ruyscher D, Van Schil PE, Vansteenkiste J and Reck M (2021). Small-cell lung cancer: ESMO Clinical Practice Guidelines for diagnosis, treatment and follow-up. *Ann Oncol* 32(7):839-853.

- 13 Wu YL, Planchard D, Lu S, Sun H, Yamamoto N, Kim DW, Tan DSW, Yang JC, Azrif M, Mitsudomi T, Park K, Soo RA, Chang JWC, Alip A, Peters S and Douillard JY (2019). Pan-Asian adapted Clinical Practice Guidelines for the management of patients with metastatic non-small-cell lung cancer: a CSCO-ESMO initiative endorsed by JSMO, KSMO, MOS, SSO and TOS. *Ann Oncol* 30(2):171-210.
- 14 Wu YL, Tsuboi M, He J, John T, Grohe C, Majem M, Goldman JW, Laktionov K, Kim SW, Kato T, Vu HV, Lu S, Lee KY, Akewanlop C, Yu CJ, de Marinis F, Bonanno L, Domine M, Shepherd FA, Zeng L, Hodge R, Atasoy A, Rukazenzov Y and Herbst RS (2020). Osimertinib in Resected EGFR-Mutated Non-Small-Cell Lung Cancer. *N Engl J Med* 383(18):1711-1723.
- 15 Passaro A, Jänne PA, Mok T and Peters S (2021). Overcoming therapy resistance in EGFR-mutant lung cancer. *Nat Cancer* 2(4):377-391.
- 16 Kalemkerian GP, Narula N, Kennedy EB, Biermann WA, Donington J, Leighl NB, Lew M, Pantelas J, Ramalingam SS, Reck M, Saqi A, Simoff M, Singh N and Sundaram B (2018). Molecular Testing Guideline for the Selection of Patients With Lung Cancer for Treatment With Targeted Tyrosine Kinase Inhibitors: American Society of Clinical Oncology Endorsement of the College of American Pathologists/International Association for the Study of Lung Cancer/Association for Molecular Pathology Clinical Practice Guideline Update. *Journal of Clinical Oncology* 36(9):911-919.
- 17 Shaw AT, Ou SH, Bang YJ, Camidge DR, Solomon BJ, Salgia R, Riely GJ, Varella-Garcia M, Shapiro GI, Costa DB, Doebele RC, Le LP, Zheng Z, Tan W, Stephenson P, Shreeve SM, Tye LM, Christensen JG, Wilner KD, Clark JW and Iafrate AJ (2014). Crizotinib in ROS1-rearranged non-small-cell lung cancer. *N Engl J Med* 371(21):1963-1971.
- 18 Marchiò C, Scaltriti M, Ladanyi M, Iafrate AJ, Bibeau F, Dietel M, Hechtman JF, Troiani T, López-Rios F, Douillard JY, André F and Reis-Filho JS (2019). ESMO recommendations on the standard methods to detect NTRK fusions in daily practice and clinical research. *Ann Oncol* 30(9):1417-1427.