

Invasive Carcinoma of the Breast in the Setting of Neoadjuvant Therapy Histopathology Reporting Guide

Family/Last name

Date of birth

DD - MM - YYYY

Given name(s)

Patient identifiers

Date of request

DD - MM - YYYY

Accession/Laboratory number

Elements in **black text** are **CORE**. Elements in **grey text** are **NON-CORE**.

SCOPE OF THIS DATASET

 indicates multi-select values indicates single select values**CLINICAL INFORMATION** (Note 1) Information not provided**Neoadjuvant treatment(s)** (select all that apply)

- Information not provided Hormonal therapy
 Chemotherapy Anti-HER2 targeted therapy
 Immune therapy Radiation therapy
 Other, *specify*

Pre-treatment tumour characteristics Information not provided

Laterality

Site(s)

Date of diagnosis

Imaging size at diagnosis

Fiducial marker placement

Diagnosis

Hormone receptor and HER2 status

Other (e.g., tumour grade, tumour cellularity, tumour infiltrating lymphocytes (TIL), Ki-67, multigene assays), *specify if available***Pre-treatment axillary lymph node biopsy/sampling**

(select all that apply)

- Not applicable Not known
 Core biopsy Fine needle aspiration (FNA)
 Other, *specify* Sentinel node biopsy

Fiducial marker placed Yes NoResult Positive Negative**Other clinical information, specify****OPERATIVE PROCEDURE - BREAST** (Note 2)

- Not specified
 Excision (less than total mastectomy)
 Therapeutic wide local excision
 Re-excision
 Total mastectomy
 Simple mastectomy
 Nipple-sparing mastectomy
 Skin-sparing mastectomy
 Modified radical mastectomy
 Radical mastectomy

 Additional specimens, *specify***OPERATIVE PROCEDURE - AXILLA** (select all that apply) (Note 3)

- Sentinel lymph node biopsy
 Targeted non-sentinel lymph node biopsy (dissection)
 Other non-sentinel lymph node biopsy
 Axillary lymph node dissection
 Level I
 Levels I and II
 Levels I to III
 Axillary lymph node level III, excision
 Other regional lymph node(s) biopsy
 Internal mammary
 Infraclavicular (subclavicular)
 Supraclavicular
 Other, *specify*

SPECIMEN LATERALITY (Note 4) Left Right Not specified**SPECIMEN DIMENSIONS** mm x mm x mm**SPECIMEN WEIGHT** g

SPECIMEN DETAILS

Depth of tissue excised

Skin to deep fascia Yes No

Specimen includes (select all that apply)

Skin Nipple Skeletal muscle

TUMOUR SITE (select all that apply) (Note 5)

Not specified

Distance from nipple mm

AND

Position, *specify* o'clock

OR

Upper outer quadrant

Lower outer quadrant

Upper inner quadrant

Lower inner quadrant

Central

Nipple

Other, *specify*

TUMOUR FOCALITY (Note 6)

Cannot be determined

Single focus of invasive carcinoma

Multiple foci of invasive carcinoma on pre-treatment imaging and on pathologic evaluation, *describe*^a

Multiple foci of invasive carcinoma within a single (fibrotic) tumour bed corresponding to a single focus on pre-treatment imaging

Number of foci

Cannot be assessed

is at least

Morphology of multiple foci^b

Distinct

Similar



Histological tumour type

Histological tumour grade

Receptor status

Cellularity

Size mm

^a See also NOTE 8.

^b Core element if multiple foci only.

Morphology of multiple foci^b

Distinct

Similar



Histological tumour type

Histological tumour grade

Receptor status

Cellularity

Size mm

Morphology of multiple foci^b

Distinct

Similar



Histological tumour type

Histological tumour grade

Receptor status

Cellularity

Size mm

RESIDUAL INVASIVE CARCINOMA (Note 7)

Present

Absent^c

Pre-treatment tumour site identified^d

Uncertain

Yes (select all that apply)

Palpable/visible area on gross examination

Area of concern on specimen radiograph

Calcifications associated with tumour pre-treatment identified

Ductal carcinoma in situ (DCIS) identified

Fiducial marker (clip or equivalent) identified

Surgical localization marker (wire, seed or equivalent) identified

Histologic changes suggestive of tumour bed

Targeted lumpectomy thoroughly sampled

None of the above but likely areas thoroughly sampled

A reference map documents the blocks sampled for histologic evaluation

Cannot be assessed, *specify*

^c If there is no residual invasive carcinoma then the remaining elements pertaining to residual invasive carcinoma (**Tumour dimensions, Tumour cellularity/composition, Histologic tumour type, Post-treatment histologic tumour grade, Tumour extension, Margin status, Post-treatment estrogen receptor, Post-treatment progesterone receptor, Post-treatment HER2 and Post-treatment ancillary studies**) are removed from the report.

^d Core element if residual invasive carcinoma absent.

TUMOUR DIMENSIONS^e (Note 8)

No residual invasive carcinoma

Maximum dimension of largest contiguous invasive focus



≤1 mm

>1 mm (specify exact measurement rounded to nearest mm)

Maximum 2 dimensions of the area containing residual invasive carcinoma, representing a single residual tumour bed and including any intervening fibrosis, fat, or breast parenchyma (specify 2 exact measurements rounded to nearest mm)

mm x mm (RCB area dimensions)

Maximum dimension of whole tumour field (invasive + DCIS)/total extent of disease mm

Cannot be assessed, specify

^e Based on a combination of macroscopic and microscopic assessment.

TUMOUR CELLULARITY/COMPOSITION (Note 9)

No residual invasive carcinoma

Estimate of Residual Cancer Cellularity using one of two methods below:

Residual Cancer Cellularity (invasive and in situ)^f

% OR <1%, specify^g %

- 1%
- 5%
- 10%
- 20%
- 30%
- 40%
- 50%
- 60%
- 70%
- 80%
- 90%

AND

Percentage of residual carcinoma that is carcinoma in situ (CIS) %

^f The pathologist estimates the average percent of cancer (invasive and in situ) within the area of residual invasive cancer, and then estimates the percent that is in situ component.

^g Note that very low cellularity can sometimes be estimated at very low values (e.g., 0.01%) and any decimal result is acceptable.

OR

Residual Cancer Cellularity (invasive only)^h

% OR <1%, specify^g %

- 1%
- 5%
- 10%
- 20%
- 30%
- 40%
- 50%
- 60%
- 70%
- 80%
- 90%

Other, specify %

Comparison with pre-treatment cellularity if available, specify

Percent TILs in tumour stroma % post-treatment

Cannot be assessed, specify

^h The pathologist estimates the average percent of invasive cancer within the area of residual invasive cancer. Zero is entered for the percentage of cancer that is in situ disease in the RCB calculator. See Note 12 for details about in situ disease.

HISTOLOGICAL TUMOUR TYPE (Note 10)

(Value list from the World Health Organization Classification of Breast Tumours (2019))

- No residual invasive carcinoma
- Invasive breast carcinoma of no special type (invasive ductal carcinoma, not otherwise specified)ⁱ
- Invasive lobular carcinoma
- Tubular carcinoma
- Cribriform carcinoma
- Mucinous carcinoma
- Invasive micropapillary carcinoma
- Carcinoma with apocrine differentiation
- Metaplastic carcinoma
- Mixed, specify subtypes present^j

Other, specify

ⁱ Refer to Note for details of variants including medullary carcinoma.

^j Tumour exhibiting more than one tumour type should be designated mixed and the types present stated.

POST-TREATMENT HISTOLOGICAL TUMOUR GRADE

(Note 11)

- No residual invasive carcinoma
- Grade 1 (scores of 3, 4, or 5)
- Grade 2 (scores of 6 or 7)
- Grade 3 (scores of 8 or 9)



Tubule score 1,2,3

Nuclear pleomorphism 1,2,3

Mitotic count

per mm²

OR

per 10 HPF (field diameter ____ mm)

Score 1,2,3

Total score

- Too small or insufficient tumour cellularity to grade
- Cannot be reliably determined due to post-treatment changes

CARCINOMA IN SITU (Note 12)

- Not identified
- Present (select all that apply)
 - DCIS
 - Negative for extensive intraductal component (EIC)
 - Positive for EIC
 - Paget disease of the nipple
 - Encapsulated papillary carcinoma
 - Solid papillary carcinoma in situ
 - Lobular carcinoma in situ (LCIS)

CLASSIFICATION OF CARCINOMA IN SITU (if present)
(Note 12)

Histological nuclear grade

(Applicable to DCIS, encapsulated papillary carcinoma and solid papillary carcinoma in situ)

- Grade 1 (Low)
- Grade 2 (Intermediate)
- Grade 3 (High)

Histological architectural pattern (select all that apply)

(Applicable to DCIS only)

- Cribriform
- Micropapillary
- Papillary
- Solid
- Other (e.g., clinging/flat^k), specify

^k Applies to high nuclear grade DCIS only.

Necrosis

- Not identified
- Present
 - Central (Comedo) necrosis
 - Focal (Punctate) necrosis (<10% duct diameter)

Classification of LCIS (select all that apply)
(Applicable if LCIS is present in specimen)

- Classical LCIS
- Pleomorphic LCIS
- Florid LCIS
- Other, specify

TUMOUR EXTENSION¹ (Note 13)

Skin

- Skin is not present
- Skin is present and uninvolved
- Invasive carcinoma directly invades into the dermis or epidermis without skin ulceration
- Invasive carcinoma directly invades into the dermis or epidermis with skin ulceration (classified as ypT4b)
- Satellite skin foci of invasive carcinoma are present (i.e., not contiguous with the invasive carcinoma in the breast) (classified as ypT4b)

Nipple (including areola complex)

- Nipple tissue is not present
- DCIS does not involve the nipple epidermis
- DCIS involves nipple epidermis (Paget disease of the nipple)

Skeletal muscle

- Skeletal muscle is not present
- Skeletal muscle is free of carcinoma
- Tumour involves skeletal muscle
- Tumour involves both skeletal muscle and chest wall (classified as ypT4a)

¹ Where there is disease extension to involve skin, nipple or skeletal muscle, disease extent classification is a core element; in all other cases it is non-core.

MARGIN STATUS^m (Note 14)

(For wide local excision specimens and similar non-complete mastectomy specimens)

Cannot be assessed, *specify*

Invasive carcinoma

Involved (select all that apply)

Anterior (superficial)

Specify extent

Posterior (deep)

Specify extent

Superior

Specify extent

Inferior

Specify extent

Medial

Specify extent

Lateral

Specify extent

Other margin, *specify*

Specify extent

Not involved

Specify closest margin, if possible

Distance of invasive carcinoma to closest margin

mm

(< or > may be used)

Cannot be determined, *specify*

Distance of invasive carcinoma to other margins (< or > may be used)

Anterior (superficial)

mm

Posterior (deep)

mm

Superior

mm

Inferior

mm

Medial

mm

Lateral

mm

Other margin, *specify*

mm

DCISⁿ

Involved (select all that apply)

Anterior (superficial)

Specify extent

Posterior (deep)

Specify extent

Superior

Specify extent

Inferior

Specify extent

Medial

Specify extent

Lateral

Specify extent

Other margin, *specify*

Specify extent

Not involved

Specify closest margin, if possible

Distance of DCIS to closest margin

mm

Cannot be determined, *specify*

Distance of DCIS to other margins (< or > may be used)

Anterior (superficial)

mm

Posterior (deep)

mm

Superior

mm

Inferior

mm

Medial

mm

Lateral

mm

Other margin, *specify*

mm

ⁿ Required only if DCIS or florid LCIS or pleomorphic LCIS is also present in specimen.

^m Core for all wide local excision specimens, similar non-complete mastectomy and some (refer to Note) complete mastectomy specimens.

MARGIN STATUS^m (Note 14)

(For complete mastectomy specimens)

Cannot be assessed, specify

Invasive carcinoma

Involved, specify margin/sites of involvement

Not involved

Specify closest margin, if possible

Distance of invasive carcinoma to closest margin

 mm (< or > may be used)

Cannot be determined, specify

DCISⁿ

Involved, specify margin/sites of involvement

Not involved

Specify closest margin, if possible

Distance of DCIS to closest margin

 mm (< or > may be used)

Cannot be determined, specify

^mCore for all wide local excision specimens, similar non-complete mastectomy and some (refer to Note) complete mastectomy specimens.

ⁿRequired only if DCIS or florid LCIS or pleomorphic LCIS is also present in specimen.

LYMPHOVASCULAR INVASION (Note 15)

Not identified

Present

Specify extent

Indeterminate

COEXISTENT PATHOLOGY (Note 16)

None identified

Present, specify

MICROCALCIFICATIONS (select all that apply) (Note 17)

Not identified

Present in DCIS

Present in invasive carcinoma

Present in non-neoplastic tissue

Other, specify

POST-TREATMENT ESTROGEN RECEPTOR (ER) (Note 18)

Antibody clone, specify

Testing performed Yes No

Positive

Low positive

For both options above specify percentage of cells with nuclear positivity^o

 %

OR Range

- 1-10%^p
- 11-20%
- 21-30%
- 31-40%
- 41-50%
- 51-60%
- 61-70%
- 71-80%
- 81-90%
- 91-100%

AND

Average intensity of staining

Weak

Moderate

Strong

Negative (less than 1% nuclear positivity)

Internal control cells present and stain as expected

Internal control cells absent

Other, specify

Cannot be determined

Internal control cells present but no immunoreactivity of either tumour cells or internal controls

Other, specify

^oPercentage of cells with nuclear positivity may be reported as a specific number or a range if more than 10%.

^pClassified as low ER positive.

POST-TREATMENT PROGESTERONE RECEPTOR (PR)
(Note 19)

Antibody clone, specify

Testing performed Yes No

Positive

Percentage of cells with nuclear positivity^o

% OR Range

- 1-10%
- 11-20%
- 21-30%
- 31-40%
- 41-50%
- 51-60%
- 61-70%
- 71-80%
- 81-90%
- 91-100%

AND

Average intensity of staining

- Weak
- Moderate
- Strong

Negative (less than 1% nuclear positivity)

- Internal control cells present and stain as expected
- Internal control cells absent
- Other, specify

Cannot be determined

Internal control cells present; no immunoreactivity of either tumour cells or internal controls

Other, specify

^o Percentage of cells with nuclear positivity may be reported as a specific number or a range if more than 10%.

POST-TREATMENT HER2 (Note 20)

Antibody clone, specify

Testing performed Yes No

By immunohistochemistry (IHC)

- Not performed
- Negative (Score 0)
- Negative (Score 1+)
- Equivocal (Score 2+)
- Positive (Score 3+)

Percentage of cells with uniform, intense, complete membrane staining %

Cannot be determined, specify

By in situ hybridization

- Not performed
- Negative (not amplified)
- Positive (amplified)
- Pending
- Cannot be determined, specify

Number of observers

Number of invasive tumour cells counted

Dual probe assay

Average number of HER2 signals per cell

Average number of CEP17 signals per cell

HER2/CEP17 ratio /

Single probe assay

Average number of HER2 signals per cell

Aneusomy

- Not identified
- Present

Heterogeneous signals

- Not identified
- Present

Percentage of cells with amplified HER2 signals %

POST-TREATMENT ANCILLARY STUDIES (Note 21)

- Not performed
- Performed

Ki-67 proliferation index %

Other, specify test(s) and result(s)

Representative blocks for ancillary studies, specify those blocks best representing tumour and/or normal tissue for further study

NUMBER OF LYMPH NODES EXAMINED (Note 22)

(These values may be reported in the corresponding cells in Table 1A)

Total number of sentinel lymph nodes examined^q

Total number of non-sentinel lymph nodes examined^r

Total number of lymph nodes examined

^q Core element only if sentinel lymph nodes are submitted by the surgeon.

^r Non-sentinel lymph nodes include:

1. any lymph node submitted by the surgeon as 'non-sentinel lymph node' at the time of sentinel lymph node biopsy; and
2. axillary lymph nodes from an axillary lymph node dissection.

Evidence of fiducial marker

- Not applicable
- No evidence of a fiducial marker
- Evidence of fiducial marker associated with lymph node, specify

NUMBER OF LYMPH NODES WITH METASTATIC CARCINOMA^s (Note 23)

(This value may be reported in the corresponding cell in Table 1A)

^s This value includes the number of lymph nodes with macrometastatic (>2 mm) and micrometastatic carcinoma (>0.2 mm to 2 mm and/or ≥200 cells).

NUMBER OF LYMPH NODES WITH MACROMETASTASES^t

Sentinel lymph nodes

Non-sentinel lymph nodes

Total lymph nodes

^t A macrometastasis is any tumour deposit spanning >2 mm microscopically.

NUMBER OF LYMPH NODES WITH MICROMETASTASES^u (Note 24)

Sentinel lymph nodes

Non-sentinel lymph nodes

Total lymph nodes

^u A micrometastasis is any tumour deposit spanning >0.2 mm to 2 mm microscopically and/or consisting of more than 200 cells in one lymph node section but not exceeding 2 mm in extent.

NUMBER OF LYMPH NODES WITH ISOLATED TUMOUR CELLS (ITCs)^v (Note 25)

(These responses may be reported in the corresponding cells in Table 1A)

Sentinel lymph nodes

Non-sentinel lymph nodes

Total lymph nodes

^v ≤0.2 mm and ≤200 cells.

SIZE OF LARGEST METASTASIS^w (Note 26)

Not assessable^x

Size of largest contiguous metastatic tumour cell deposit (without intervening fibrosis)^y mm (TNM size)

Extent of largest lymph node metastasis (with intervening fibrosis)^z mm (RCB size)

^w Required only if macro- or micrometastatic carcinoma is present.

^x Only to be used for cases investigated by one-step nucleic acid amplification.

^y Largest contiguous metastatic tumour cell deposit determines micrometastasis versus macrometastasis for pN staging.

^z Measurement used for calculation of RCB.

EXTRANODAL EXTENSION^A (Note 27)

(This response may be reported in the corresponding cell in Table 1A)

- Not identified
- Present
- Cannot be determined

^A Core element only if macro- or micrometastases are present.

TREATMENT EFFECT (Note 28)

(These responses may be reported in the corresponding cells in Table 1B)

Treatment effect (A) – Presence of treatment effect in lymph nodes containing residual metastatic carcinoma

- Not identified
- Present
- Cannot be determined

Treatment effect (B) – Presence of treatment effect in lymph nodes without metastatic carcinoma

Number of lymph nodes with changes suggestive of treatment effect without metastatic carcinoma

PATHOLOGIC COMPLETE RESPONSE (pCR) (Note 29)

- pCR (ypT0 ypN0/cN0)
- pCR (ypTis ypN0/cN0) (residual DCIS)
- Residual invasive cancer – Not pCR
- Lymphovascular invasion only – Not pCR
- ITCs only (ypN0(i+)) – Not pCR

RESIDUAL CANCER BURDEN (RCB) (Note 30)

Cannot be determined
 No residual invasive carcinoma
 Residual invasive carcinoma

RCB area dimensions mm x mm

AND

Average cancer cellularity in RCB area^B %

% in situ component^C

OR

Average invasive cancer cellularity in RCB area^B %

Number of lymph nodes with carcinoma^C

Extent of largest lymph node metastasis mm

RCB score^D

RCB class^D 0 I II III

^B Enter this value, and 0% for % CIS, in the RCB calculator (see Note).

^C The number of lymph nodes with carcinoma, including the number of lymph nodes with ITCs, is used for calculating RCB.

^D Core element if neoadjuvant treatment includes chemotherapy and the RCB calculator is accessible.

PATHOLOGICAL STAGING (UICC TNM 8th edition)^E (Note 31)

TNM Descriptors (only if applicable) (select all that apply)

- r - recurrent
 m - multiple foci of invasive carcinoma
 y - post-therapy
 c - based on clinical or imaging studies, no histopathologic examination was performed – or lymph node assessment was done without the primary breast tumour being removed

Primary tumour (pT)

- ypTX Primary tumour cannot be assessed
 ypT0 No evidence of primary tumour
 ypT1 Tumour 2 cm or less in greatest dimension
 - ypT1a More than 0.1 cm but not more than 0.5 cm in greatest dimension
 - ypT1b More than 0.5 cm but not more than 1 cm in greatest dimension
 - ypT1c More than 1 cm but not more than 2 cm in greatest dimension ypT2 Tumour more than 2 cm but not more than 5 cm in greatest dimension
 ypT3 Tumour more than 5 cm in greatest dimension
 ypT4 Tumour of any size with direct extension to chest wall and/or to skin (ulceration or skin nodules)^F
 - ypT4a Extension to chest wall (does not include pectoralis muscle invasion only)
 - ypT4b Ulceration, ipsilateral satellite skin nodules, or skin oedema (including peau d'orange)
 - ypT4c Both 4a and 4b
 - ypT4d Inflammatory carcinoma^G

Regional lymph nodes (pN)

(This value may be reported in the corresponding cell in Table 1A)

- ypNX Regional lymph nodes cannot be assessed (e.g., previously removed, or not removed for pathological study)
 ypN0 No regional lymph node metastasis
 ypN1 Micrometastasis: or metastasis in 1 to 3 axillary ipsilateral lymph nodes: and/or in internal mammary nodes with metastases detected by sentinel lymph node biopsy but not clinically detected^H
 - ypN1mi Micrometastasis (larger than 0.2 mm and/or more than 200 cells, but none larger than 2.0 mm)
 - ypN1a Metastasis in 1–3 axillary lymph node(s), including at least one larger than 2 mm in greatest dimension
 - ypN1b Metastasis in internal mammary lymph nodes not clinically detected^H
 - ypN1c Metastasis in 1–3 axillary lymph nodes and internal mammary lymph nodes not clinically detected^H ypN2 Metastasis in 4–9 ipsilateral axillary lymph nodes, or in clinically detected^H ipsilateral internal mammary lymph node(s) in the absence of axillary lymph node metastasis
 - ypN2a Metastasis in 4–9 axillary lymph nodes, including at least one that is larger than 2 mm
 - ypN2b Metastasis in clinically detected internal mammary lymph node(s), in the absence of axillary lymph node metastasis ypN3 Metastasis as described below:^I
 - ypN3a Metastasis in 10 or more ipsilateral axillary lymph nodes (at least one larger than 2 mm) or metastasis in infraclavicular lymph nodes/level III lymph nodes
 - ypN3b Metastasis in clinically detected^H internal ipsilateral mammary lymph node(s) in the presence of positive axillary lymph node(s): or metastasis in more than 3 axillary lymph nodes and in internal mammary lymph nodes with microscopic or macroscopic metastasis detected by sentinel lymph node biopsy but not clinically detected
 - ypN3c Metastasis in ipsilateral supraclavicular lymph node(s)

^E Reproduced with permission. Source: UICC TNM Classification of Malignant Tumours, 8th Edition, eds by James D. Brierley, Mary K. Gospodarowicz, Christian Wittekind. 2016, Publisher Wiley (incorporating any errata published up until 6th October 2020).

^F Invasion of the dermis alone does not qualify as ypT4. Chest wall includes ribs, intercostal muscles, and serratus anterior muscle but not pectoral muscle.

^G Inflammatory carcinoma of the breast is characterised by diffuse, brawny induration of the skin with an erysipeloid edge, usually with no underlying mass. If a cancer was classified as inflammatory (cT4d before neoadjuvant chemotherapy, the cancer is still classified as inflammatory breast cancer after therapy, even if complete resolution of the inflammatory findings is observed during treatment. The post-treatment pathological classification (ypT) should reflect the extent of identified residual disease, and the pathology report should note that the pre-treatment classification was cT4d. Dimpling of the skin, nipple retraction, or other skin changes, except those in ypT4b and ypT4d, may occur in ypT1, ypT2, or ypT3 without affecting the classification.

^H Clinically detected is defined as detected by imaging studies (excluding lymphoscintigraphy) or by clinical examination and having characteristics highly suspicious for malignancy or a presumed pathological macrometastasis based on FNA biopsy with cytological examination. Confirmation of clinically detected metastatic disease by FNA without excision biopsy is designated with a (f) suffix, e.g., cN3a(f). Not clinically detected is defined as not detected by imaging studies (excluding lymphoscintigraphy) or not detected by clinical examination.

^I Definition of N3 not included in UICC TNM 8th Edition.

The following tables are provided for reference, and may be used as needed.

Core elements are summarised in Table 1A. Although all core elements need to be reported for accurate staging of lymph node status, reporting in table format is not required, and the same information may be provided as indicated in the reporting guide. The same applies to the non-core elements summarised in Table 1B.

Table 1A: Regional lymph node status – core elements

Type of lymph nodes	Number of lymph nodes	Status post-neoadjuvant treatment ^c	Total lymph nodes with metastatic carcinoma (size >0.2 mm)	Size of largest metastasis (mm) ^d	Only ITCs present (Yes/No)	Total lymph nodes with ITCs ^e	pN status (UICC TNM8) ^f	Extranodal extension (ENE)
SLNs ^a								
Non-SLNs ^a								
Total lymph nodes ^b								

SLNs: sentinel lymph nodes

ITCs: isolated tumour cells

ENE: extranodal extension

Status post-neoadjuvant treatment: Information not provided

No neoadjuvant treatment given

Residual disease not identified

Residual disease present

ENE: Not identified

Present

Cannot be determined

^a Core elements only if SLN biopsy was performed; if no SLN biopsy was performed report only total number of lymph nodes (LNs).

^b The total number of LNs removed includes the number of SLNs (if SLN biopsy was performed) + number of non-SLNs. Non-SLNs are all the LNs that are not submitted as SLNs by the surgeon. If an axillary lymph node dissection has been performed without a SLN biopsy, only the total number of LNs needs to be given.

^c If the LNs were obtained post-neoadjuvant treatment, it is strongly suggested to provide the non-core information summarised in Table 1B.

^d If the size cannot be measured (e.g., LN removed in several pieces and multiple pieces involved by the metastatic process) the largest measurable size should be given as 'at least' size. If one-step nucleic acid amplification was used for nodal staging the size will be not assessable; the CK19 mRNA copy numbers can be given alternatively as a quantitative value. (Macrometastasis: one-step nucleic acid amplification assay result with >5000 CK19 mRNA copy number/ μ L lysate; Micrometastasis: one-step nucleic acid amplification assay result with CK19 mRNA copy number between 250 and 5000/ μ L lysate).

^e ITCs are tumour deposits spanning ≤ 0.2 mm and ≤ 200 cells in a single LN profile. LNs with ITCs are not counted as metastatic LNs for pN stage. LNs with ITCs are counted in the number of lymph nodes with carcinoma for RCB calculation.

^f If SLN biopsy was performed the minimum number of LNs required for staging purposes is one (sentinel) LN. If no SLN biopsy was performed, non-SLNs usually are obtained by axillary LN dissection (level I + level II +/- level III axillary LNs, depending on regional practices).

Table 1B: Regional lymph node status post-neoadjuvant treatment – non-core elements

Tumour regression	Number of lymph nodes WITH residual carcinoma	Number of lymph nodes WITHOUT residual carcinoma	Total number of lymph nodes
Not identified			
Present			
Cannot be determined			
Total lymph nodes examined			

Definitions

CORE elements

CORE elements are those which are essential for the clinical management, staging or prognosis of the cancer. These elements will either have evidentiary support at Level III-2 or above (based on prognostic factors in the National Health and Medical Research Council (NHMRC) levels of evidence¹). In rare circumstances, where level III-2 evidence is not available an element may be made a core element where there is unanimous agreement by the Dataset Authoring Committee (DAC). An appropriate staging system e.g., Pathological TNM staging would normally be included as a CORE element.

Non-morphological testing e.g., molecular or immunohistochemical testing is a growing feature of cancer reporting. However, in many parts of the world this type of testing is limited by the available resources. In order to encourage the global adoption of ancillary tests for patient benefit, International Collaboration on Cancer Reporting (ICCR) recommends that some ancillary testing in ICCR Datasets is included as core elements. Where the technical capability does not yet exist, laboratories may consider temporarily using these data elements as NON-CORE items.

The summation of all CORE elements is considered to be the minimum reporting standard for a specific cancer.

NON-CORE elements

NON-CORE elements are those which are unanimously agreed should be included in the dataset but are not supported by level III-2 evidence. These elements may be clinically important and recommended as good practice but are not yet validated or regularly used in patient management.

Key information other than that which is essential for clinical management, staging or prognosis of the cancer such as macroscopic observations and interpretation, which are fundamental to the histological diagnosis and conclusion e.g., macroscopic tumour details, may be included as either CORE or NON-CORE elements by consensus of the DAC.

 [Back](#)

Scope

This dataset has been developed for the reporting of resection specimens after neoadjuvant therapy from patients with invasive carcinoma of the breast with or without ductal carcinoma in situ (DCIS). This dataset is for post-treatment surgical specimens. Core needle biopsies are not included.

A brief pre-operative exposure is not considered neoadjuvant therapy. This document is intended where neoadjuvant treatment was of longer duration with therapeutic intent.

This dataset overlaps with the ICCR dataset for reporting of resection specimens from patients with invasive breast carcinoma, the ICCR dataset for reporting of DCIS without invasive carcinoma and microinvasive carcinoma (≤ 1 millimetres (mm)) where DCIS represents residual disease post neoadjuvant therapy, and the ICCR dataset for reporting surgically removed lymph nodes for breast

tumours.²⁻⁴ Reporting of resection specimens after neoadjuvant therapy from patients with invasive carcinoma of the breast requires multidisciplinary collaboration and specialised handling of the resection specimen. A separate dataset for the neoadjuvant setting containing both the standard elements that remain applicable after neoadjuvant therapy and the elements specific for the neoadjuvant setting is provided to be used in conjunction with the other ICCR datasets, as appropriate.

The reporting of DCIS without invasive carcinoma and microinvasive carcinoma (≤ 1 mm), pleomorphic and florid lobular carcinoma in situ (LCIS), encapsulated papillary carcinoma and solid papillary carcinoma in situ are dealt with in a separate ICCR dataset.³ Sarcomas with or without neoadjuvant therapy are covered in a separate ICCR dataset.⁵

Ipsilateral multifocal disease should be dealt with in a single report. For bilateral invasive breast tumours, a separate dataset should be completed for each side.

General information related to this dataset is outlined in [Appendix 1](#).

The authors of this dataset can be accessed [here](#).

↑ Back

Note 1 – Clinical information (Core)

It is imperative to alert the pathologist that the specimen has been resected following neoadjuvant therapy. Residual invasive carcinoma post neoadjuvant therapy is often difficult to identify grossly. Without the information that the specimen is post neoadjuvant therapy and information regarding the location and size of tumour foci prior to treatment, appropriate sampling of the correct area of the breast is not possible. Information about the type of treatment received and prior diagnosis helps the pathologist to know what to expect in terms of response to treatment and helps to guide the extent of initial sampling.

Fiducial markers are radiological clips or other markers placed at the site of the primary breast tumour(s) pre-treatment to indicate the location of the tumour bed in case of excellent clinical/radiological response to therapy. The placement of fiducial markers should be documented and communicated to the pathologist as they help the pathologist identify the pre-treatment tumour site. Fiducial marker placement in biopsied lymph nodes with removal of the marked lymph nodes improves the accuracy of sentinel lymph node biopsy after neoadjuvant therapy. If an intra-operative specimen x-ray has been carried out in the operating theatre the findings should be communicated to the pathologist.

Pre-treatment clinical-radiologic nodal status in the axilla is important information to guide handling and interpretation of axillary surgical specimens. The clinical-radiologic findings may include needle biopsy results from a suspicious node. If a pre-treatment axillary sentinel lymph node excision was performed and there was nodal metastasis, then response in the lymph nodes cannot be evaluated with accuracy and the residual cancer burden (RCB) and ypTNM staging become invalid. Positive lymph nodes removed before neoadjuvant therapy are given a clinical N stage.

Pre-treatment assessment of cancer cellularity by area (percent tumour cellularity) is compared with post-treatment tumour cellularity in some methods of response grading. Centres that use those response assessments may prefer to collect this optional information.

There is accumulating evidence in the literature that the presence of tumour infiltrating lymphocytes (TIL) provides important prognostic and predictive information for some molecular subtypes of breast cancer.⁶ Pre-treatment assessment of TILs, estimated as a percentage of stromal area, is optional.

↑ Back

Note 2 – Operative procedure - Breast (Core)

The nature of the operation or procedure(s) performed is important to ensure appropriate pathological examination protocols are followed, and accurate clinical correlation and post-operative management discussion take place. The nature, extent, focality of the abnormality and patient choice can influence the type of operation. Multiple procedures may be performed and sent as separate specimens which require cross correlation. The forms of surgical procedure used to manage breast disease are considerable and more specific detail of the specimen can be provided.

↑ Back

Note 3 – Operative procedure - Axilla (Core)

The metastatic involvement of the axillary lymph nodes has specific clinical, treatment and prognostic implications. Nodal status post neoadjuvant treatment shows a strong association with overall and disease free survival,⁷ and is independent of response in the breast.

Accurate staging requires that all submitted lymph nodes be accurately designated by the surgeon.

Currently, in some countries (e.g., United States, Canada, Singapore, many European countries) an axillary lymph node dissection does not routinely include level III lymph nodes.

↑ Back

Note 4 – Specimen laterality (Core)

Specification of the side and site in the breast is important for clinical correlation and accuracy of the patient medical record.

For bilateral invasive breast tumours, a separate dataset should be completed for each side.

↑ Back

Note 5 – Tumour site (Core)

A clock face delineation and measure of distance from the nipple are a more accurate indicator of site than quadrant alone. Specification of the site in the breast is important for clinical correlation, post-operative management discussion and accuracy of the patient medical record, especially when there are multiple lesions for correlation with radiology/prior biopsies.

↑ Back

Note 6 – Tumour focality (Core and Non-core)

Presence of a single tumour focus is the most common clinical situation, but breast cancer can present with multiple tumour foci because of several scenarios (see ICCR Invasive carcinoma of the breast dataset²).

Identification of the presence of multiple tumour foci requires further clarification through measurement of the main foci, the overall extent of disease (DCIS and invasive foci) and their type, grade and receptor status to determine which of the forms of multifocality is present. Ipsilateral multifocal disease, even if of different types, should be dealt with in a single report.

If multiple tumour sites were present on pre-treatment imaging and/or multiple separate (macroscopically separate) tumour bed sites are present and the invasive carcinoma at these separate sites is distinct by tumour type, grade and/or receptor status then size and cellularity should be recorded for each of the tumours separately to evaluate response (TNM^{8,9} stage and RCB).

It can be difficult, if not impossible, on rare occasions to determine whether two adjacent foci represent satellite foci or one lesion. After neoadjuvant therapy, it is common for tumours that on pre-treatment imaging appeared to represent a single tumour to present as scattered foci of residual invasive carcinoma that are separated by areas of fibrosis in the post neoadjuvant therapy resection specimen, due to a heterogenous response to treatment. Union for International Cancer Control (UICC)⁸/American Joint Committee on Cancer (AJCC)⁹ staging and RCB address this scenario in different ways:

- UICC/AJCC staging considers this scenario as multiple foci irrespective of a pre-treatment finding of multiple foci or a single focus. The pathologist determines and measures the largest focus.
- RCB considers this scenario to be a single focus of scattered residual cancer. RCB considers multifocality only when the foci were clearly separate on pre-treatment imaging or clearly separate on gross examination (see **Note 8 TUMOUR DIMENSIONS**).

 [Back](#)

Note 7 – Residual invasive carcinoma (Core and Non-core)

The priority for evaluation of surgical specimens is different after neoadjuvant therapy, with emphasis on accurate identification of the pre-treatment tumour site to enable evaluation of tumour response to treatment. Pathologic complete response (pCR), defined as absence of residual invasive disease post neoadjuvant therapy, is associated with improved survival outcomes and forms the primary endpoint for neoadjuvant clinical trials, and identification of residual disease is important to guide future local and systemic adjuvant therapy decisions.⁶ Confident localisation of the pre-treatment tumour site and adequate, precise sampling are vital for accurate assessment of pCR.

Residual tumour is often less well defined following treatment, and close clinical-pathological correlation with careful mapping of the pre-treatment tumour site is essential for accurate microscopic assessment of response. It is strongly recommended that a visual record of the sliced specimen is made, and then used as a map of the sections taken to facilitate subsequent histological interpretation and clinical-radiologic-pathologic correlation; this may be in the form of radiographs, photographs, photocopies or drawings. It is helpful to indicate in the pathology report as a non-core element or in the gross description that such a map is available. The map can be stored in the

electronic medical record as a specimen image. It may also be helpful to indicate in the report which blocks correspond to the largest cross section of the residual invasive carcinoma. Use of large format 'Mega' blocks may be helpful in this regard.

In cases where there has been an excellent response to therapy there may be no grossly detectable residual tumour present. If there is no visible lesion, then careful palpation of the specimen slices looking for areas of firmness may also assist in identifying the pre-treatment tumour site.

Different types of fiducial markers should be inserted to indicate the site of the tumour prior to treatment; these include metallic clips of different shapes, gel foam clips, carbon pigment, and magnetic or radioactive seeds. Sometimes for large tumours, markers may be placed during the course of therapy when there is evidence of tumour response. If fiducial markers or surgical localisation markers have been inserted, they should be looked for in the surgical specimen. Clips or seeds may be seen macroscopically, but this is not always possible. As fiducial markers are designed to be identifiable on x-ray, specimen x-ray can be helpful to localise the fiducial markers and pre-treatment tumour site. If an intra-operative specimen x-ray has been carried out in the operating theatre the findings should be communicated to the pathologist. The presence of residual microcalcifications that were associated with the tumour pre-treatment may also be a radiographic guide to locating the pre-treatment tumour site. Guidewires or surgical markers (radioactive or magnetic seed or equivalent) may also be placed at the time of surgery to guide excision of the correct area, particularly if breast conservation surgery is attempted. The surgical marker may be placed at the site of the pre-treatment tumour site or residual tumour as identified radiologically, and/or at the site of a fiducial marker placed earlier. The presence of guidewires or surgical markers should be described as part of the gross assessment of the specimen, and helps identify the area on which to focus sampling.

Histological changes suggesting tumour was present may be seen at the pre-treatment tumour site after treatment and may include fibrosis, a characteristic pattern of vessels reminiscent of tumour vasculature, myxoid change, and infiltration by macrophages and/or lymphocytes ('microscopic tumour bed'). Sometimes macrophages are abundant and accompanied by extensive necrosis. The site of fiducial marker(s) is usually visible microscopically as they induce a foreign body type reaction which can be seen on histology. The presence of DCIS or calcification microscopically may also act as indicators of the pre-treatment tumour site.

When a small lumpectomy is performed with image guided targeting of the area of concern pre-treatment (the pre-treatment tumour site) then it is reasonable to presume the pre-treatment tumour site has been sampled by sampling the lumpectomy even when only non-specific histologic changes are seen.

All of the above approaches can help identify the location of the tumour pre-treatment (the pre-treatment tumour site); often several or all of them are used at the same time.

If the microscopic tumour bed or marked site are not identified on microscopy, then the specimen should be re-examined and further blocks may need to be taken. On occasion, there may be complete resolution of the tumour and histologic changes at the site may be nonspecific or subtle. In this setting it is worthwhile to make a comment in the report that the likely tumour site has been thoroughly sampled, or if there is uncertainty to indicate the uncertainty in the report so appropriate action can be taken. For example, if inadequate clinical information regarding the pre-treatment tumour site has been provided, this should be resolved or conveyed in the report.

 **Back**

Note 8 – Tumour dimensions (Core and Non-core)

The size of the tumour or of the largest/dominant invasive tumour focus is a key variable required for breast cancer staging and requires accurate assessment to the nearest mm. Histological tumour size is deemed the gold standard but should be correlated with the gross macroscopic size measurement and where possible with the imaging size. Detailed descriptions of how to measure invasive tumour size in specific scenarios, such as when there is extensive DCIS, is provided in the ICCR Invasive carcinoma of the breast dataset.¹

Determination of tumour dimensions after neoadjuvant therapy can be complicated due to tumour response to treatment and requires documenting the largest cross section of residual tumour with histologic sections. The dimensions of the residual invasive carcinoma are determined initially on gross examination and modified as needed after histologic evaluation. This requires correlating the histologic, macroscopic and imaging findings. Precise mapping with images of the sliced specimen, which can then be used as a map for the sections taken, facilitates subsequent histologic interpretation; this may be in the form of radiographs, photographs, photocopies or drawings. It can be useful to indicate in the report which blocks correspond to the largest cross section of residual tumour.

The final (histologic) tumour dimensions may be smaller or larger than initially suspected on gross evaluation, smaller or larger than the dimensions of the fibrotic (macroscopic or microscopic) tumour bed, smaller or larger than the dimensions on pre-treatment imaging and smaller or larger than the dimensions on Post-treatment imaging.

The approach to defining tumour dimensions in the 8th editions of TNM^{8,9} and the RCB (identical to the definitions used in prior TNM editions) can sometimes yield two distinct sets of tumour dimensions (TNM size and RCB area dimensions). Both TNM size and RCB area dimensions are core elements as TNM size is used for TNM^{8,9} staging and RCB area dimensions are used to determine RCB.

The size of the largest contiguous invasive tumour focus excluding intervening or adjacent fibrosis is required for breast cancer TNM^{8,9} staging and requires accurate assessment to the nearest mm. This measurement can be thought of as a single dimension intended to represent the volume of residual invasive cancer. In instances where it is difficult to determine what to consider the largest contiguous invasive focus, a description explaining how the measurement was determined provides useful documentation (see below). It is helpful to take into account the common growth patterns of breast carcinoma within breast tissue when determining what to consider the largest contiguous focus. For example, invasive lobular carcinoma tends to grow along fibrous tissue and commonly presents with satellite lesions. The satellite lesions would not be included in the TNM size. The growth along fibrous tissue would likely be considered in the TNM size by most observers even with some fibrous tissue between the cells. When residual invasive carcinoma cells are relatively evenly distributed over a fibrotic area then they are probably best considered a single focus. If the distribution of residual invasive carcinoma cells is more uneven it may be better representation to consider separate contiguous foci and to determine which is the largest. If residual invasive carcinoma cells are present in a pattern within normal breast tissue similar to one that is commonly seen in a single focus of invasive breast carcinoma without prior therapy, then they are probably best considered a single focus (Figure 1). The concept of multifocality within a single tumour bed in the ypT AJCC/UICC stage is different than the concept of multifocality in breast specimens without neoadjuvant treatment as discussed in Note 5 Tumour focality in the ICCR Invasive carcinoma of the breast dataset.² The considerations discussed in the ICCR Invasive carcinoma of the breast dataset² can help inform the interpretation of the post neoadjuvant findings.

For quantification of residual invasive carcinoma using RCB the largest cross sectional area of residual invasive carcinoma including intervening fibrosis is measured in two dimensions. Adjacent fibrosis and adjacent areas with DCIS only are not included in the measurements. In other words, the measurements are from invasive carcinoma cell to invasive carcinoma cell covering the entire extent of the invasive carcinoma within a single (fibrotic) tumour bed site. The measurements may extend beyond the area of fibrosis or be smaller than the area of fibrosis. This is the area in which the tumour cellularity is estimated (see **Note 9 TUMOUR CELLULARITY/COMPOSITION**).

In many instances, TNM size and the larger of the two RCB dimensions can be interpreted as the same. When they are different, both should be reported. A description explaining how the measurements were determined provides helpful documentation. For example: “Invasive carcinoma is present as multiple foci with varying cellularity in a single (fibrotic) tumour bed. The largest contiguous focus of invasive carcinoma is ... mm (size used for TNM^{8,9} staging). The largest cross section of the entire volume containing residual invasive carcinoma within the single residual primary tumour bed measures ...mm X ...mm (area used to determine RCB).” Adjacent necrosis and mucin without viable invasive carcinoma cells are not included in tumour size measurements for TNM^{8,9} staging and RCB.

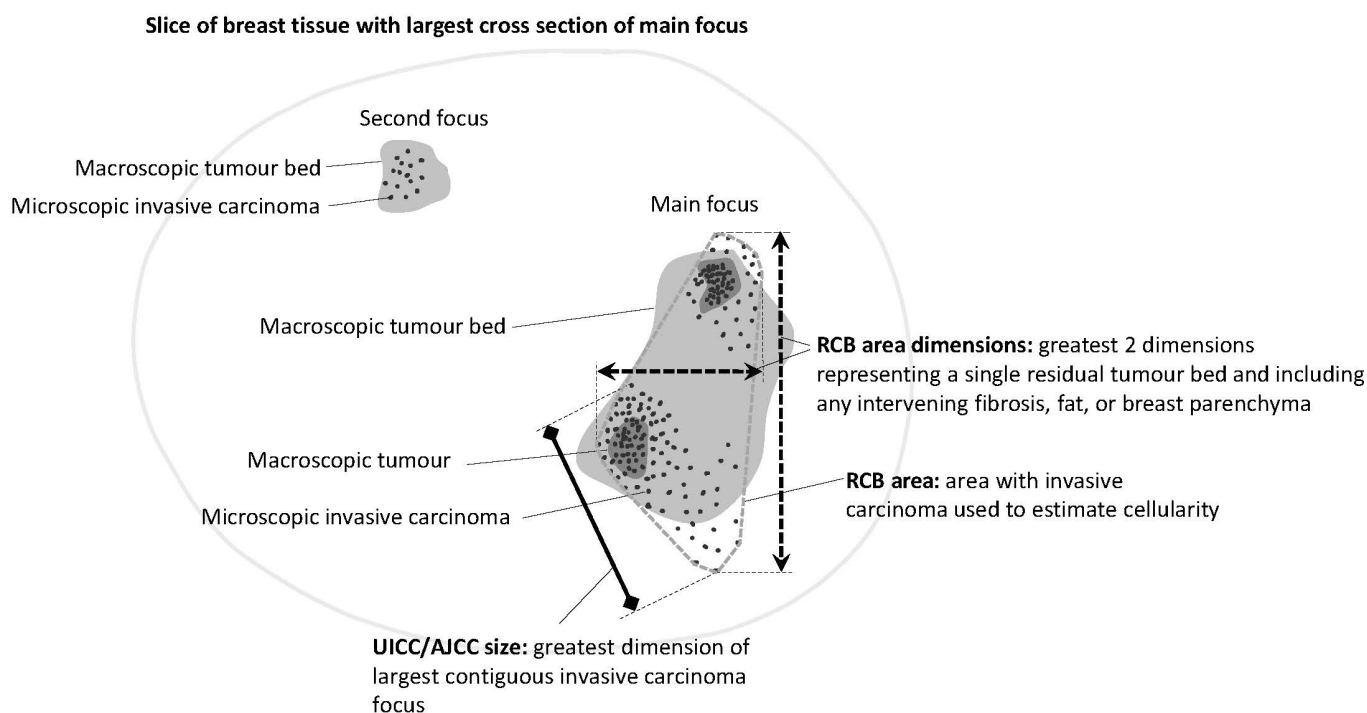


Figure 1: Invasive carcinoma measurement in post neoadjuvant treated excision specimen for UICC/AJCC pathological staging and Residual Cancer Burden (RCB) calculation. *Permission courtesy of Dr Veerle Bossuyt.*

↑ Back

Note 9 – Tumour cellularity/composition (Core and Non-core)

Tumour cellularity reduction compared to the pre-treatment biopsy correlates with survival.¹⁰ Tumour cellularity and size after neoadjuvant therapy provide independent prognostic information.^{11,12} The reduction in cellularity is often heterogeneous with varying cellularity across the residual invasive carcinoma and with areas of fibrosis without tumour cells separating islands of residual invasive disease. The RCB system addresses this heterogeneity by standardising sampling and estimating the average cellularity across the entire area of residual invasive carcinoma. Combining size and cellularity also dampens the effect of variations due to variable interpretation and sampling (see Figure 1). Sampling or interpretation may lead to a large tumour with low cellularity or a small tumour with high cellularity.

The objective of RCB measurement of the residual invasive cancer in the breast is to calculate the invasive cancer cellularity relative to the area containing residual invasive disease. It is typically easier to estimate the cellularity from two steps: 1) the percent of cancer in the area containing residual invasive cancer, then 2) the percent of the cancer component that is in situ (not invasive). The calculator for RCB then calculates the invasive component by area. Alternatively, some pathologists prefer to directly estimate the percent of invasive cancer in the area, and when using the RCB calculator they should enter zero for in situ component (even if there is some). It is recommended that the components of RCB also be reported together in a section of the report, as described in **Note 30 RESIDUAL CANCER BURDEN**.

Residual cancer burden (RCB) is the most validated prognostic factor for describing response to neoadjuvant chemotherapy in any subtype of breast cancer. The RCB standard operating procedure can be downloaded from the RCB calculator website at: http://www.mdanderson.org/breastcancer_RCB.¹³

There is emerging evidence that post-treatment lymphocytic infiltrate across the residual tumour bed has prognostic significance.^{14,15} Post-treatment assessment of the extent of TILs, either in association with residual invasive carcinoma or across the tumour bed when there has been a complete response, can be performed but is optional. The International TILs Working Group maintains a website with instructions and educational materials for assessing TILs in residual breast cancer at: <http://www.tilsinbreastcancer.org/>.

↑ Back

Note 10 – Histological tumour type (Core)

To ensure consensus and consistency of reporting, it is recommended to use the most recent edition of the World Health Organization (WHO) Classification of Breast Tumours, 5th edition, 2019, nomenclature and definitions for diagnosis and classification of invasive tumour type (Table 1).¹⁶ The ICCR dataset includes 5th edition Corrigenda, September 2020.¹⁷

Determination of histologic type is based on routine histologic examination; special stains such as e-cadherin are not required for determining histologic type. Pure special type carcinomas should consist of at least 90% pure pattern. Refer to the ICCR Invasive carcinoma of the breast dataset for more detail.²

After neoadjuvant therapy, it may be more difficult to accurately classify the tumour type due to cytopathic changes from treatment. For example, the morphology of an invasive breast carcinoma of no special type (NST) may appear more like that of a lobular carcinoma or a lobular carcinoma may appear more high grade suggesting the possibility of a ductal phenotype.¹⁸ In this instance pre-treatment tumour type should be regarded as more accurate.

The mucin pools of mucinous carcinoma tend to remain even after the invasive carcinoma cells have disappeared following neoadjuvant therapy. Size measurement after neoadjuvant therapy when this picture is present should be from tumour cell to tumour cell not including surrounding mucin. Thorough sampling of mucinous carcinoma with low cellularity after neoadjuvant therapy is needed. Mucin in the absence of viable tumour cells does not preclude classification as pCR.

Table 1: Detailed Invasive Tumour Classification based on 2019 World Health Organization classification of breast tumours subsections.¹⁶

Descriptor	ICD-O codes ^a
Invasive Type for Pure or Mixed (include all types present if >10%)	
Main categories:	
No Special Type (NST)	
Invasive breast carcinoma of no special type (see 'a' below)	8500/3
Special Types:	
Invasive lobular carcinoma (see 'b' below)	8520/3
Tubular carcinoma	8211/3
Invasive Cribriform carcinoma	8201/3
Mucinous carcinoma	8480/3
Invasive micropapillary carcinoma	8507/3
Carcinoma with apocrine differentiation	8401/3
Metaplastic carcinoma (see 'c' below)	8575/3
WHO 2019 classification additional sub categories (use 'Other, specify')	
a. NST special patterns	
None	8500/3
Present	
medullary	
neuroendocrine differentiation	
pleomorphic	
choriocarcinomatous	
melanocytic features	
oncocytic	8290/3
lipid-rich	8314/3
glycogen-rich	8315/3
clear cell	
sebaceous carcinomas	8410/3

Descriptor	ICD-O codes ^a
b. Lobular Sub-Type	8520/3
Classical	
Pleomorphic	
Solid	
Alveolar	
Tubulolobular	
Mixed sub-types	
c. Metaplastic carcinoma	8575/3
Low grade adenosquamous carcinoma	
Fibromatosis-like metaplastic carcinoma	
Squamous cell carcinoma	
Spindle cell carcinoma/myoepithelial carcinoma	
Metaplastic carcinoma with mesenchymal differentiation (chondroid, osseous, other types of mesenchymal differentiation)	
Mixed metaplastic carcinoma	
d. Salivary gland-type and other rare tumours	
Mucinous cystadenocarcinoma	8470/3
Acinic cell carcinoma	8550/3
Adenoid cystic carcinoma	8200/3
Secretory carcinoma	8502/3
Mucoepidermoid carcinoma	8430/3
Polymorphous adenocarcinoma	8525/3
Tall cell carcinoma with reversed polarity	8509/3
e. Invasive papillary carcinomas	
Solid papillary carcinoma - invasive	8509/3
Invasive papillary carcinoma	8503/3
f. Neuroendocrine neoplasms	
Neuroendocrine tumour	8240/3
Neuroendocrine carcinoma	8246/3
g. Epithelial-myoepithelial tumours	
Malignant adenomyoepithelioma	8562/3

^a These morphology codes are from the International Classification of Diseases for Oncology, third Edition, second revision (ICD-O-3.2).¹⁹ Behaviour is coded /0 for benign tumours; /1 for unspecified, borderline, or uncertain behaviour; /2 for carcinoma in situ and grade III intraepithelial neoplasia; /3 for malignant tumours, primary site; and /6 for malignant tumours, metastatic site. Incorporates all relevant changes from the 5th edition Corrigenda, September 2020.¹⁷

© World Health Organization/International Agency for Research on Cancer. Reproduced with permission.

 **Back**

Note 11 – Post-treatment histological tumour grade (Core and Non-core)

There is limited evidence that histological grading provides prognostic information after neoadjuvant therapy.²⁰⁻²² Post-therapy cytologic changes may be present and alter the grade.

All invasive breast carcinomas should be graded. Although histologic features impacting grading (tubules, nuclear atypia and mitotic rate) may be altered by treatment, grading after neoadjuvant treatment documents the histologic features after neoadjuvant therapy without taking pre-treatment features of the tumour into account. The amount of residual invasive carcinoma remaining may be too small to provide a grade. The Nottingham combined histologic grade (Elston-Ellis modification of Scarff-Bloom-Richardson grading system) is the recommended method.²³ There are no modifications to the method after neoadjuvant therapy. See Note 8 Histological tumour grade in the ICCR Invasive carcinoma of the breast dataset.²

 [Back](#)

Note 12 – Carcinoma in situ (Core and Non-core) and Classification of carcinoma in situ (Core and Non-core)

The presence of coexisting DCIS (and/or florid or pleomorphic LCIS) is commonplace with invasive carcinomas of the breast and forms part of the overall disease process which requires complete surgical excision to reduce the risk of local recurrence. In the context of extensive surrounding DCIS (and/or florid or pleomorphic LCIS), the total extent of the entire disease process including all invasive tumour foci and associated DCIS should be provided as the whole tumour size. (Note: The whole tumour size is different from the residual invasive carcinoma size used for RCB).

Classification of DCIS with respect to nuclear grade and architecture is dealt with in the companion DCIS, variants of LCIS and low grade lesions dataset.³ Post-treatment cytologic changes may be present and alter the grade and appearance of the DCIS.

It has been controversial whether residual DCIS after neoadjuvant therapy affects prognosis when residual invasive cancer is not identified.²⁴ In that circumstance the pathologist should be mindful to consider whether the sampling of tumour bed has been sufficient to exclude invasive disease (particularly important if calcifications were targeted) and lymphovascular invasion (LVI). The definition of pCR used may or may not include the absence of DCIS. It is helpful to document the definition of pCR used (ypT0/ypTis ypN0 or ypT0 ypN0). ypTis ypN0 has an excellent prognosis.

 [Back](#)

Note 13 – Tumour extension (Core)

Tumour extension to involve overlying skin or underlying skeletal muscle is a variable which influences TNM staging and should be recorded when present. It is recognised that in the context of primary operable breast cancer these phenomena are rare. The majority of cancer resection cases will be confined to the breast with no skin, nipple or underlying skeletal muscle involvement and in this context disease extent classification is deemed non-core.

Satellite skin nodules must be separate from the primary tumour and macroscopically identified to assign a category as T4b. Skin nodules identified only on microscopic examination and in the absence of epidermal ulceration or skin oedema (clinical peau d'orange) do not qualify as T4b. Such tumours should be categorised based on tumour size. If a cancer was classified as inflammatory (cT4d) before neoadjuvant chemotherapy, the cancer is still classified as inflammatory breast cancer after therapy, even if complete resolution of the inflammatory findings is observed during treatment. The post-treatment pathological classification (ypT) should reflect the extent of identified residual disease, and the pathology report should note that the pre-treatment classification was cT4d.

The finding of invasive carcinoma that directly invades into the dermis or epidermis without skin ulceration does not change the pT stage.

The finding of tumour extension into the nipple does not change the pT classification of invasive carcinomas.

Invasion into pectoralis muscle is not considered chest wall invasion, and cancers are not classified as pT4a unless there is invasion deeper than this muscle.

↑ Back

Note 14 – Margin status (Core and Non-core)

There is an assumption that all breast tissue will be resected in patients undergoing a complete mastectomy and that pathological examination of margins is of limited value. However, there is evidence that margin involvement can increase the risk of local recurrence after mastectomy and modification of the comprehensive margin analysis and reporting recommendations for wide local excision and other similar specimens is adopted for reporting of mastectomy specimens to include a statement of the distance to the closest margin or site of margin involvement.

Assessment of adequacy of excision requires close correlation between the surgical excision procedure and pathological examination. In particular it is essential that the pathologist is made aware of the depth of tissue excised and whether the surgeon has excised all the tissue from the subcutis to the pectoral fascia. Similarly, it has been recognised that involvement of a margin, particularly the posterior margin in a mastectomy specimen, should also be described as this could result in a recommendation for further surgery or radiotherapy.

There remains some controversy regarding the minimum width of uninvolved tissue that defines 'complete' excision, although narrower margins are now more widely accepted as adequate than previously. For this reason, it is recommended that the pathologist reports the measurement to the inked margins of DCIS and invasive carcinoma rather than quoting 'complete' excision or 'not at ink' in histology reports.

Some centres find it helpful to report the approximate extent of margin involvement. The following system is recommended - this is considered a non-core feature:

- Unifocal: one focal area of carcinoma at the margin, <5 mm
- Multifocal: two or more foci of carcinoma at the margin
- Extensive: carcinoma present at the margin over a broad front (≥5 mm).

The presence of microscopically identifiable tumour bed at the margin may be documented in a note in the report and is optional. On a rare occasion if the tumour has a heterogenous pattern of

response with scattered invasive carcinoma cells in an area of fibrosis the pathologist may be concerned that a significant amount of residual invasive carcinoma may have been left behind because there is fibrosis at the margin, with fibrosis with scattered invasive carcinoma cells close to the margin and no invasive carcinoma at the margin. However, it is important to remember that surgical resection of the entirety of the tissue involved by the tumour pre-treatment is not necessarily performed after neoadjuvant therapy. As such tumour bed that may or may not be identifiable is present at the margin in many specimens after neoadjuvant therapy. The significance of identifiable tumour bed at the margin in the absence of invasive carcinoma at the margin is unclear. Re-excision is usually not performed when identifiable tumour bed is present at the margin in the absence of invasive carcinoma at the margin.

↑ Back

Note 15 – Lymphovascular invasion (Core and Non-core)

The presence of lymphovascular invasion (LVI) is an adverse feature providing independent prognostic information about both local recurrence and survival. Reporting the LVI status for stage IIA and IIB patients who have an axillary lymph node dissection may also influence the use of radiotherapy.

Recognition of LVI may be challenging (see Note 12 Lymphovascular invasion in primary breast carcinoma in the ICCR Invasive carcinoma of the breast dataset²).

On occasion, residual invasive carcinoma after neoadjuvant therapy is present as LVI only. This is not considered pCR. This finding should prompt careful re-evaluation of the gross specimen and lymph nodes to ensure appropriate sampling of the correct area and that residual invasive carcinoma or lymph node metastasis was not missed. ypT0 category is assigned with a comment emphasising this is not pCR. For the purposes of calculating the RCB, if there is no other residual invasive cancer, then the extent of the LVI should be estimated in two dimensions and its cellularity estimated relative to this area.

Only LVI identified in breast tissue at the tumour site should be recorded. LVI identified elsewhere, for example in axillary tissue, may be described but not recorded formally as LVI positive. Documenting the presence of dermal LVI is valuable because of its strong association with the clinical findings of inflammatory breast carcinoma. As with LVI only in the breast, LVI at other sites such as dermis or axilla when present without residual invasive carcinoma elsewhere should not be classified as pCR. Perineural invasion should not be recorded as LVI.

↑ Back

Note 16 – Coexistent pathology (Non-core)

In some situations, inclusion of coexisting conditions can be considered beneficial if this supports clinico-pathological correlation or patient management. Examples include microcalcification detected mammographically and extension into or involvement of a benign lesion such as a sclerosing lesion, papillary lesion or fibroepithelial lesion.

An exhaustive description of all coexisting conditions is not required.

↑ Back

Note 17 – Microcalcifications (Non-core)

The presence of microcalcifications may help to locate the pre-treatment tumour site with or without the presence of residual invasive carcinoma. Note that calcifications from the original primary cancer usually persist after treatment and should be sampled for microscopic evaluation, but the calcifications may represent the prior DCIS and residual invasive cancer can be present as less obvious tissue density or distortion in the post-treatment breast.

↑ Back

Note 18 – Post-treatment estrogen receptor (ER) (Core and Non-core)

Hormone receptor status should be performed on pre-treatment core biopsy. Depending on the resources available it may be repeated after neoadjuvant therapy, although routine retesting of receptor status in residual disease is not currently advocated. Repeat testing can be considered if abundant residual disease is present in the breast or lymph nodes. Repeat testing is also indicated if tumour foci show morphology suggesting a different breast cancer subtype than was present in the pre-treatment core biopsy.

Change in estrogen receptor (ER) status post neoadjuvant chemotherapy has been reported in up to 47% of patients, with a meta-analysis identifying a change in ER status in 13-18% of cases.^{25,26} This can be from positive to negative, or negative to positive. The significance of a change in ER status for survival outcomes and clinical management is less certain. Some series have suggested improved survival outcomes with endocrine therapy in patients that revert from ER negative to ER positive disease.²⁷

If the pre-operative endocrine prognostic index (PEPI) index is being measured for response to neoadjuvant endocrine therapy, then ER immunohistochemistry (IHC) and Ki-67 IHC of the residual primary tumour need to be performed and recorded.^{28,29}

When a tumour is negative but no internal control cells are present, the pathologist must exercise judgment as to whether the assay can be interpreted as a true negative. If there is doubt then a recommendation to repeat on another block or specimen that contains internal controls should be made.

‘Cannot be determined’ is used when any issue prevents reliable interpretation of the result. This can include suboptimal specimen handling, presence of artefacts (crush or edge artefacts) making interpretation difficult, or if the analytical testing procedure failed.

See also Note 15 Estrogen receptor in the ICCR Invasive carcinoma of the breast dataset.²

↑ Back

Note 19 – Post-treatment progesterone receptor (PR) (Core and Non-core)

Change in progesterone receptor (PR) status post neoadjuvant chemotherapy is seen more frequently than changes in ER status, perhaps reflecting changes in ER signalling, with a meta-analysis identifying a change in PR status in 26-32% of cases.^{25,26} This can be from positive to negative, or negative to positive. The significance of a change in PR status for survival outcomes and clinical management is even less certain than for ER.

When a tumour is negative but no internal control cells are present, the pathologist must exercise judgment as to whether the assay can be interpreted as a true negative. If there is doubt then a recommendation to repeat on another block or specimen that contains internal controls should be made.

‘Cannot be determined’ is used when any issue prevents reliable interpretation of the result. This can include suboptimal specimen handling, presence of artefacts (crush or edge artefacts) making interpretation difficult, or if the analytical testing procedure failed.

See also **Note 18 POST-TREATMENT ESTROGEN RECEPTOR** and Note 15 Estrogen receptor and Note 16 Progesterone receptor in the ICCR Invasive carcinoma of the breast dataset.²

 **Back**

Note 20 – Post-treatment HER2 (Core and Non-core)

HER2 status should be performed on pre-treatment core biopsy. Depending on the resources available it may be repeated after neoadjuvant therapy, although routine retesting of receptor status in residual disease is not currently advocated. Repeat testing can be considered if abundant residual disease is present in the breast or lymph nodes. Repeat testing is also indicated if tumour foci show morphology suggesting a different breast cancer subtype than was present in the pre-treatment core biopsy.

Changes in HER2 status are less frequent than changes in hormone receptor status. A large population based series from Japan identified a change in HER2 status on IHC in 20% of cases, but only 8% showed a change with HER2 FISH.³⁰ Conversion from HER2 positive to HER2 negative status is more common than negative to positive. Persistence of a HER2 negative clone post neoadjuvant therapy with chemotherapy plus HER2 targeted agents occurs in approximately one third of cases, and is associated with worse survival outcomes.³¹

‘Cannot be determined’ is used when any issue prevents reliable interpretation of the result. This can include suboptimal specimen handling, presence of artefacts (crush or edge artefacts) making interpretation difficult, or if the analytical testing procedure failed.

See also Note 17 HER2 in the ICCR Invasive carcinoma of the breast dataset.²

 **Back**

Note 21 – Post-treatment ancillary studies (Non-core)

Primary tumour

The results of any additional ancillary studies such as multigene test results when performed are recommended to be included or added subsequently to the pathology report to ensure a record of all assays performed on the case in a single comprehensive report.

The information on Ki-67 expression after therapy is distinct from the information on the core biopsy. Suppression of proliferation has been shown to be associated with response to neoadjuvant chemotherapy and improved survival.^{32,33}

A decrease in Ki-67 following two weeks of neoadjuvant endocrine therapy has been associated with endocrine responsiveness and improved survival in window studies of anti-estrogen therapy.^{29,34,35} Decreased Ki-67 occurs in most tumours treated with a cdk4/6 inhibitor of cell cycle entry in combination with neoadjuvant endocrine therapy, and currently there is uncertainty about what that means.

If the PEPI index is being measured for response to neoadjuvant endocrine therapy, then ER IHC and Ki-67 IHC of the residual primary tumour need to be performed and recorded.^{28,29}

See also Note 18 Ancillary studies in the ICCR Invasive carcinoma of the breast dataset for additional information on Ki-67 proliferation index.²

Lymph nodes

Immunohistochemistry (IHC)

The routine use of keratin IHC assays to evaluate lymph nodes obtained post neoadjuvant treatment with no evidence of carcinoma in haematoxylin and eosin (H&E)-stained sections is not routinely recommended. However, keratin IHC can be useful to evaluate suspicious cells identified in H&E-stained sections. The identification of tumour cells in lymph nodes obtained post neoadjuvant treatment using IHC for keratins was not associated with significantly worse prognosis in a retrospective study.³⁶ Tumour cells should be classified in the same way regardless of the method of detection with or without IHC.

Molecular techniques

The RD-100i OSNA system is a commercially available RT-PCR assay for the detection of mRNA (CK19) associated with breast carcinoma. It is used to infer the presence of epithelial cells in the lymph nodes and estimate the volume of disease.³⁷ OSNA is calibrated in a way to virtually ignore ITCs but to detect micrometastases/macrometastases.

The RD-100i OSNA system (see ICCR Surgically removed lymph nodes for breast tumours dataset⁴) is not currently recommended in the post neoadjuvant chemotherapy setting. It is not calibrated to detect ITCs, which have prognostic significance post neoadjuvant therapy and the presence of which is not regarded as pCR. It is not possible to assess the presence of histological changes such as fibrosis or necrosis that indicate response to chemotherapy, and are associated with improved prognosis. Finally, it is not possible to provide a measurement for the size of the largest metastasis which means the RCB cannot be determined.

↑ Back

Note 22 – Number of lymph nodes examined (Core)

For axillary staging purpose at least one sentinel node is required in patients who received neoadjuvant treatment and were clinically node negative (cN0) pre-treatment.

In patients with cT1-T2 cN1 disease with clinical and imaging resolution of lymph node positivity after completion of neoadjuvant treatment, based on the results of three separate clinical trials,³⁸⁻⁴⁰ evaluation of at least three sentinel lymph nodes identified with dual tracer technique or removal of the biopsied node as identified by a fiducial marker, is associated with a false negative sentinel lymph node rate of less than 10%.

If a fiducial marker clip has been placed in a biopsied node pre-treatment then it is important for the pathologists to be aware of this at the time of initial sampling of the specimen (sometimes at the frozen section bench) so the pathologist can look for the fiducial marker. Specimen x-ray may help localise the fiducial marker. If an intra-operative specimen x-ray has been carried out in the operating theatre the findings should be communicated to the pathologist. A comment should be made in the pathology report stating whether the fiducial marker was identified and its location (in a sentinel or a non-sentinel node which was positive or negative for carcinoma). Fiducial marker clips or carbon pigment can induce a florid foreign body reaction which can make histological interpretation more difficult, especially if frozen section is performed, and which should not be interpreted as treatment effect.

 **Back**

Note 23 – Number of lymph nodes with metastatic carcinoma (Core)

The number of lymph nodes containing metastatic carcinoma post neoadjuvant therapy is an important prognostic factor and shows a strong association with disease free and overall survival, independent of the presence of residual tumour in the breast. Any carcinoma cells in the lymph node should be regarded as residual disease. The presence of low burden of residual disease in the lymph nodes (isolated tumour cells (ITC) or micrometastases) represents a very different finding after neoadjuvant therapy than without prior therapy. Both the presence of micrometastases and of ITCs has significant prognostic implications (see **Note 25 NUMBER OF LYMPH NODES WITH ISOLATED TUMOUR CELLS**).

The number of lymph nodes with metastatic carcinoma excluding ITCs is used for ypN classification (see **Note 31 PATHOLOGICAL STAGING**).

The number of lymph nodes with carcinoma including the number of lymph nodes with ITCs is used for calculation of RCB.

According to College of American Pathologists (CAP) guidelines, ITCs post neoadjuvant chemotherapy are not counted as positive nodes.⁴¹ However, the presence of ITCs needs to be recorded as these patients are not regarded as having a pCR.^{8,9}

According to The Royal College of Pathologists (RCPath) guidelines, ITCs post neoadjuvant chemotherapy are regarded as node positive and included in the number of lymph nodes with metastatic carcinoma.⁴²

 **Back**

Note 24 – Number of lymph nodes with micrometastases (Non-core)

The number of lymph nodes containing metastatic carcinoma post neoadjuvant therapy is an important prognostic factor and shows a strong association with disease free and overall survival, independent of the presence of residual tumour in the breast. Any carcinoma cells in the lymph node should be regarded as residual disease. The presence of low burden of residual disease in the lymph nodes (ITCs or micrometastases) represents a very different finding after neoadjuvant therapy than without prior therapy. Both the presence of micro-metastases and of ITCs has significant prognostic implications.

The number of micrometastatic lymph nodes is added to the number of macrometastatic lymph nodes, provided that there is at least one lymph node with macrometastasis to derive the pN category.

If no macrometastasis is present, the number of micrometastatic lymph nodes (provided there is at least one) does not alter the pN1mi category, but may still reflect prognostic information.

The number of lymph nodes with metastatic carcinoma excluding ITCs is used for ypN classification (see **Note 31 PATHOLOGICAL STAGING**).

↑ Back

Note 25 – Number of lymph nodes with isolated tumour cells (ITCs) (Core and Non-core)

Isolated tumour cell (ITC) clusters are single tumour cells or small clusters of carcinoma spanning less than or equal to 0.2 mm in greatest dimension or adding to less than or equal to 200 cells in a single histological cross section. ITCs can be detected by routine H&E stains or IHC but should be verified in H&E-stained slides. Currently ITCs are not classified as metastatic deposits for the purposes of staging. If only ITCs are identified in lymph nodes, the ypN classification is ypN0(i+).

Post neoadjuvant chemotherapy ITCs can occur in two contexts. There can be scattered single cells lying within a background of post-treatment changes such as fibrosis suggestive of previous gross metastatic disease that has partially responded to therapy, or there can be scattered single cells or small clusters within lymph node parenchyma with no evidence of treatment related changes. Both these scenarios represent residual viable tumour that is treatment resistant, and in the post neoadjuvant setting, the presence of ITCs (ypN0(i+) category) excludes pCR.

In contrast to the adjuvant setting, it is currently advised that presence of ITCs in sentinel lymph nodes post neoadjuvant therapy should result in further axillary treatment with either completion axillary dissection or axillary radiotherapy. In the SN FNAC trial, when nodes containing ITCs were regarded as node positive, the false negative rate for sentinel lymph node biopsy fell from 13% to 8%.³⁹

According to CAP guidelines, nodes containing only ITCs are excluded from the total positive node count for purposes of ypN classification but should be included in the total number of nodes evaluated.⁴¹

For calculation of the RCB lymph nodes with ITCs post-neoadjuvant chemotherapy, with or without treatment related changes, are regarded as node positive and included in the number of lymph nodes with metastatic carcinoma. Lymph nodes with ITCs are also regarded as positive in some national guidelines, for example RCPATH guidelines.⁴²

↑ Back

Note 26 – Size of largest metastasis (Core)

The size of the largest metastasis is a strong predictor of disease free and overall survival post neoadjuvant chemotherapy,⁴³ and it is one of the variables used to calculate the RCB.¹²

Measuring the size of the largest metastatic deposit can be very challenging post neoadjuvant chemotherapy. The measurement of residual carcinoma in the post neoadjuvant therapy setting is a subject of debate and varies in different classification systems. According to the AJCC 8th edition Staging System, only the size of the largest contiguous focus of residual carcinoma present in the lymph nodes is used for lymph node classification.⁹ Treatment-induced fibrosis between adjacent foci of residual carcinoma is not included in the size measurement.^{9,41,44} In other regions such as the United Kingdom, Ireland, Australasian and South-East Asian countries, the size includes foci of residual viable carcinoma with intervening treatment-induced stromal fibrosis. This second measurement (largest metastatic extent measured from tumour cell to tumour cell including intervening fibrosis and extracapsular extension 'RCB size', 'largest lymph node metastasis') is also the measurement used to determine RCB (see Figure 2).

If there are clearly separate foci within a node with intervening nodal tissue, then these should be measured as distinct foci and the largest single focus used as the size of the largest metastatic deposit.

Lymph node

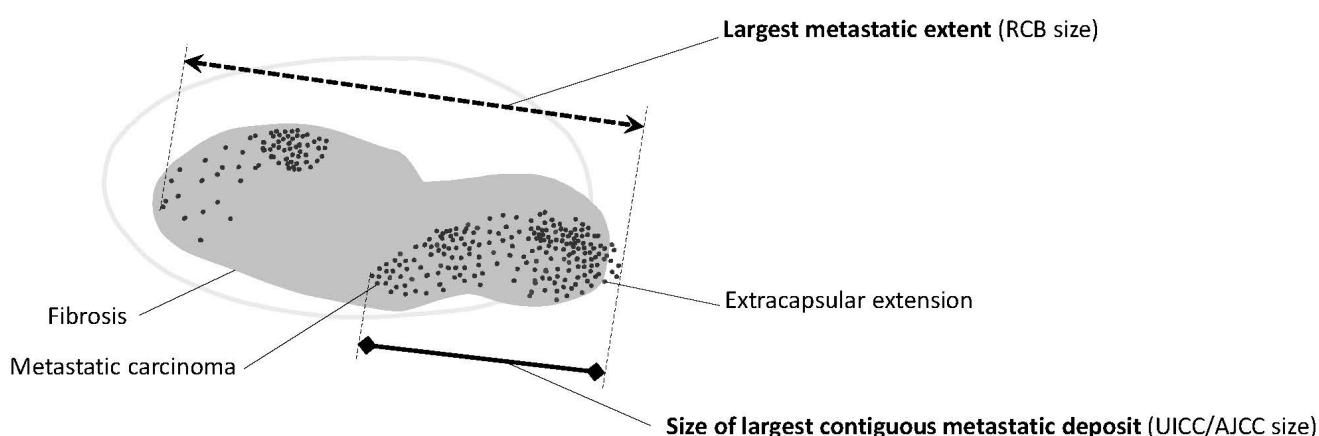


Figure 2: Measurement of largest metastatic deposit in post neoadjuvant treated lymph nodes for UICC/AJCC pathological staging and Residual Cancer Burden (RCB) calculation. *Permission courtesy of Dr Veerle Bossuyt.*

↑ Back

Note 27 – Extranodal extension (Core)

Extranodal extension (ENE) may be grossly visible (matted lymph nodes) but is most often a microscopic finding. In studies which looked at the effect of ENE on prognosis and overall nodal burden when ENE was present only in sentinel lymph nodes, ENE was only included as a qualitative variable i.e., present or absent.⁴⁵⁻⁴⁸ There is no firm evidence to recommend further quantifying ENE at this stage.

Extranodal extension (ENE) is included in the size of the largest lymph node metastasis for the purpose of calculating RCB.

↑ Back

Note 28 – Treatment effect (Non-core)

Treatment effect is best reported separately for lymph nodes with residual carcinoma (A) and for lymph nodes without residual carcinoma (B).

Treatment effect is defined as areas of scarring, hyalinization, necrosis, mucoid or myxoid change in the lymph node (akin to tumour bed in the breast specimen), and/or the presence/absence of cellular alterations in the residual carcinoma attributable to the neoadjuvant treatment. Reporting of treatment effect in lymph nodes is strongly encouraged, as it may act as an indicator of the extent of lymph node involvement before neoadjuvant treatment, and of the tumour response to treatment. However, interpretation of fibrosis in nodes can be very subjective, and areas of fibrosis may be seen in lymph nodes in the adjuvant setting. Caution must be taken not to over interpret biopsy site changes and small amounts of fibrosis, particularly capsular fibrosis, as evidence of previous metastatic disease. If there is variable response between nodes then this should be commented on in the report. The number of lymph nodes showing changes suggestive of treatment effect without the presence of residual tumour cells may be an indicator of pre-treatment nodal burden, and may be used in decision making regarding the need for adjuvant radiotherapy.

↑ Back

Note 29 – Pathologic complete response (pCR) (Core)

Pathologic complete response (pCR) is now defined as no invasive disease in the breast (ypT0/ypTis or ypT0) and no disease in all sampled lymph nodes (ypN0). An international effort tried to standardise the definition and aspects of clinical practice and pathologic evaluation that impact the determination of pCR.^{49,50} Fiducial marker placement to mark the primary tumour site prior to initiating therapy is very important. To improve the accuracy of sentinel lymph node biopsy the placement of a clip in involved lymph nodes is also recommended. Appropriate handling of the pathology specimen is critical (see **Appendix 1: General information - Specimen handling post neoadjuvant treatment** section). Directed sampling with identification of the tumour site is needed to accurately determine the pCR status.

Absence of disease in all sampled lymph nodes, including absence of ITCs, is required for pCR. LVI only associated with the primary tumour or elsewhere (for example, dermal LVI or in the axilla) is not

considered pCR. The presence of in situ carcinoma, lobular neoplasia, necrotic tumour and mucin in the absence of viable disease do not preclude classification as pCR.

It is unclear if residual DCIS after neoadjuvant therapy affects prognosis. The definition of pCR used may or may not include the absence of DCIS. It is helpful to document the definition of pCR used (ypT0/ypTis ypN0 or ypT0 ypN0). ypTis ypN0 has an excellent prognosis.

↑ **Back**

Note 30 – Residual cancer burden (RCB) (Core)

Multivariable response predictors combine individual prognostic elements. The RCB index combines residual carcinoma in the breast (tumour size and cellularity) and in the lymph nodes (number of lymph nodes with carcinoma and extent of largest lymph node metastasis) into a single continuous RCB score that can be divided into RCB class 0 corresponding to pCR, RCB I minimal residual disease, RCB II moderate residual disease, and RCB III extensive residual disease. After neoadjuvant chemotherapy (with anti-HER2 therapy when applicable) the RCB score and classes are prognostic overall, within AJCC anatomic stage groups⁹ and within breast cancer subtypes (triple negative, HR+ HER2-, HR+ HER2+, and HR- HER2+). RCB was originally described in 2007.¹² A standard operating procedure (SOP), teaching materials and a calculator are freely available at: http://www.mdanderson.org/breastcancer_RCB.¹³ RCB is widely used in a variety of settings and is reproducible.^{12,51,52} A recent pooled meta-analysis including over 5,000 patients confirmed that RCB score and classes were independently and strongly prognostic in all breast cancer subtypes.⁵³ The AJCC 8th edition Staging System⁹ recommends adding additional descriptions to staging, such as the number of foci, total area of involvement, RCB, etc. AJCC stage and RCB provide complementary information.

Residual cancer burden (RCB) score and class can be included in the pathology report. For best results it is important to follow the SOP including appropriate sampling of the tumour bed and to use uniform definitions for the elements as explained in the SOP and this dataset. It is preferable if the pathologist interpreting the RCB can also report the calculated result. It is also helpful to provide the core elements used to calculate RCB when RCB class and score are reported. If the RCB score is not calculated, then the required information should be provided and formatted in the report such that any member of the clinical team reading the report would exactly enter the correct information and obtain the correct result from the calculator, as this facilitates calculation of RCB at a later date by the clinical team or when access to the online calculator is not available at the site of reporting.

Combining the core prognostic elements from the surgical specimen into a single score with corresponding prognosis improves reproducibility by dampening the effects of variable results of individual elements due to differences in interpretation or sampling (for example, if there are multiple foci of invasive carcinoma in an area of fibrosis this would give a large tumour with low cellularity if they are interpreted as a single tumour or a small tumour with high cellularity if only the largest individual focus is assessed (see Figure 1, **Note 8 TUMOUR DIMENSIONS**), and facilitates interpretation, comparisons, and clinical decisions. Other factors such as pre-treatment burden of disease and tumour biology may also be important predictors of prognosis in a given situation.

When multiple separate lesions are present the one with the greatest burden of residual disease determines RCB. This is often the largest lesion. It is useful to also calculate the RCB score for the smaller lesions if they are more cellular and may yield a higher RCB score. If the separate invasive carcinomas are distinct by tumour type, grade and/or receptor status then RCB should be reported

for each. For example, after neoadjuvant therapy with chemotherapy and anti-HER2 therapy in a patient with a synchronous HER2 positive tumour and HR positive HER2 negative tumour response in both tumours is expected to be different. RCB is expected to be prognostic in both tumours. In particular, the response in the HER2 positive tumour will determine the need to escalate subsequent therapy.

Residual cancer burden (RCB) cannot be reliably calculated if the positive lymph nodes were removed prior to neoadjuvant therapy as the number of lymph nodes with carcinoma and the extent of the largest lymph node metastasis are needed. Areas of fibrosis and extracapsular extension are included in the measurement. The 'RCB size of the largest lymph node metastasis' may be different from the size used to determine AJCC⁹ N categories. For ITCs, a number <1 can be entered for the extent of the largest lymph node metastasis. The number of involved nodes used to calculate RCB includes the number of lymph nodes with macrometastases, micrometastases and ITCs. Involved internal mammary lymph nodes are included in the lymph node count to calculate RCB.

At this time, pathology response endpoints following neoadjuvant endocrine therapy are insufficiently validated to be considered as core elements. The PEPI is recommended as a non-core element when reporting response from neoadjuvant endocrine therapy. PEPI has not been extensively validated for prognosis, but the results to date with PEPI are promising and it combines parameters that have known prognostic information: tumour size, involved nodes, proliferative suppression, and persistence of ER positive status of the residual invasive cancer.

Residual cancer burden (RCB) and yp stage (UICC⁸/AJCC⁹ TNM) were not designed for prognosis after neoadjuvant endocrine therapy, and their prognostic value has not been demonstrated in this setting. It is already clear that patients with ER positive disease who achieve a low RCB or ypStage from chemotherapy-based treatment will have an excellent prognosis with adjuvant endocrine therapy. However it remains unproven whether achieving that same response with neoadjuvant endocrine therapy would impart the same excellent prognosis with continued adjuvant endocrine therapy as there are currently no data. The elements to determine RCB and the RCB score can still be used to describe the findings in the surgical specimen post neoadjuvant endocrine therapy but it would be prudent to add a note to the report that the prognostic value of RCB score and class has not been demonstrated in the setting of neoadjuvant endocrine therapy.

There are insufficient data to support specific prognostic tools as core elements for other types of neoadjuvant therapy. However, the elements in this dataset are reasonable to describe the pathological findings in these more unusual or investigational treatment settings.

 [Back](#)

Note 31 – Pathological staging (Core)

The Tumour Node Metastasis (TNM) system of the UICC is recommended.⁸ In the UICC TNM Staging System,⁸ breast cancer staging can be done for primary untreated disease, breast cancer treated with primary systemic therapies or in the recurrent setting. To distinguish between these, the symbols of categorisation are added before the tumour and nodal categories. For uniform use, the order of these categories is advised to be y – r – p or c (if none of these latter two are given, this is synonymous with c).

Pathologic Classification

Classification of T, N, and M by pathology examination of a post-treatment specimen is denoted by use of a lower case 'yp' prefix (ypT, ypN, ypM).

Pathological T (ypT): Histological assessment of the primary tumour (pT) generally is based on the largest contiguous invasive tumour focus without intervening areas of fibrosis (see **Note 8 TUMOUR DIMENSIONS** section for methodology details). These dimensions may be different than the dimensions used for RCB.

The suffix 'm' indicates the presence of multiple primary tumours (see **Note 6 TUMOUR FOCALITY**) in a single site and is recorded in parentheses, e.g., ypT(m) NM.

Breast cancer staging involves the inclusion of the nodal status according to the ypN categories as defined above. Nodal stage post neoadjuvant therapy has been shown to correlate with survival outcomes, and is important for cancer registry purposes to monitor the population demographics of breast cancer.

The number of lymph nodes with metastases for UICC⁸/AJCC⁹ staging includes the number of lymph nodes with macrometastases and with micrometastases provided one macrometastasis is present. The number of lymph nodes with metastases used for UICC⁸/AJCC⁹ staging may be different than the number used to calculate RCB as for calculating the RCB the number of lymph nodes with ITCs and micrometastases are also included regardless of the presence of a lymph node with macrometastases.

 [Back](#)

Appendix 1: General information

There has been an increase in the use of neoadjuvant chemotherapy in recent times that has been driven by greater access to effective treatments, desire for breast conservation, and most recently clinical desire to learn prognostic information from the response of a patient's disease to the treatment given which may increasingly guide further therapy. The recommended prognostic tools are multivariable, and so combine individual data elements from pathology evaluation. Certainly, it is now core information for there to be accurate determination of whether pCR has been achieved and to provide accurate prognostic information if there is residual disease. To this end, the RCB method is the most validated prognostic tool for patients with residual disease after neoadjuvant chemotherapy-based treatments for any subtype of breast cancer. Results from a multinational pooled analysis of RCB in over 5,000 subjects were recently reported⁵⁴ and have now established sufficient level of evidence to include reporting of RCB as core elements in addition to UICC⁸/AJCC⁹ ypTNM stage.

Neoadjuvant endocrine therapy is sometimes given instead of chemotherapy, but pCR is a rare outcome. A brief pre-operative exposure to endocrine therapy (for example, because of a delay in surgery) is not considered neoadjuvant therapy. At this time, pathology response endpoints following neoadjuvant endocrine therapy are insufficiently validated to be considered as core elements, but the PEPI is recommended as a non-core element when reporting response from neoadjuvant endocrine therapy. PEPI has limited validation for prognosis and combines parameters that have known prognostic information: tumour size, involved nodes, proliferative suppression, and persistence of ER positive status of the residual invasive cancer. Although there are insufficient data to support specific prognostic tools as core elements for neoadjuvant endocrine therapy when

combined with other targeted therapy, immunotherapy, radiotherapy, or other novel treatments, it is reasonable to use this dataset to document pathology information that would be relevant for any type of neoadjuvant therapy, even if investigational treatment. Biological indicators might be differently affected by molecular treatments, however the estimation of extent and pathology of residual disease is generally relevant.

Data entered into this dataset represent the findings in the surgical specimen after neoadjuvant therapy. To emphasise this, the modifier 'post-treatment' is added to several elements (Histological tumour grade, ER, PR, HER2 and Ancillary studies). When no residual invasive carcinoma is present then the remaining elements pertaining to residual invasive carcinoma (Tumour dimensions, Tumour cellularity/composition, Histological tumour type, Post-treatment histological tumour grade, Tumour extension, Margin status, Post-treatment ER, Post-treatment PR, Post-treatment HER2 and Post-treatment ancillary studies) are removed from the report. These elements should not be populated with information from the prior core biopsy.

Specimen handling post neoadjuvant treatment

The objective is to document the extent of residual invasive carcinoma or accurately confirm complete response. Because residual carcinoma may be indistinct, we use all the knowledge available to us from imaging, radiological clips, markers, gross appearance and palpation to guide sampling for histology. Therefore, it is important to have a visual map of the sections of the gross specimen so that the extent of histologically confirmed invasive residual carcinoma can be measured in the resected specimen. The grossly fibrotic lesion may or may not represent the extent of the residual invasive carcinoma, but it is the extent of residual invasive carcinoma that is the most important to measure.

Detailed specimen handling as described previously,^{49,55-57} with close correlation with radiological findings, accurate macroscopic description and precise block designation is vital for reliable identification of the **pre-treatment tumour site*** and assessment of tumour response post neoadjuvant therapy. Precise mapping of the specimen with intelligent block selection guided by close radiological-pathological correlation is preferable to exhaustive sampling. It is strongly recommended that an image of the sliced specimen is recorded, and then used as a map for the sections taken to facilitate subsequent histological interpretation; this may be in the form of radiographs, photographs, photocopies or drawings. The pathologist should evaluate the extent of residual primary cancer in two stages: 1) macroscopic tumour bed as the extent of possible disease based on informed evaluation of the pre-treatment tumour site(s) and any other suspicious areas, and 2) the extent of disease that is confirmed to be cancer after careful sampling for histopathology review and mapping of those findings to the original specimen.

In cases where there has been an excellent response to therapy, there may be no grossly detectable residual tumour present. If there is no visible lesion, then careful palpation of the specimen slices looking for areas of firmness may assist in identifying the tumour bed. Ideally, a fiducial marker (clip or equivalent) will have been placed in the tumour at the time of diagnosis, even in patients who will undergo a mastectomy. The fiducial marker may be identified macroscopically, but if not found on gross examination specimen x-ray can be used to localise the site. The presence of microcalcifications may also help identify the tumour bed on x-ray.

Tumours may show a heterogeneous response to therapy, with patchy distribution of residual islands of tumour cells dispersed across the entire tumour bed. Hence, even if there is a discrete visible lesion present after chemotherapy, sampling needs to extend beyond this to encompass the area occupied by the tumour on pre-treatment imaging. This often requires more extensive block taking than in the adjuvant setting. A maximum of 25 blocks across the tumour bed, including five blocks to

span the maximum tumour dimension, should be sufficient to document pCR.⁴⁹ If the tumour bed or clip site is not present in the sections, the specimen needs to be re-examined in conjunction with the imaging and further blocks may need to be taken.

* The term '*tumour bed*' in post-treatment breast specimens is often used in different ways to describe the area where cancer was and may still be. To avoid confusion, in this document the term 'pre-treatment tumour site' is used to refer to the location of the tumour pre-treatment. The terms 'macroscopic tumour bed' and 'microscopic tumour bed' are explained below. The RCB website¹³ uses the terms 'residual tumour bed' and 'primary tumour bed' interchangeably to refer to the area involved by residual invasive carcinoma as measured initially from the macroscopic findings and modified by the microscopic findings (see **Note 7 RESIDUAL INVASIVE CARCINOMA**).

- 'Macroscopic tumour bed' also often referred to as 'tumour bed': Macroscopically identifiable area post-treatment at the pre-treatment tumour site. Macroscopic findings usually fibrosis may be present at the pre-treatment tumour site. Grossly identifiable residual invasive carcinoma may or may not be present in the macroscopic tumour bed. The boundaries of the macroscopic tumour bed are often not distinct and therefore measurements of the macroscopic tumour bed are often subjective. Alternatively, anywhere in the volume covered by the tumour pre-treatment may be considered the 'macroscopic tumour bed' regardless of the presence of a macroscopic lesion.
- 'Microscopic tumour bed': Microscopically identifiable area post-treatment at the pre-treatment tumour site. Histologic changes such as fibrosis, a characteristic pattern of vessels reminiscent of tumour vasculature, myxoid change, and infiltration by macrophages and/or lymphocytes (sometimes abundant and accompanied by extensive necrosis), suggesting that there was a tumour in this location pre-treatment, may be present at the pre-treatment tumour site. It may be difficult to differentiate these histologic changes from breast tissue that was never involved by tumour and defining the exact boundaries of this area is nearly impossible, and it should not be measured. Alternatively, anywhere in the volume covered by the tumour pre-treatment may be considered the 'microscopic tumour bed' regardless of the presence of histologic changes. Residual invasive carcinoma may or may not be present in the microscopic tumour bed.
- 'Residual tumour bed' or 'Primary tumour bed' (RCB website calculator): The area in the breast involved by residual invasive carcinoma as measured initially from the macroscopic findings and modified by the microscopic findings.

Macroscopically occult residual invasive carcinoma identified microscopically may extend beyond the macroscopic tumour bed. Residual invasive carcinoma may also extend beyond the area of breast tissue showing the background histologic stromal changes suggesting that there was a tumour in the location pre-treatment (see Figure 1, **Note 8 TUMOUR DIMENSIONS**).

Histologic changes related to systemic therapy can be seen in breast tissue (usually in the form of enlarged cells with vacuolated cytoplasm and smudgy nuclear atypia) at the pre-treatment tumour site in the 'microscopic tumour bed' as well as away from the pre-treatment tumour site.

 **Back**

References

- 1 Merlin T, Weston A and Tooher R (2009). Extending an evidence hierarchy to include topics other than treatment: revising the Australian 'levels of evidence'. *BMC Med Res Methodol* 9:34.
- 2 International Collaboration on Cancer Reporting (2022). *Invasive Carcinoma of the Breast Histopathology Reporting Guide. 2nd edition*. Available from: <http://www.iccr-cancer.org/datasets/published-datasets/breast> (Accessed 1st June 2022).
- 3 International Collaboration on Cancer Reporting (2021). *Ductal Carcinoma In Situ, Variants of Lobular Carcinoma In Situ and Low Grade Lesions Histopathology Reporting Guide. 1st edition*. Available from: <http://www.iccr-cancer.org/datasets/published-datasets/breast> (Accessed 1st June 2022).
- 4 International Collaboration on Cancer Reporting (2021). *Surgically Removed Lymph Nodes for Breast Tumours Histopathology Reporting Guide. 1st edition*. Available from: <http://www.iccr-cancer.org/datasets/published-datasets/breast> (Accessed 1st June 2022).
- 5 International Collaboration on Cancer Reporting (2021). *Soft Tissue Sarcoma Histopathology Reporting Guide - Resection Specimens. 1st edition*. Available from: <http://www.iccr-cancer.org/datasets/published-datasets/soft-tissue-bone> (Accessed 19th April 2021).
- 6 Wein L, Savas P, Luen SJ, Virassamy B, Salgado R and Loi S (2017). Clinical Validity and Utility of Tumor-Infiltrating Lymphocytes in Routine Clinical Practice for Breast Cancer Patients: Current and Future Directions. *Front Oncol* 7:156.
- 7 Hennessy BT, Hortobagyi GN, Rouzier R, Kuerer H, Sneige N, Buzdar AU, Kau SW, Fornage B, Sahin A, Broglio K, Singletary SE and Valero V (2005). Outcome after pathologic complete eradication of cytologically proven breast cancer axillary node metastases following primary chemotherapy. *J Clin Oncol* 23(36):9304-9311.
- 8 Brierley JD, Gospodarowicz MK and Wittekind C (eds) (2016). *Union for International Cancer Control. TNM Classification of Malignant Tumours, 8th Edition*, Wiley, USA.
- 9 Amin MB, Edge S, Greene FL, Byrd DR, Brookland RK, Washington MK, Gershenwald JE, Compton CC, Hess KR, Sullivan DC, Jessup JM, Brierley JD, Gaspar LE, Schilsky RL, Balch CM, Winchester DP, Asare EA, Madera M, Gress DM and Meyer LR (eds) (2017). *AJCC Cancer Staging Manual. 8th ed*. Springer, New York.
- 10 Ogston KN, Miller ID, Payne S, Hutcheon AW, Sarkar TK, Smith I, Schofield A and Heys SD (2003). A new histological grading system to assess response of breast cancers to primary chemotherapy: prognostic significance and survival. *Breast* 12(5):320-327.
- 11 Rajan R, Esteva FJ and Symmans WF (2004). Pathologic changes in breast cancer following neoadjuvant chemotherapy: implications for the assessment of response. *Clin Breast Cancer* 5(3):235-238.

- 12 Symmans WF, Peintinger F, Hatzis C, Rajan R, Kuerer H, Valero V, Assad L, Poniecka A, Hennessy B, Green M, Buzdar AU, Singletary SE, Hortobagyi GN and Pusztai L (2007). Measurement of residual breast cancer burden to predict survival after neoadjuvant chemotherapy. *J Clin Oncol* 25(28):4414-4422.
- 13 MD Anderson Cancer Centre. *Residual Cancer Burden Calculator*. Available from: http://www.mdanderson.org/breastcancer_RCB (Accessed 20th March 2020).
- 14 Dieci MV, Radosevic-Robin N, Fineberg S, van den Eynden G, Ternes N, Penault-Llorca F, Pruneri G, D'Alfonso TM, Demaria S, Castaneda C, Sanchez J, Badve S, Michiels S, Bossuyt V, Rojo F, Singh B, Nielsen T, Viale G, Kim SR, Hewitt S, Wienert S, Loibl S, Rimm D, Symmans F, Denkert C, Adams S, Loi S and Salgado R (2018). Update on tumor-infiltrating lymphocytes (TILs) in breast cancer, including recommendations to assess TILs in residual disease after neoadjuvant therapy and in carcinoma in situ: A report of the International Immunology Biomarker Working Group on Breast Cancer. *Semin Cancer Biol* 52(Pt 2):16-25.
- 15 Luen SJ, Salgado R, Dieci MV, Vingiani A, Curigliano G, Gould RE, Castaneda C, D'Alfonso T, Sanchez J, Cheng E, Andreopoulou E, Castillo M, Adams S, Demaria S, Symmans WF, Michiels S and Loi S (2019). Prognostic implications of residual disease tumor-infiltrating lymphocytes and residual cancer burden in triple-negative breast cancer patients after neoadjuvant chemotherapy. *Ann Oncol* 30(2):236-242.
- 16 WHO Classification of Tumours Editorial Board (ed) (2019). *WHO Classification of Tumours, Breast Tumours, 5th Edition*. IARC Publications, Lyon.
- 17 WHO Classification of Tumours Editorial Board (2020). *Breast Tumours, WHO Classification of Tumours, 5th Edition, Volume 2 - Corrigenda September 2020*. Available from: <https://publications.iarc.fr/Book-And-Report-Series/Who-Classification-Of-Tumours/Breast-Tumours-2019> (Accessed 16th June 2021).
- 18 Sahoo S and Lester SC (2012). Pathology Considerations in Patients Treated with Neoadjuvant Chemotherapy. *Surg Pathol Clin* 5(3):749-774.
- 19 Fritz A, Percy C, Jack A, Shanmugaratnam K, Sobin L, Parkin DM and Whelan S (eds) (2020). *International Classification of Diseases for Oncology, Third edition, Second revision ICD-O-3.2*. Available from: http://www.iacr.com.fr/index.php?option=com_content&view=category&layout=blog&id=100&Itemid=577 (Accessed 16th June 2021).
- 20 Adams AL, Eltoum I, Krontiras H, Wang W and Chheng DC (2008). The effect of neoadjuvant chemotherapy on histologic grade, hormone receptor status, and HER2/neu status in breast carcinoma. *Breast J* 14(2):141-146.
- 21 Abdel-Fatah TM, Ball G, Lee AH, Pinder S, MacMilan RD, Cornford E, Moseley PM, Silverman R, Price J, Latham B, Palmer D, Chan A, Ellis IO and Chan SY (2015). Nottingham Clinico-Pathological Response Index (NPRI) after neoadjuvant chemotherapy (Neo-ACT) accurately predicts clinical outcome in locally advanced breast cancer. *Clin Cancer Res* 21(5):1052-1062.
- 22 Diaz J, Stead L, Shapiro N, Newell R, Loudig O, Lo Y, Sparano J and Fineberg S (2013). Mitotic counts in breast cancer after neoadjuvant systemic chemotherapy and development of metastatic disease. *Breast Cancer Res Treat* 138(1):91-97.

- 23 Elston CW and Ellis IO (1991). Pathological prognostic factors in breast cancer. I. The value of histological grade in breast cancer: experience from a large study with long-term follow-up. *Histopathology* 19(5):403-410.
- 24 Cortazar P, Zhang L, Untch M, Mehta K, Costantino JP, Wolmark N, Bonnefoi H, Cameron D, Gianni L, Valagussa P, Swain SM, Prowell T, Loibl S, Wickerham DL, Bogaerts J, Baselga J, Perou C, Blumenthal G, Blohmer J, Mamounas EP, Bergh J, Semiglazov V, Justice R, Eidtmann H, Paik S, Piccart M, Sridhara R, Fasching PA, Slaets L, Tang S, Gerber B, Geyer CE, Jr., Pazdur R, Ditsch N, Rastogi P, Eiermann W and von Minckwitz G (2014). Pathological complete response and long-term clinical benefit in breast cancer: the CTNeoBC pooled analysis. *Lancet* 384(9938):164-172.
- 25 Jabbour MN, Massad CY and Boulos FI (2012). Variability in hormone and growth factor receptor expression in primary versus recurrent, metastatic, and post-neoadjuvant breast carcinoma. *Breast Cancer Res Treat* 135(1):29-37.
- 26 Zhang N, Moran MS, Huo Q, Haffty BG and Yang Q (2011). The hormonal receptor status in breast cancer can be altered by neoadjuvant chemotherapy: a meta-analysis. *Cancer Invest* 29(9):594-598.
- 27 Tacca O, Penault-Llorca F, Abrial C, Mouret-Reynier MA, Raoelfils I, Durando X, Achard JL, Gimbergues P, Curé H and Chollet P (2007). Changes in and prognostic value of hormone receptor status in a series of operable breast cancer patients treated with neoadjuvant chemotherapy. *Oncologist* 12(6):636-643.
- 28 Ellis MJ, Tao Y, Luo J, A'Hern R, Evans DB, Bhatnagar AS, Chaudri Ross HA, von Kameke A, Miller WR, Smith I, Eiermann W and Dowsett M (2008). Outcome prediction for estrogen receptor-positive breast cancer based on postneoadjuvant endocrine therapy tumor characteristics. *J Natl Cancer Inst* 100(19):1380-1388.
- 29 Ellis MJ, Suman VJ, Hoog J, Goncalves R, Sanati S, Creighton CJ, DeSchryver K, Crouch E, Brink A, Watson M, Luo J, Tao Y, Barnes M, Dowsett M, Budd GT, Winer E, Silverman P, Esserman L, Carey L, Ma CX, Unzeitig G, Pluard T, Whitworth P, Babiera G, Guenther JM, Dayao Z, Ota D, Leitch M, Olson JA, Jr., Allred DC and Hunt K (2017). Ki67 Proliferation Index as a Tool for Chemotherapy Decisions During and After Neoadjuvant Aromatase Inhibitor Treatment of Breast Cancer: Results From the American College of Surgeons Oncology Group Z1031 Trial (Alliance). *J Clin Oncol* 35(10):1061-1069.
- 30 Niikura N, Tomotaki A, Miyata H, Iwamoto T, Kawai M, Anan K, Hayashi N, Aogi K, Ishida T, Masuoka H, Iijima K, Masuda S, Tsugawa K, Kinoshita T, Nakamura S and Tokuda Y (2016). Changes in tumor expression of HER2 and hormone receptors status after neoadjuvant chemotherapy in 21,755 patients from the Japanese breast cancer registry. *Ann Oncol* 27(3):480-487.
- 31 Mittendorf EA, Wu Y, Scaltriti M, Meric-Bernstam F, Hunt KK, Dawood S, Esteva FJ, Buzdar AU, Chen H, Eksambi S, Hortobagyi GN, Baselga J and Gonzalez-Angulo AM (2009). Loss of HER2 amplification following trastuzumab-based neoadjuvant systemic therapy and survival outcomes. *Clin Cancer Res* 15(23):7381-7388.

- 32 Cabrera-Galeana P, Muñoz-Montaño W, Lara-Medina F, Alvarado-Miranda A, Pérez-Sánchez V, Villarreal-Garza C, Quintero RM, Porrás-Reyes F, Bargallo-Rocha E, Del Carmen I, Mohar A and Arrieta O (2018). Ki67 Changes Identify Worse Outcomes in Residual Breast Cancer Tumors After Neoadjuvant Chemotherapy. *Oncologist* 23(6):670-678.
- 33 Sheri A, Smith IE, Johnston SR, A'Hern R, Nerurkar A, Jones RL, Hills M, Detre S, Pinder SE, Symmans WF and Dowsett M (2015). Residual proliferative cancer burden to predict long-term outcome following neoadjuvant chemotherapy. *Ann Oncol* 26(1):75-80.
- 34 Goncalves R, DeSchryver K, Ma C, Tao Y, Hoog J, Cheang M, Crouch E, Dahiya N, Sanati S, Barnes M, Sarian LOZ, Olson J, Allred DC and Ellis MJ (2017). Development of a Ki-67-based clinical trial assay for neoadjuvant endocrine therapy response monitoring in breast cancer. *Breast Cancer Res Treat* 165(2):355-364.
- 35 Dowsett M, Smith IE, Ebbs SR, Dixon JM, Skene A, A'Hern R, Salter J, Detre S, Hills M and Walsh G (2007). Prognostic value of Ki67 expression after short-term presurgical endocrine therapy for primary breast cancer. *J Natl Cancer Inst* 99(2):167-170.
- 36 Loya A, Guray M, Hennessy BT, Middleton LP, Buchholz TA, Valero V and Sahin AA (2009). Prognostic significance of occult axillary lymph node metastases after chemotherapy-induced pathologic complete response of cytologically proven axillary lymph node metastases from breast cancer. *Cancer* 115(8):1605-1612.
- 37 Cserni G (2012). Intraoperative analysis of sentinel lymph nodes in breast cancer by one-step nucleic acid amplification. *J Clin Pathol* 65(3):193-199.
- 38 Kuehn T, Bauerfeind I, Fehm T, Fleige B, Hausschild M, Helms G, Lebeau A, Liedtke C, von Minckwitz G, Nekljudova V, Schmatloch S, Schrenk P, Staebler A and Untch M (2013). Sentinel-lymph-node biopsy in patients with breast cancer before and after neoadjuvant chemotherapy (SENTINA): a prospective, multicentre cohort study. *Lancet Oncol* 14(7):609-618.
- 39 Boileau JF, Poirier B, Basik M, Holloway CM, Gaboury L, Sideris L, Meterissian S, Arnaout A, Brackstone M, McCready DR, Karp SE, Trop I, Lisbona A, Wright FC, Younan RJ, Provencher L, Patocskai E, Omeroglu A and Robidoux A (2015). Sentinel node biopsy after neoadjuvant chemotherapy in biopsy-proven node-positive breast cancer: the SN FNAC study. *J Clin Oncol* 33(3):258-264.
- 40 Boughey JC, Suman VJ, Mittendorf EA, Ahrendt GM, Wilke LG, Taback B, Leitch AM, Kuerer HM, Bowling M, Flippo-Morton TS, Byrd DR, Ollila DW, Julian TB, McLaughlin SA, McCall L, Symmans WF, Le-Petross HT, Haffty BG, Buchholz TA, Nelson H and Hunt KK (2013). Sentinel lymph node surgery after neoadjuvant chemotherapy in patients with node-positive breast cancer: the ACOSOG Z1071 (Alliance) clinical trial. *Jama* 310(14):1455-1461.
- 41 College of American Pathologists (2022). *Protocol for the Examination of Resection Specimens From Patients With Invasive Carcinoma of the Breast*. Available from: https://documents.cap.org/protocols/Breast.Invasive_4.6.0.0.REL_CAPCP.pdf (Accessed 2nd April 2022).

- 42 Royal College of Pathologists (2016). *Pathology reporting of breast disease in surgical excision specimens incorporating the dataset for histological reporting of breast cancer*. Available from: <https://www.rcpath.org/profession/guidelines/cancer-datasets-and-tissue-pathways.html> (Accessed 26th March 2020).
- 43 Klauber-DeMore N, Ollila DW, Moore DT, Livasy C, Calvo BF, Kim HJ, Dees EC, Sartor CI, Sawyer LR, Graham M, 2nd and Carey LA (2006). Size of residual lymph node metastasis after neoadjuvant chemotherapy in locally advanced breast cancer patients is prognostic. *Ann Surg Oncol* 13(5):685-691.
- 44 American Joint Committee on Cancer. *Updated breast chapter for 8th edition*. Available from: <https://cancerstaging.org/references-tools/deskreferences/Documents/AJCC%20Breast%20Cancer%20Staging%20System.pdf> (Accessed 31st March 2021).
- 45 Cserni G (2011). Meta-analysis of predictive factors for non-sentinel lymph node metastases in breast cancer patients with a positive SLN. *Breast Diseases: A Year Book Quarterly* (22(4)): 390-391.
- 46 Cserni G (2011). Sentinel node biopsy and nodal staging. In: *Breast cancer, a heterogeneous disease entity. The very early stages*, (eds) KZaTT (ed), Springer Science+Business Media, Dordrecht-Heidelberg-London-New York, pp 149-184.
- 47 van la Parra RF, Peer PG, Ernst MF and Bosscha K (2011). Meta-analysis of predictive factors for non-sentinel lymph node metastases in breast cancer patients with a positive SLN. *Eur J Surg Oncol* 37(4):290-299.
- 48 Nottegar A, Veronese N, Senthil M, Roumen RM, Stubbs B, Choi AH, Verheuvcl NC, Solmi M, Pea A, Capelli P, Fassan M, Sergi G, Manzato E, Maruzzo M, Bagante F, Koç M, Eryilmaz MA, Bria E, Carbognin L, Bonetti F, Barbareschi M and Luchini C (2016). Extra-nodal extension of sentinel lymph node metastasis is a marker of poor prognosis in breast cancer patients: A systematic review and an exploratory meta-analysis. *Eur J Surg Oncol* 42(7):919-925.
- 49 Provenzano E, Bossuyt V, Viale G, Cameron D, Badve S, Denkert C, MacGrogan G, Penault-Llorca F, Boughey J, Curigliano G, Dixon JM, Esserman L, Fastner G, Kuehn T, Peintinger F, von Minckwitz G, White J, Yang W and Symmans WF (2015). Standardization of pathologic evaluation and reporting of postneoadjuvant specimens in clinical trials of breast cancer: recommendations from an international working group. *Mod Pathol* 28(9):1185-1201.
- 50 Bossuyt V, Provenzano E, Symmans WF, Boughey JC, Coles C, Curigliano G, Dixon JM, Esserman LJ, Fastner G, Kuehn T, Peintinger F, von Minckwitz G, White J, Yang W, Badve S, Denkert C, MacGrogan G, Penault-Llorca F, Viale G and Cameron D (2015). Recommendations for standardized pathological characterization of residual disease for neoadjuvant clinical trials of breast cancer by the BIG-NABCG collaboration. *Ann Oncol* 26(7):1280-1291.
- 51 Peintinger F, Sinn B, Hatzis C, Albarracin C, Downs-Kelly E, Morkowski J, Gould R and Symmans WF (2015). Reproducibility of residual cancer burden for prognostic assessment of breast cancer after neoadjuvant chemotherapy. *Mod Pathol* 28(7):913-920.

- 52 Thomas JSJ, Provenzano E, Hiller L, Dunn J, Blenkinsop C, Grybowicz L, Vallier AL, Gounaris I, Abraham J, Hughes-Davies L, McAdam K, Chan S, Ahmad R, Hickish T, Houston S, Rea D, Caldas C, Bartlett JM, Cameron DA, Hayward RL and Earl HM (2017). Central pathology review with two-stage quality assurance for pathological response after neoadjuvant chemotherapy in the ARTemis Trial. *Mod Pathol* 30(8):1069-1077.
- 53 Christina Yau, Marieke van der Noordaa, Jane Wei, Marie Osdoit, Fabien Reyal, Anne-Sophie Hamy, Marick Lae, Miguel Martin, Maria del Monte, I-SPY 2 TRIAL Consortium, Judy C Boughey, Rebekah Gould, Jelle Wesseling, Tessa Steenbruggen, Maartje van Seijen, Gabe Sonke, Stephen Edge, Stephen-John Sammut, Elena Provenzano, Jean Abraham, Peter Hall, Ashley Graham, Lorna Mackintosh, David Cameron, Alice Wang, Priyanka Sharma, Kimberly Cole, Lajos Pusztai, Mi-Ok Kim, Laura van 't Veer, Laura Esserman and Symmans WF (2019). Residual cancer burden after neoadjuvant therapy and long-term survival outcomes in breast cancer: A multi-center pooled analysis. *San Antonio Breast Cancer Symposium*, Texas, USA.
- 54 Yau C, Osdoit M, van der Noordaa M, Shad S, Wei J, de Croze D, Hamy AS, Laé M, Reyal F, Sonke GS, Steenbruggen TG, van Seijen M, Wesseling J, Martín M, Del Monte-Millán M, López-Tarruella S, Boughey JC, Goetz MP, Hoskin T, Gould R, Valero V, Edge SB, Abraham JE, Bartlett JMS, Caldas C, Dunn J, Earl H, Hayward L, Hiller L, Provenzano E, Sammut SJ, Thomas JS, Cameron D, Graham A, Hall P, Mackintosh L, Fan F, Godwin AK, Schwensen K, Sharma P, DeMichele AM, Cole K, Pusztai L, Kim MO, van 't Veer LJ, Esserman LJ and Symmans WF (2022). Residual cancer burden after neoadjuvant chemotherapy and long-term survival outcomes in breast cancer: a multicentre pooled analysis of 5161 patients. *Lancet Oncol* 23(1):149-160.
- 55 Bossuyt V, Provenzano E, Symmans WF, Boughey JC, Coles C, Curigliano G, Dixon JM, Esserman LJ, Fastner G, Kuehn T, Peintinger F, von Minckwitz G, White J, Yang W, Badve S, Denkert C, MacGrogan G, Penault-Llorca F, Viale G, Cameron D and Breast International Group-North American Breast Cancer Group (BIG-NABCG) collaboration (2015). Recommendations for standardized pathological characterization of residual disease for neoadjuvant clinical trials of breast cancer by the BIG-NABCG collaboration. *Ann Oncol* 26(7):1280-1291.
- 56 Pinder SE, Provenzano E, Earl H and Ellis IO (2007). Laboratory handling and histology reporting of breast specimens from patients who have received neoadjuvant chemotherapy. *Histopathology* 50(4):409-417.
- 57 Pinder SE, Rakha EA, Purdie CA, Bartlett JM, Francis A, Stein RC, Thompson AM, Shaaban AM and Translational Subgroup of the NCRI Breast Clinical Studies Group (2015). Macroscopic handling and reporting of breast cancer specimens pre- and post-neoadjuvant chemotherapy treatment: review of pathological issues and suggested approaches. *Histopathology* 67(3):279-293.