

# Carcinoma of the Oesophagus Histopathology Reporting Guide



Family/Last name  Date of birth

Given name(s)

Patient identifiers  Date of request  Accession/Laboratory number

Elements in **black text** are **CORE**. Elements in **grey text** are **NON-CORE**.

☐ indicates multi-select values ☐ indicates single select values

SCOPE OF THIS DATASET

## CLINICAL INFORMATION (select all that apply) (Note 1)

☐ Information not provided

☐ Relevant biopsy results, *specify*


☐ Previous diagnosis and treatment for oesophageal cancer, *specify*


☐ Endoscopic location of the tumour, *specify levels (upper/middle/lower)*


☐ Clinical staging, *specify level of involvement, distant metastases*


☐ History of gastroesophageal reflux and/or Barrett oesophagus

☐ Other (e.g., previous history of cancer), *specify*

## NEOADJUVANT THERAPY (Note 2)

☐ Not administered

☐ Information not provided

☐ Administered, *describe*


## OPERATIVE PROCEDURE (select all that apply) (Note 3)

☐ Not specified

☐ Pharyngo-laryngo-oesophagectomy

☐ Oesophagectomy/oesophagogastrrectomy

☐ Lymph nodes, *describe site(s) from which taken if sent separately by surgeon*

☐ Other, *specify*

## SPECIMEN DIMENSIONS (Note 4)

Length of tubular oesophagus  
(Record per specimen)

Specimen 1

Specimen 2

Specimen 3

Length of stomach, from oesophagogastric junction to distal gastric resection margin (if present)

## MACROSCOPIC APPEARANCE (Note 5)

☐ No macroscopically detectable lesion

☐ Scar/thickening

☐ Protruding/fungating/polypoid

☐ Ulcerative tumour

☐ Diffuse infiltrative

## TUMOUR FOCALITY<sup>a</sup> (Note 6)

☐ Unifocal

☐ Multifocal, *specify number of tumours in specimen*

☐ Cannot be assessed, *specify*

<sup>a</sup> If multiple primary tumours are present, separate datasets should be used to record this and all following elements for each primary tumour.

## TUMOUR SITE (select all that apply) (Note 7)

☐ Not specified

☐ Cervical (proximal) oesophagus

☐ Upper thoracic oesophagus

☐ Middle thoracic oesophagus

☐ Lower thoracic (distal) oesophagus

☐ Oesophagogastric junction (OGJ) with tumour epicentre ≤20 mm into the proximal stomach

☐ Other, *specify*

Distance from epicentre/midpoint of tumour to OGJ

**TUMOUR DIMENSIONS** (Note 8)

Maximum tumour dimension

mm

Additional dimensions

mm

x

mm

☐ No macroscopically visible tumour☐ Cannot be assessed, *specify***BARRETT MUCOSA** (Note 9)☐ Not identified☐ Present**MACROSCOPIC DISTANCE OF TUMOUR TO THE MARGIN** (Note 10)☐ Cannot be assessed☐ Involved☐ Not involved

Distance of tumour from closest margin

mm

Specify closest margin

**HISTOLOGICAL TUMOUR TYPE** (Note 11)*(Value list based on the World Health Organization Classification of Tumours of the Digestive System (2019))*☐ Cannot be assessed☐ Squamous cell carcinoma☐ Conventional☐ Verrucous☐ Spindle cell carcinoma☐ Basaloid squamous cell carcinoma☐ Adenocarcinoma☐ Tubular☐ Papillary☐ Mucinous☐ Poorly cohesive carcinoma☐ Signet ring☐ Non-signet ring☐ Mucoepidermoid☐ Adenosquamous carcinoma☐ Adenoid cystic carcinoma☐ Undifferentiated carcinoma☐ Neuroendocrine neoplasms<sup>b</sup>☐ Neuroendocrine carcinoma☐ Small cell☐ Large cell☐ Mixed neuroendocrine-non-neuroendocrine neoplasm (MiNEN)☐ Other, *specify***DYSPLASIA** (Note 12)☐ Not applicable☐ Cannot be assessed☐ Not identified☐ Present**Type**☐ Squamous☐ Columnar/Barrett**Grade**☐ Low grade☐ High grade☐ Cannot be assessed, *specify***HISTOLOGICAL TUMOUR GRADE** (Note 13)*(Applicable to squamous cell carcinoma and adenocarcinoma)*☐ GX: Cannot be assessed☐ Grade 1 (G1): Well differentiated☐ Grade 2 (G2): Moderately differentiated☐ Grade 3 (G3): Poorly differentiated**EXTENT OF INVASION** (Note 14)☐ Cannot be assessed☐ No evidence of primary tumour☐ Dysplasia☐ Invasion into the lamina propria☐ Invasion into the muscularis mucosae☐ Invasion into the submucosa☐ Invasion into the muscularis propria☐ Invasion into the adventitia☐ Invasion into the visceral peritoneum, azygous vein, diaphragm, pleura, pericardium☐ Invasion into adjacent structures/organs, *specify***LYMPHOVASCULAR INVASION** (Note 15)☐ Not identified☐ Present (select all that apply)☐ Small vessel (lymphatic, capillary or venular), *specify the type of vessel, if possible*☐ Large vessel (venous)**PERINEURAL INVASION** (Note 16)☐ Not identified☐ Present<sup>b</sup> Neuroendocrine tumour is not covered in this dataset.

**RESPONSE TO NEOADJUVANT THERAPY (Note 17)**

☐ Cannot be assessed, *specify*

**Manard system**

- ☐ Absence of residual cancer with fibrosis extending throughout (complete response)
- ☐ Rare residual cancer cells scattered through the fibrosis
- ☐ An increase in the number of residual cancer cells, but fibrosis still predominates
- ☐ Residual cancer outgrowing fibrosis
- ☐ Absence of regressive changes

**OR****Becker system**

- ☐ No carcinoma present (complete response)
- ☐ <10% carcinoma present
- ☐ 10-50% carcinoma present
- ☐ >50% carcinoma present

**OR****Modified Ryan system**

- ☐ No neoadjuvant treatment
- ☐ Complete response - no viable cancer cells (score 0)
- ☐ Near complete response - single cells or rare small groups of cancer cells (score 1)
- ☐ Partial response - residual cancer with evident tumour regression, but more than single cells or rare small groups of cancer cells (score 2)
- ☐ Poor or no response - extensive residual cancer with no evident tumour regression (score 3)

**MARGIN STATUS (Note 18)****Invasive carcinoma**

- ☐ Cannot be assessed
- ☐ Not involved

Distance of tumour from closest margin

mm

Specify closest margin, if possible

- ☐ Involved (select all that apply)

- ☐ Distal
- ☐ Proximal
- ☐ Circumferential/Radial

**Dysplasia**

- ☐ Cannot be assessed
- ☐ Not involved

Distance of dysplasia from closest margin

mm

Specify closest margin, if possible

- ☐ Involved

- ☐ Squamous
- ☐ Columnar/Barrett
- ☐ High grade
- ☐ Low grade
- ☐ High grade
- ☐ Low grade

Specify margin (select all that apply)

- ☐ Distal
- ☐ Proximal

**LYMPH NODE STATUS (Note 19)**

- ☐ Cannot be assessed
- ☐ No nodes submitted or found

Number of lymph nodes examined

- ☐ Not involved
- ☐ Involved

Number of involved lymph nodes

**Extranodal extension**

- ☐ Not identified
- ☐ Present
- ☐ Cannot be determined

**COEXISTENT PATHOLOGY (select all that apply) (Note 20)**

- ☐ None identified
- ☐ Synchronous carcinoma(s), *specify*

- ☐ Other, *specify*

**ANCILLARY STUDIES (Note 21)****For neuroendocrine neoplasms only**

- ☐ Not applicable
- ☐ Neuroendocrine markers (chromogranin A, synaptophysin, other), *specify test(s) performed and result(s) if available*

AND

Ki-67 proliferation index

%

**Other oesophageal carcinomas**

- ☐ Not performed
- ☐ Performed (select all that apply)
- ☐ HER2 testing performed, *record results*

- ☐ PD-L1, *specify*

- ☐ Microsatellite instability, *specify*

- ☐ Other, *specify test(s) and result(s)*

**HISTOLOGICALLY CONFIRMED DISTANT METASTASES**

(Note 22)

- ☐ Not identified
- ☐ Present, *specify site(s)*




**PATHOLOGICAL STAGING (UICC TNM 8<sup>th</sup> edition)<sup>c,d</sup>** (Note 23)**TNM Descriptors** (only if applicable)

- ☐ No adjuvant therapy
- ☐ y - post-therapy

**Primary tumour (pT)**

- ☐ TX Primary tumour cannot be assessed
- ☐ T0 No evidence of primary tumour
- ☐ Tis Carcinoma in situ/high grade dysplasia
- ☐ T1 Tumour invades lamina propria, muscularis mucosae, or submucosae
- ☐ T1a Tumour invades lamina propria or muscularis mucosae
- ☐ T1b Tumour invades submucosa
- ☐ T2 Tumour invades muscularis propria
- ☐ T3 Tumour invades adventitia
- ☐ T4 Tumour invades adjacent structures
- ☐ T4a Tumour invades pleura, pericardium, azygos vein, diaphragm, or peritoneum
- ☐ T4b Tumour invades other adjacent structures such as aorta, vertebral body, or trachea

**Regional lymph nodes (pN)**

- ☐ NX Regional lymph nodes cannot be assessed
- ☐ N0 No regional lymph node metastasis
- ☐ N1 Metastasis in 1 to 2 regional lymph nodes
- ☐ N2 Metastasis in 3 to 6 regional lymph nodes
- ☐ N3 Metastasis in 7 or more regional lymph nodes

<sup>c</sup> Reproduced with permission. Source: *UICC TNM Classification of Malignant Tumours, 8<sup>th</sup> Edition*, eds by James D. Brierley, Mary K. Gospodarowicz, Christian Wittekind. 2016, Publisher Wiley.

<sup>d</sup> Refer to Note for AJCC 8<sup>th</sup> Edition staging of oesophageal adenocarcinomas and squamous cell carcinomas with or without neoadjuvant therapy.

# Definitions

## CORE elements

CORE elements are those which are essential for the clinical management, staging or prognosis of the cancer. These elements will either have evidentiary support at Level III-2 or above (based on prognostic factors in the National Health and Medical Research Council levels of evidence<sup>1</sup>). In rare circumstances, where level III-2 evidence is not available an element may be made a CORE element where there is unanimous agreement in the expert committee. An appropriate staging system, e.g., Pathological TNM staging, would normally be included as a CORE element.

The summation of all CORE elements is considered to be the minimum reporting standard for a specific cancer.

## NON-CORE elements

NON-CORE elements are those which are unanimously agreed should be included in the dataset but are not supported by level III-2 evidence. These elements may be clinically important and recommended as good practice but are not yet validated or regularly used in patient management.

Key information other than that which is essential for clinical management, staging or prognosis of the cancer such as macroscopic observations and interpretation, which are fundamental to the histological diagnosis and conclusion e.g., macroscopic tumour details, may be included as either CORE or NON-CORE elements by consensus of the Dataset Authoring Committee.

 **Back**

# Scope

The dataset has been developed for the pathology reporting of resection specimens of the oesophagus. Carcinomas involving the oesophagogastric junction (OGJ) with tumour epicentre  $\leq 20$  millimetres (mm) into the proximal stomach are included. A separate International Collaboration on Cancer Reporting (ICCR) dataset is available for endoscopic resections of the oesophagus and oesophagogastric junction.<sup>2</sup>

Neuroendocrine carcinomas (NEC) and mixed neuroendocrine-non-neuroendocrine neoplasms (MiNEN) of the oesophagus are included.

Neuroendocrine tumours (NET), non-epithelial malignancies such as melanoma, and secondary tumours are excluded from this dataset.

The authors of this dataset can be accessed [here](#).

 **Back**

## Note 1 – Clinical information (Non-core)

Clinical information should ideally be provided by the clinician on the endoscopy report or the pathology request form. Pathologists may also search for additional information from previous pathology reports.

Relevant biopsy results include the presence of carcinoma, dysplasia (intraepithelial neoplasia) and Barrett metaplasia.

Endoscopic location or information regarding the location of the tumour from the clinician are an important guide as the specimen received may have retraction artefact after formalin fixation.

Information on clinical stage, such as the presence of distant metastases and involvement of adjacent structures, is essential information for the pathologist.

Multiple tumours may occur in the oesophagus and especially in patients with a previous history of cancer e.g., carcinoma of hypopharynx.

 [Back](#)

## Note 2 – Neoadjuvant therapy (Core)

Cancers with or without neoadjuvant therapy have different staging groups.<sup>3</sup>

Survival of patients with oesophageal adenocarcinoma after neoadjuvant chemotherapy/radiotherapy depends on the response to therapy.

The main treatment options with curative intent for advanced stage oesophageal carcinoma are neoadjuvant chemoradiation with surgery or definitive chemoradiation.<sup>4</sup> Response to neoadjuvant therapy, including regression grade and lymph node downstaging, has a marked impact on cancer recurrence and survival of patients with oesophageal adenocarcinoma and squamous cell carcinoma.<sup>5-10</sup>

 [Back](#)

## Note 3 – Operative procedure (Core)

‘Oesophagectomy’ includes the oesophagus and a tiny strip of stomach and technically is also referred to as ‘oesophagogastrrectomy’ which is removal of the oesophagus and the proximal portion of stomach.

The type of resection is a core element, as processing is different among different types of specimens. There is a general lack of uniformity as to the definition of the term lymphadenectomy in the context of oesophageal cancer surgery. For the purposes of this dataset the definitions standardised by the International Society of Diseases of the Esophagus and reviewed in Jamieson et al (2009) are used.<sup>11</sup>

A two-field lymphadenectomy refers to dissection of the mediastinum as well as the upper abdominal lymph nodes around the coeliac trifurcation. Three-field lymphadenectomy refers to the addition of bilateral cervical lymphadenectomy. Three-field lymphadenectomy is optimal for an upper or middle thoracic oesophageal cancer with metastasis in the lymph node(s) based on improved long-term survival data.<sup>12</sup> Therefore, the extent of lymphadenectomy should be recorded.<sup>11,12</sup>

Ideally, lymph nodes should be submitted in groups and labelled separately by surgeons. It is otherwise difficult for pathologists to identify the different groups of lymph nodes.

**↑ Back**

## **Note 4 – Specimen dimensions (Non-core)**

The dimensions of the specimen are normally measured to provide reference to the location of the tumour. It is noted that the oesophagus is approximately 250 mm in length. Record the specimen dimensions for each specimen.

If a specimen is received piecemeal and submitted in the one container, then a reconstructed measurement of size is recommended.

**↑ Back**

## **Note 5 – Macroscopic appearance (Non-core)**

There is no evidence that macroscopic appearance has prognostic value in oesophageal cancer. However, the macroscopic appearance of the lesion, such as having an ulcerative appearance, could indicate the potential for a more advanced lesion.

The World Health Organization (WHO) descriptions for oesophageal squamous cell carcinoma are recommended.<sup>13</sup>

In the WHO Classification of oesophageal cancer, the macroscopic description for oesophageal adenocarcinoma is stricturing, polypoid, fungating, ulcerative, or diffuse infiltrating lesions whereas in squamous cell carcinoma, tumours are described as early versus advanced.<sup>13</sup> Advanced squamous cell carcinoma is defined as protruding, ulcerative and localised, ulcerative and infiltrative as well as diffusely infiltrative.<sup>13</sup> There is no WHO recommendation on the macroscopic description for other tumour types. However, there is no clinical significance attributed to these macroscopic features. In this dataset, we have unified the macroscopic descriptions to account for the effect of neoadjuvant therapies. It is worth noting that in specimens obtained post neoadjuvant therapy, there may be no macroscopically detectable lesion, or just a small scar seen.

**↑ Back**

## Note 6 – Tumour focality (Core)

Multifocal oesophageal carcinomas should be documented. If there are synchronous primary lesions (i.e., two or more individual tumours), separate datasets should be used to record the tumour site and all following elements for each primary tumour.

 [Back](#)

## Note 7 – Tumour site (Core and Non-core)

The location of the tumour is important for staging of oesophageal cancer.<sup>3</sup>

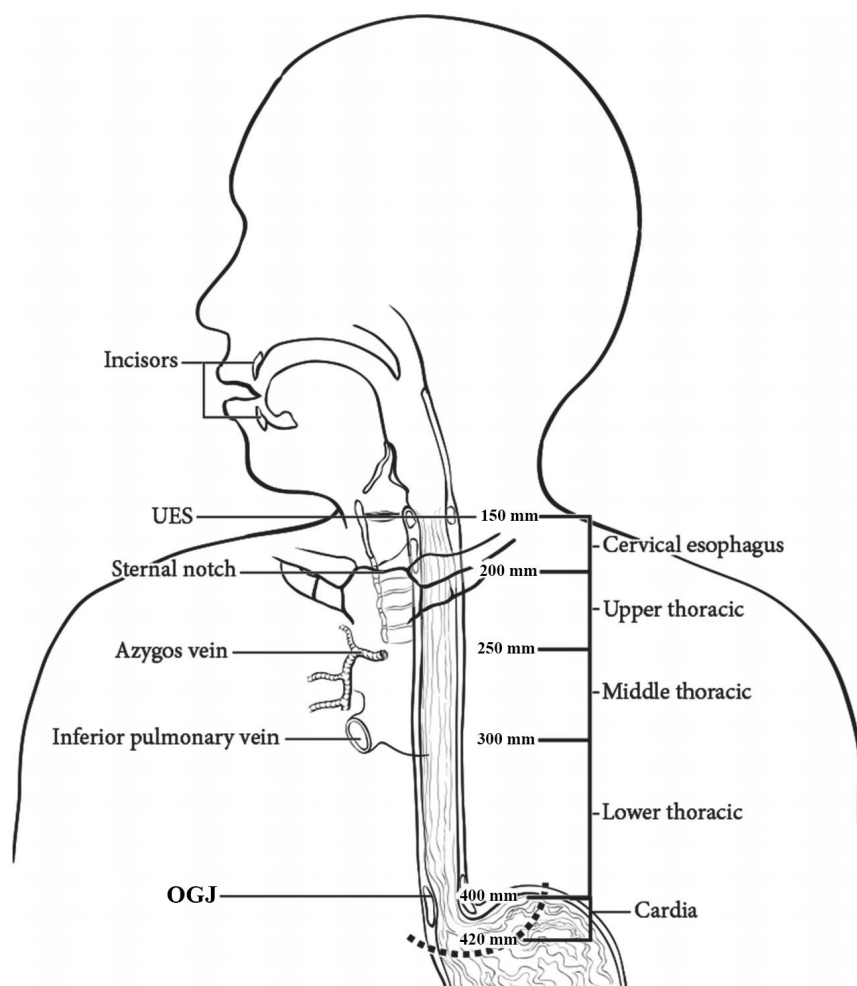
The location of a tumour is based on endoscopic examination and landmarks (Figures 1 and 2). Therefore, clinical information provided by the surgeon is critical.

The anatomical subdivisions of the oesophagus are outlined below and in Figure 1:<sup>3</sup>

- The cervical oesophagus begins at the hypopharynx and extends to the thoracic inlet (at the level of the sternal notch); 150 to <200 mm from the incisors.
- Upper thoracic oesophagus extends from the thoracic inlet to the lower border of the azygos vein; 200 to <250 mm from the incisors.
- Middle thoracic oesophagus extends from the lower border of the azygos vein to the lower border of the inferior pulmonary vein; 250 to <300 mm from the incisors.
- Lower thoracic (distal) oesophagus extends from the lower border of the inferior pulmonary vein to the stomach, including the abdominal oesophagus; 300-400 mm from the incisors.
- Upper oesophagus is equal to cervical oesophagus and upper thoracic oesophagus.
- Middle oesophagus is equal to middle thoracic oesophagus.
- Lower oesophagus is equal to lower thoracic oesophagus or distal oesophagus.

In the absence of clinical information, the location of the tumour could be estimated from the relationship of the tumour to the OGJ junction by the pathologist. The epicentre/midpoint of the tumour should be considered as the point of measurement for the pathological examination. The exact distance of tumour from epicentre/midpoint to the OGJ is non-core because it is only for clinical correlation purposes.



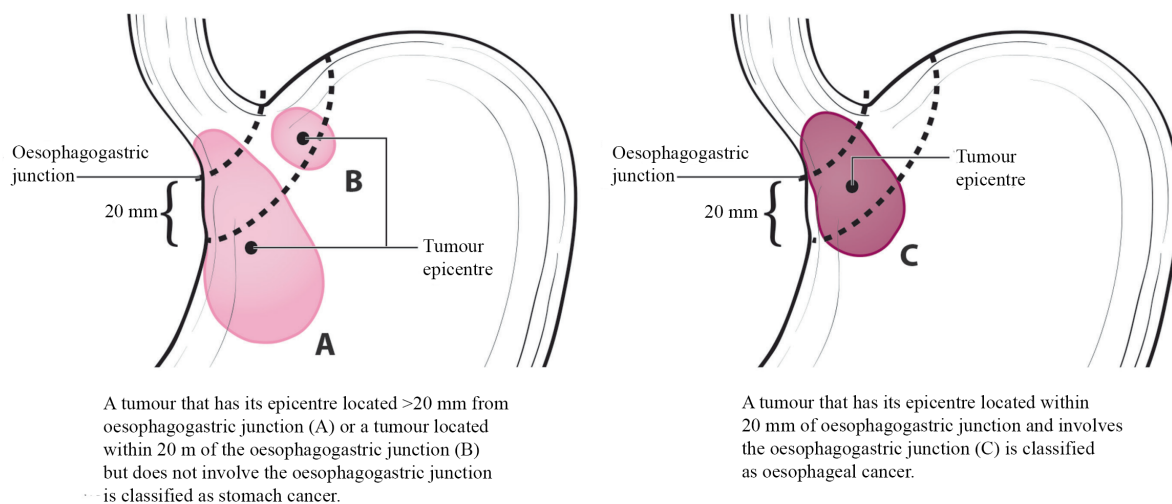


**Figure 1: Anatomic subdivisions of the oesophagus.** Modified with permission of the American College of Surgeons, Chicago, Illinois. The original source for this information is the American Joint Committee on Cancer Staging Manual, Eighth Edition (2016) published by Springer Science+Business Media.<sup>3</sup>

A description of the tumour site is ideally provided by the surgeon and should be documented by the pathologist. In addition, specific observations should be recorded by the pathologist which may help establish the exact site of origin of the tumour.

The American Joint Committee on Cancer (AJCC) and College of American Pathologists (CAP) define the OGJ as the junction of the tubular oesophagus and the stomach, irrespective of the type of epithelial lining of the oesophagus.<sup>3,14</sup>

Pure anatomical classification of the tumour site of origin can be defined in several different systems. The Siewert Classification categorises OGJ cancer into Siewert type I (tumours with their epicentre located 10-50 mm above the OGJ), type II (tumour epicentre located from 10 mm above to 20 mm below the OGJ) and type III (tumour epicentre located from 20 mm - 50 mm below the OGJ).<sup>15</sup> In the Siewert Classification, the proximal end of the gastric longitudinal mucosa folds is used as pragmatic reference for the endoscopic cardia/OGJ (zero point).<sup>15</sup> The current Union for International Cancer Control (UICC)<sup>16</sup>/AJCC<sup>3</sup> 8<sup>th</sup> edition Staging System definition of gastric cancer includes those tumours involving the OGJ but with the epicentre >20 mm into the proximal stomach and cardia cancer without involvement of the OGJ (Figure 2). Therefore, all Siewert type III tumours are classified as gastric cancer based on the UICC<sup>16</sup>/AJCC<sup>3</sup> 8<sup>th</sup> edition Staging Systems.



**Figure 2: (A) Oesophagogastric junction (OGJ) tumours with their epicentre located >20 mm into the proximal stomach are staged as stomach cancers. (B) Cardia cancers not involving the OGJ are staged as stomach cancers. (C) Tumours involving the OGJ with their epicenter <20 mm into the proximal stomach are staged as oesophageal cancer.** Modified with permission of the American College of Surgeons, Chicago, Illinois. The original source for this information is the American Joint Committee on Cancer Staging Manual, Eighth Edition (2016) published by Springer Science+Business Media.<sup>3</sup>

The UICC<sup>16</sup>/AJCC<sup>3</sup> 8<sup>th</sup> edition Staging Manuals also define tumours involving the OGJ as those with a midpoint within the proximal 20 mm of the cardia/proximal stomach and these are staged as oesophageal cancers. In contrast, tumours involving the OGJ with their epicentre more than 20 mm into the cardia/proximal stomach are staged as stomach cancers, as are all cardia/proximal stomach cancers not involving the OGJ, even if within 20 mm of the OGJ.<sup>3,16</sup>

Some proximal stomach tumours which appear to be of gastric origin, under the AJCC 8<sup>th</sup> edition Classification,<sup>3</sup> may be classified as tumours of the oesophagus and OGJ somewhat artificially and thus reported using the oesophageal dataset. When reporting such tumours, it should be noted that the tumour may have arisen within the stomach.

A tumour arising from the oesophagus with a tumour epicentre beyond the 20 mm mark is staged as a gastric tumour.

↑ Back

## Note 8 – Tumour dimensions (Core and Non-core)

Where possible, the pathologist should record the maximum longitudinal dimension of the tumour mass and the distance of the tumour midpoint from the OGJ in the oesophagus and in the stomach.

If no tumour is macroscopically visible, or for small tumours where the macroscopic dimensions may not be accurate, then the microscopic dimensions should be documented.

If the specimen is fragmented, measurements of the reconstructed tumour should be estimated, where possible. Otherwise, the clinical and/or radiological measurements should be used.

 [Back](#)

## **Note 9 – Barrett mucosa (Non-core)**

The presence of Barrett mucosa points to the aetiology of the adenocarcinoma and helps to differentiate the origin of the lesion i.e., oesophageal versus gastric. The definition of Barrett mucosa varies between countries. In many regions, the presence of goblet cells is required for the diagnosis of Barrett mucosa.

Nevertheless, it is a non-core element as Barrett mucosa may be obscured by the cancer.

 [Back](#)

## **Note 10 – Macroscopic distance of tumour to the margin (Core)**

A clear proximal resection margin may be difficult to obtain in oesophageal squamous cell carcinoma located in the upper portion. A positive resection margin is an important prognostic factor affecting survival rates.<sup>17</sup>

The distance of tumour from the closest resection margin, whether it is the distal, proximal or circumferential margin, should be recorded.

For tumours close to the resection margin an accurate macroscopic assessment may not be possible, and the microscopic measurement is used (see **Note 18 MARGIN STATUS**).

 [Back](#)

## **Note 11 – Histological tumour type (Core)**

Pathological staging is different for the two major groups of oesophageal carcinomas, adenocarcinoma and squamous cell carcinoma.<sup>3</sup> It is important to refer to the current WHO Classification of Tumours of the Digestive System, 5<sup>th</sup> edition, 2019 (Table 1) for the different oesophageal malignant neoplasms.<sup>13</sup>

Adenoid cystic carcinoma, undifferentiated carcinoma or MiNEN (the neuroendocrine component is nearly always NEC) with an adenocarcinoma component use the adenocarcinoma stage grouping.<sup>18</sup> There is no definite evidence for whether the staging of adenosquamous carcinoma or mucoepidermoid carcinoma should follow that of squamous cell carcinoma or adenocarcinoma staging groups.<sup>13</sup>

For adenocarcinoma, there are different histological patterns. In most instances, they could be grouped either into tubular, papillary and mucinous patterns. In rare circumstances, the tumour could be poorly cohesive and have either signet ring or non-signet ring pattern.

**Table 1: World Health Organization Classification of tumours of the oesophagus.<sup>13</sup>**

Descriptor	ICD-O codes <sup>a</sup>
<b>Benign epithelial tumours and precursors</b>	
Squamous cell papilloma NOS	8052/0
Squamous papillomatosis	8060/0
Oesophageal glandular dysplasia (intraepithelial neoplasia), low grade	8148/0
Oesophageal glandular dysplasia (intraepithelial neoplasia), high grade	8148/2
Oesophageal squamous intraepithelial neoplasia (dysplasia), low grade	8077/0
Oesophageal squamous intraepithelial neoplasia (dysplasia), low grade	8077/2
<b>Malignant epithelial tumours</b>	
Adenocarcinoma NOS	8140/3
Adenoid cystic carcinoma	8200/3
Mucoepidermoid carcinoma	8430/3
Adenosquamous carcinoma	8560/3
Squamous cell carcinoma NOS	8070/3
Verrucous squamous cell carcinoma	8051/3
Squamous cell carcinoma, spindle cell	8074/3
Basaloid squamous cell carcinoma	8083/3
Carcinoma, undifferentiated, NOS	8020/3
Lymphoepithelioma-like carcinoma	8082/3
Neuroendocrine tumour NOS	8240/3
Neuroendocrine tumour, grade 1	8240/3
Neuroendocrine tumour, grade 2	8249/3
Neuroendocrine tumour, grade 3	8249/3
Neuroendocrine carcinoma NOS	8246/3
Large cell neuroendocrine carcinoma	8013/3
Small cell neuroendocrine carcinoma	8041/3
Mixed neuroendocrine–non-neuroendocrine neoplasm (MiNEN)	8154/3
Combined small cell–adenocarcinoma	8045/3
Combined small cell–squamous cell carcinoma	8045/3

<sup>a</sup> These morphology codes are from the International Classification of Diseases for Oncology, Third Edition, second revision (ICD-O-3.2).<sup>19</sup> Behaviour is coded /0 for benign tumours; /1 for unspecified, borderline, or uncertain behaviour; /2 for carcinoma in situ and grade III intraepithelial neoplasia; and /3 for malignant tumours, primary site; and /6 for malignant tumours, metastatic site. Subtype labels are indented.

© World Health Organization/International Agency for Research on Cancer. Reproduced with permission.

 [Back](#)

## Note 12 – Dysplasia (Core)

There are two types of dysplasia, squamous dysplasia and columnar/glandular (either Barrett or non-Barrett) dysplasia.

In the current WHO Classification, both squamous and Barrett dysplasia are classified using a two-tiered system, high and low grade.<sup>13,20</sup> The use of the term ‘carcinoma in situ’ is not recommended.

Columnar dysplasia is mostly Barrett dysplasia. The presence of Barrett dysplasia supports oesophageal origin of an adenocarcinoma in cancer from the OGJ.

The term Barrett dysplasia in the WHO Classification is adopted because of the aetiological link with Barrett oesophagus.<sup>13</sup> However, it is noted that rare cases of oesophageal adenocarcinoma may not arise from Barrett dysplasia. For instance, some rare adenocarcinomas of the mid oesophagus have no relationship with Barrett dysplasia.<sup>13</sup>

Oesophageal columnar dysplasia is broadly divided into gastric, intestinal and mixed (hybrid) types, based on morphological and immunohistochemical features.<sup>13</sup> The clinical significance of this division is yet to be determined and is not needed for routine clinical care.

Squamous dysplasia may present adjacent to squamous carcinoma in the upper thoracic oesophagus. Due to the anatomical limit of resection, dysplasia may extend to the proximal resection margin.

 [Back](#)

## Note 13 – Histological tumour grade (Core)

Grade (differentiation) of the tumour contributes to pathological staging or pathological prognostic grouping.<sup>3</sup> Grading should be based on the most predominant grade present in the carcinoma, although there is insufficient evidence to support this.

The 5<sup>th</sup> edition of the WHO Classification has defined the morphological criteria for grading of adenocarcinoma and squamous cell carcinoma.<sup>13</sup>

In adenocarcinoma, grade 1 is defined as adenocarcinoma with >95% of the carcinoma with well-formed glands; grade 2 with 50% to 95% with well-formed glands; grade 3 is <50% with glandular formation.<sup>18</sup>

In squamous cell carcinoma, grade 1 to grade 3 depends on the amount of keratin pearls, cytological atypia, mitotic activity and proportion of basaloid cells.<sup>21</sup>

The three-tiered grading is preferred to the two-tiered system as each grade may have an impact on early staged oesophageal cancers not treated by pre-operative adjuvant therapy based on AJCC stage grouping.<sup>3</sup>

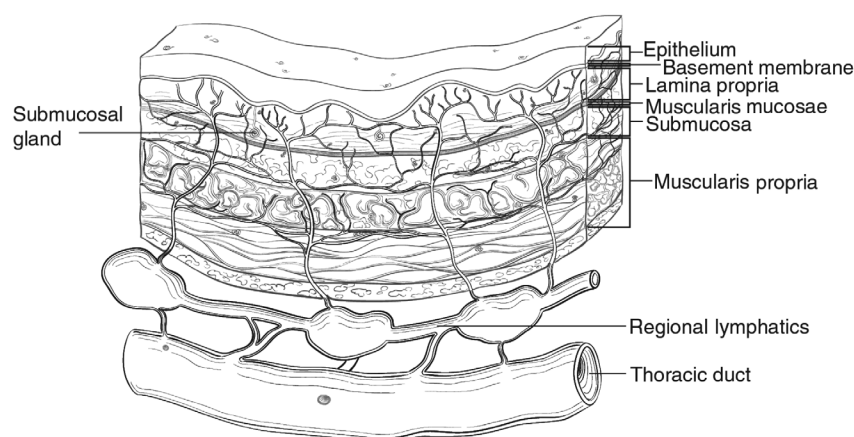
It is acknowledged that after neoadjuvant therapy, it may be difficult to grade the carcinoma. However, this does not impact pathological staging.

Histological tumour grade is applicable to squamous cell carcinoma and adenocarcinoma only.

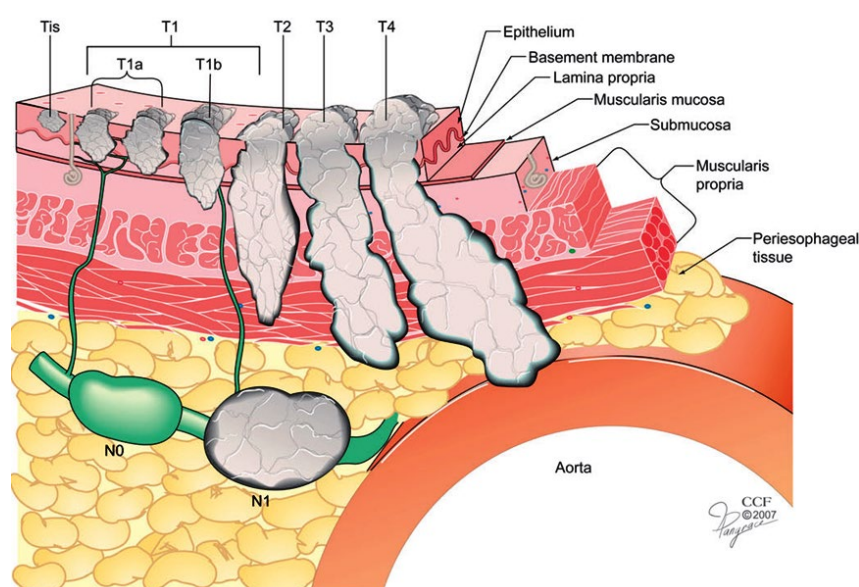
 [Back](#)

## Note 14 – Extent of invasion (Core)

The UICC<sup>16</sup>/AJCC<sup>3</sup> 8<sup>th</sup> edition Staging Manuals divide T stage into T1a and T1b. T1a refers to invasion into the lamina propria or muscularis mucosae whereas T1b involves the submucosa (Figures 3 and 4). Thus, the extent of invasion should be recorded accurately.



**Figure 3: Microscopic anatomy of the oesophagus.** Used with permission of the American College of Surgeons, Chicago, Illinois. The original source for this information is the American Joint Committee on Cancer Staging Manual, Eighth Edition (2016) published by Springer Science+Business Media.<sup>3</sup>



**Figure 4: Anatomic cancer classification is by depth of cancer invasion (T) and regional lymph node classification (N), defined by absence (N0) or presence (N1) of cancer-positive lymph nodes. Distant metastasis (M) not illustrated.** Reproduced with permission from Ishwaran H et al (2009). A novel approach to cancer staging: application to oesophageal cancer. *Biostatistics* 10(4):603-620 by permission of Oxford University Press.<sup>22</sup>

↑ Back

## Note 15 – Lymphovascular invasion (Core)

Lymphovascular invasion is a known poor prognostic factor in oesophageal carcinomas and is designated a core element.<sup>13,23</sup>

The value of subdividing lymphovascular invasion into large vessel (venous) and small vessels (lymphatic, capillary and venular) has not been investigated. However, recording of this type of data will be useful to aid further investigation. Identifying invasion into the extramural veins is important.

[↑ Back](#)

## Note 16 – Perineural invasion (Non-core)

The existence of perineural infiltration after neoadjuvant treatment is closely associated with poor prognosis and could be utilised along with the Tumour-Node-Metastasis (TNM) staging system for better discrimination between patients with oesophageal squamous cell carcinoma or adenocarcinoma.<sup>23,24</sup> However, as more studies are needed to validate the impact of perineural invasion, it is designated as a non-core element.

[↑ Back](#)

## Note 17 – Response to neoadjuvant therapy (Core)

There are two commonly used systems to assess tumour regression grade (Table 2). One very common method employed to assess tumour regression is the Mandard Classification system.<sup>25</sup> This five-tiered system divides tumour regression into five grades based on the proportion of viable tumour tissue present in relation to fibrosis.<sup>25</sup>

There is also a four-tiered system (Becker system) recommended by some authors for having a better reproducibility for pathological assessment (Table 2).<sup>26</sup> This system depends on the proportion of residual cancer cells present by percentage.

The modified Ryan system<sup>27</sup> proposed by the CAP<sup>14</sup> (Table 3), recognises four grades based on the proportion of residual tumour in a descriptive manner, but this is less commonly adopted in oesophageal cancers.

Although many studies have evaluated and compared these schemes in assessing treatment response in gastrointestinal carcinomas after neoadjuvant therapy, there is no consensus on the optimal way to stratify tumour regression grades. In addition, the inter- and intra-observer variability is high in most schemes. Nevertheless, response to neoadjuvant therapy should be reported, as assessment of histological tumour regression may provide valuable prognostic information and impact on the choice of postoperative therapy.<sup>26</sup> Patients with complete tumour regression have significantly better overall survival compared to patients with residual adenocarcinoma. As there is no current consensus on grading schemes, the three most commonly used systems have been provided by the ICCR Carcinoma of the Oesophagus Dataset Authoring Committee.<sup>6,25,27</sup> Subjective elements in interpretation are difficult to avoid. Further comparative studies are needed.

However, regardless of the system used, it is important to assess the tumour regression grade as it is associated with prognosis in patients with oesophageal carcinomas.<sup>6,10,13,28</sup>

**Table 2: The Mandard and Becker systems for assessing the tumour regression grade (TRG) of carcinoma after neoadjuvant therapy.**

Mandard	Becker
<b>TRG 1:</b> Absence of residual cancer, with fibrosis extending through the various layers of the oesophageal wall (complete regression)	<b>TRG 1a:</b> No residual carcinoma present
<b>TRG 2:</b> Rare residual cancer cells scattered through the fibrosis	<b>TRG 1b:</b> <10% residual carcinoma present
<b>TRG 3:</b> An increase in the number of residual cancer cells, but fibrosis still predominates	<b>TRG 2:</b> 10-50% residual carcinoma present
<b>TRG 4:</b> Residual cancer outgrowing fibrosis	<b>TRG 3:</b> >50% residual carcinoma present
<b>TRG 5:</b> Absence of regressive changes	

Modified with permission from Lam AK and Kumarasinghe MP (2019). Adenocarcinoma of the oesophagus and oesophagogastric junction not otherwise specified (NOS) In: Odze RD et al (2019). Tumours of the oesophagus. In: *Digestive System Tumours. World Health Organization Classification of Tumours, 5th Edition*, Lokuhetty D, White V, Watanabe R and Cree IA (eds), IARC Press, Lyon, France.<sup>13</sup>

© World Health Organization/International Agency for Research on Cancer. Reproduced with permission.

**Table 3: Modified Ryan scheme for tumour regression grading system.**<sup>14,27</sup>

Description	Tumour Regression Score
No viable cancer cells (complete response)	0
Single cells or rare small groups of cancer cells (near complete response)	1
Residual cancer with evident tumour regression, but more than single cells or rare small groups of cancer cells (partial response)	2
Extensive residual cancer with no evident tumour regression (poor or no response)	3

Reproduced with permission from Ryan R et al (2005). Pathological response following long-course neoadjuvant chemoradiotherapy for locally advanced rectal cancer. *Histopathology* 47(2):141-146.<sup>27</sup>

[!\[\]\(e8fb589d58dad1692debababa5e928b6\_img.jpg\) Back](#)



## Note 18 – Margin status (Core)

The proximal resection margin is important in oesophageal squamous cell carcinoma due to the anatomical limit for resection and may be difficult to achieve a negative margin in patients with cancer in the upper oesophagus.

In many studies, the circumferential margin is associated with a poorer outcome for patients with oesophageal carcinomas.<sup>29,30</sup>

There is controversy in defining when to call a circumferential margin positive, with some labelling margins of <1 mm positive and others defining it as the presence of tumour cells at the resection margin.<sup>31</sup> No consensus has been reached. When patients with a positive circumferential margin via either definition were compared with those with a margin clearance of >1 mm, overall survival was significantly prolonged in the latter.<sup>32</sup>

For multifocal tumours, the presence of a positive margin in any tumours should be indicated as 'positive', and the closest margin can be measured from any tumours in the specimen.

 **Back**

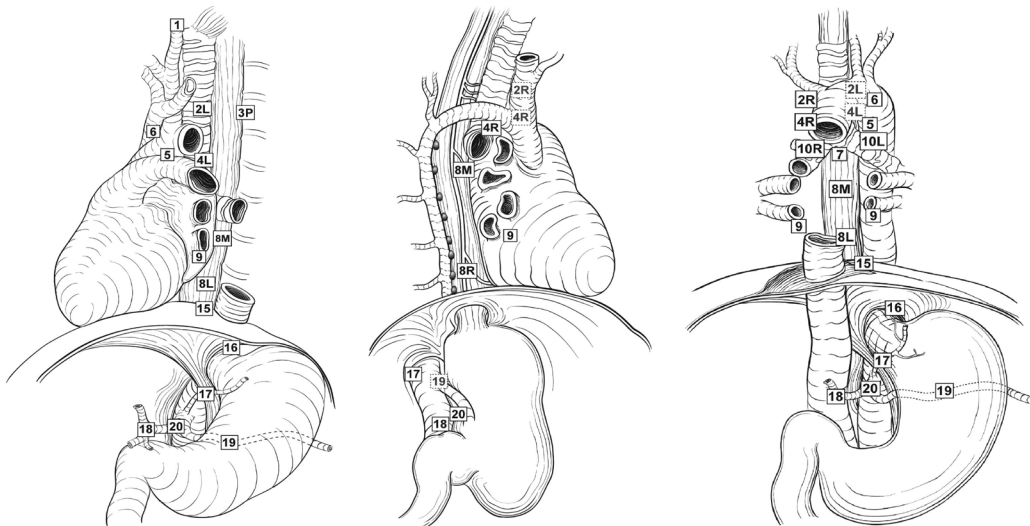
## Note 19 – Lymph node status (Core and Non-core)

The number of lymph nodes infiltrated by carcinoma is a core element. More important is the minimum number of lymph nodes sampled for accurate assessment. The UICC<sup>16</sup>/AJCC<sup>3</sup> Classification system N3, is seven or more lymph nodes.

According to UICC<sup>16</sup>/AJCC<sup>3</sup> 8<sup>th</sup> editions, although it is suggested that at least 16 regional lymph nodes (Figure 5) be removed and assessed pathologically, removal and evaluation of greater than or equal to 30 nodes is desirable due to the prognostic value of increased nodal yield on overall survival.<sup>10,33,34</sup>

The presence or absence of regressive changes observed in lymph node metastases could be recorded, as there is some evidence that this has a prognostic impact.<sup>35-38</sup>

Like the situation in squamous cell carcinomas in the head and neck region, extranodal extension in oesophageal squamous carcinoma was shown to have prognostic impact for patients.<sup>39</sup> Nevertheless, more studies are needed to validate the use of extranodal extension as a prognostic marker, and it is therefore a non-core element.



**Figure 5: Regional lymph nodes of the oesophagus.** Used with permission of the American College of Surgeons, Chicago, Illinois. The original source for this information is the American Joint Committee on Cancer Staging Manual, Eighth Edition (2016) published by Springer Science+Business Media.<sup>3</sup>

↑ Back

## Note 20 – Coexistent pathology (Non-core)

Common coexisting pathology other than Barrett oesophagus may include scar tissue, leiomyoma, squamous papilloma, etc.

↑ Back

## Note 21 – Ancillary studies (Core and Non-core)

For oesophageal NECs including MiNENs, the reporting of neuroendocrine marker expression and Ki-67 proliferation index are core elements. These elements are non-core for other types of oesophageal carcinomas.

Neuroendocrine neoplasms are classified into NETs, NECs and MiNENs. NETs are graded 1-3 using the mitotic count and Ki-67 proliferation index.<sup>13</sup> However, pure NETs are not considered within the scope of this dataset. Most NECs show marked cytological atypia, brisk mitotic activity, and are subclassified into small cell and large cell subtypes.<sup>13</sup> NECs are considered high grade by definition. MiNENs are usually composed of a poorly differentiated NEC component and an adenocarcinoma component. If a pure or mixed NEC is suspected on morphology, immunohistochemistry is required to confirm neuroendocrine differentiation, usually applying synaptophysin and chromogranin A as a minimum.<sup>13</sup>

HER2 is important for planning therapy for metastatic or unresectable OGJ adenocarcinoma. It should be tested by immunohistochemistry and could be confirmed by in situ hybridisation.<sup>13</sup>

PD-L1 or microsatellite instability markers are helpful in predicting response to immunotherapy. They may be considered if immunotherapy is to be used for treatment of advanced oesophageal carcinoma.

**↑ Back**

## **Note 22 – Histologically confirmed distant metastases (Core)**

The presence of distant metastases is one of the most important parameters for staging of patients with oesophageal carcinomas.<sup>3,16</sup>

Biopsy of the distant site to confirm metastases could be received during operation of the primary tumour. It is worth finding out whether there is also biopsy proven distant metastases before the operation.

**↑ Back**

## **Note 23 – Pathological staging (Core)**

Pathological staging (according to the agreed criteria of the UICC<sup>16</sup> and AJCC<sup>3</sup> 8<sup>th</sup> editions) is the most important factor to predict the survival of patients with oesophageal carcinomas.

It is worth noting that although the pathological criteria T, N, M remain the same, the stage grouping is different from squamous cell carcinoma and adenocarcinoma.<sup>3</sup> Stage grouping tables have therefore been provided for reference (Tables 4-7) for the AJCC 8<sup>th</sup> edition staging of oesophageal adenocarcinomas and squamous cell carcinomas with or without neoadjuvant therapy.<sup>3</sup> The differentiation (grades) of the carcinomas are important criteria for the stage grouping for patients without receiving neoadjuvant therapy, before oesophagogastrectomy.

On the other hand, in the AJCC 8<sup>th</sup> edition Staging Manual there is only one staging grouping for both squamous cell carcinoma and adenocarcinoma after receiving neoadjuvant therapy.<sup>3</sup> In this group of carcinomas, the grade is not a criterion for the stage grouping.<sup>3,18,21</sup>

**Table 4: American Joint Committee on Cancer Pathological (pTNM) – Squamous cell carcinoma.**

When pT is...	And pN is...	And M is...	And G is...	And location is...	Then the stage group is...
Tis	N0	M0	N/A	Any	0
T1a	N0	M0	G1	Any	IA
T1a	N0	M0	G2-3	Any	IB
T1a	N0	M0	GX	Any	IA
T1b	N0	M0	G1-3	Any	IB
T1b	N0	M0	GX	Any	IB
T2	N0	M0	G1	Any	IB
T2	N0	M0	G2-3	Any	IIA
T2	N0	M0	GX	Any	IIA
T3	N0	M0	G1-3	Lower	IIA
T3	N0	M0	G1	Upper/middle	IIA
T3	N0	M0	G2-3	Upper/middle	IIB
T3	N0	M0	GX	Lower/upper/middle	IIB
T3	N0	M0	Any	Location X	IIB
T1	N1	M0	Any	Any	IIB
T1	N2	M0	Any	Any	IIIA
T2	N1	M0	Any	Any	IIIA
T2	N2	M0	Any	Any	IIIB
T3	N1-2	M0	Any	Any	IIIB
T4a	N0-1	M0	Any	Any	IIIB
T4a	N2	M0	Any	Any	IVA
T4b	N0-2	M0	Any	Any	IVA
Any T	N3	M0	Any	Any	IVA
Any T	Any N	M1	Any	Any	IVB

Used with permission of the American College of Surgeons, Chicago, Illinois. The original source for this information is the American Joint Committee on Cancer Staging Manual, Eighth Edition (2016) published by Springer Science+Business Media.<sup>3</sup>

**Table 5: American Joint Committee on Cancer Postneoadjuvant Therapy (ypTNM) – Squamous cell carcinoma.**

When yp T is...	And yp N is...	And M is...	Then the stage group is...
T0-2	N0	M0	I
T3	N0	M0	II
T0-2	N1	M0	IIIA
T3	N1	M0	IIIB
T0-3	N2	M0	IIIB
T4a	N0	M0	IIIB
T4a	N1-2	M0	IVA
T4a	NX	M0	IVA
T4b	N0-2	M0	IVA
Any T	N3	M0	IVA
Any T	Any N	M1	IVB

Used with permission of the American College of Surgeons, Chicago, Illinois. The original source for this information is the American Joint Committee on Cancer Staging Manual, Eighth Edition (2016) published by Springer Science+Business Media.<sup>3</sup>

**Table 6: American Joint Committee on Cancer Pathological (pTNM) – Adenocarcinoma.**

When pT is...	And pN is...	And M is...	And G is...	Then the stage group is...
Tis	N0	M0	N/A	0
T1a	N0	M0	G1	IA
T1a	N0	M0	GX	IA
T1a	N0	M0	G2	IB
T1b	N0	M0	G1-2	IB
T1b	N0	M0	GX	IB
T1	N0	M0	G3	IC
T2	N0	M0	G1-2	IC
T2	N0	M0	G3	IIA
T2	N0	M0	GX	IIA
T1	N1	M0	Any	IIB
T3	N0	M0	Any	IIB
T1	N2	M0	Any	IIIA
T2	N1	M0	Any	IIIA
T2	N2	M0	Any	IIIB
T3	N1-2	M0	Any	IIIB
T4a	N0-1	M0	Any	IIIB
T4a	N2	M0	Any	IVA
T4b	N0-2	M0	Any	IVA
Any T	N3	M0	Any	IVA
Any T	Any N	M1	Any	IVB

Used with permission of the American College of Surgeons, Chicago, Illinois. The original source for this information is the American Joint Committee on Cancer Staging Manual, Eighth Edition (2016) published by Springer Science+Business Media.<sup>3</sup>

**Table 7: American Joint Committee on Cancer Postneoadjuvant Therapy (ypTNM) – Adenocarcinoma.**

When yp T is...	And yp N is...	And M is...	Then the stage group is...
T0-2	N0	M0	I
T3	N0	M0	II
T0-2	N1	M0	IIIA
T3	N1	M0	IIIB
T0-3	N2	M0	IIIB
T4a	N0	M0	IIIB
T4a	N1-2	M0	IVA
T4a	NX	M0	IVA
T4b	N0-2	M0	IVA
Any T	N3	M0	IVA
Any T	Any N	M1	IVB

Used with permission of the American College of Surgeons, Chicago, Illinois. The original source for this information is the American Joint Committee on Cancer Staging Manual, Eighth Edition (2016) published by Springer Science+Business Media.<sup>3</sup>

 **Back**

## References

- 1 Merlin T, Weston A and Tooher R (2009). Extending an evidence hierarchy to include topics other than treatment: revising the Australian 'levels of evidence'. *BMC Med Res Methodol* 9:34.
- 2 International Collaboration on Cancer Reporting (2021). *Endoscopic Resection of the Oesophagus and Oesophagogastric Junction Histopathology Reporting Guide, 2nd Edition*. Available from: <http://www.iccr-cancer.org/datasets/published-datasets/digestive-tract/endoscopic-resection-of-the-oesophagus> (Accessed 20th December 2021).
- 3 Amin MB, Edge SB, Greene FL, Byrd DR, Brookland RK, Washington MK, Gershenwald JE, Compton CC, Hess KR, Sullivan DC, Jessup JM, Brierley JD, Gaspar LE, Schilsky RL, Balch CM, Winchester DP, Asare EA, Madera M, Gress DM and Meyer LR (eds) (2017). *AJCC Cancer Staging Manual. 8th Edition*, Springer, New York.
- 4 Mayr P, Martin B, Fries V, Claus R, Anthuber M, Messmann H, Schenkirsch G, Blodow V, Kahl KH and Stüben G (2020). Neoadjuvant and Definitive Radiochemotherapeutic Approaches in Esophageal Cancer: A Retrospective Evaluation of 122 Cases in Daily Clinical Routine. *Oncol Res Treat* 43(7-8):372-379.
- 5 Noble F, Nolan L, Bateman AC, Byrne JP, Kelly JJ, Bailey IS, Sharland DM, Rees CN, Iveson TJ, Underwood TJ and Bateman AR (2013). Refining pathological evaluation of neoadjuvant therapy for adenocarcinoma of the esophagus. *World J Gastroenterol* 19(48):9282-9293.

- 6 Langer R, Becker K, Zlobec I, Gertler R, Sisic L, Buchler M, Lordick F, Slotta-Huspenina J, Weichert W, Hofler H, Feith M and Ott K (2014). A multifactorial histopathologic score for the prediction of prognosis of resected esophageal adenocarcinomas after neoadjuvant chemotherapy. *Ann Surg Oncol* 21(3):915-921.
- 7 Karamitopoulou E, Thies S, Zlobec I, Ott K, Feith M, Slotta-Huspenina J, Lordick F, Becker K and Langer R (2014). Assessment of tumor regression of esophageal adenocarcinomas after neoadjuvant chemotherapy: comparison of 2 commonly used scoring approaches. *Am J Surg Pathol* 38(11):1551-1556.
- 8 Hatogai K, Fujii S, Kojima T, Daiko H, Kadota T, Fujita T, Yoshino T, Doi T, Takiguchi Y and Ohtsu A (2016). Prognostic significance of tumor regression grade for patients with esophageal squamous cell carcinoma after neoadjuvant chemotherapy followed by surgery. *J Surg Oncol* 113(4):390-396.
- 9 Xiang M, Chang DT, Heestand GM and Pollom EL (2020). Survival after neoadjuvant approaches to gastroesophageal junction cancer. *Gastric Cancer* 23(1):175-183.
- 10 Kadota T, Hatogai K, Yano T, Fujita T, Kojima T, Daiko H and Fujii S (2018). Pathological tumor regression grade of metastatic tumors in lymph node predicts prognosis in esophageal cancer patients. *Cancer Sci* 109(6):2046-2055.
- 11 Jamieson G, Lamb P and Thompson S (2009). The Role of Lymphadenectomy in Esophageal Cancer. *Ann Surg* 250:206-209.
- 12 Fujita H, Sueyoshi S, Tanaka T, Fujii T, Toh U, Mine T, Sasahara H, Sudo T, Matono S, Yamana H and Shirouzu K (2003). Optimal lymphadenectomy for squamous cell carcinoma in the thoracic esophagus: comparing the short- and long-term outcome among the four types of lymphadenectomy. *World J Surg* 27(5):571-579.
- 13 Odze RD, Lam AK, Ochiai A and Washington MK (2019). Tumours of the oesophagus. In: *Digestive System Tumours. WHO Classification of Tumours, 5th Edition.*, Lokuhetty D, White V, Watanabe R and Cree IA (eds), IARC Press, Lyon.
- 14 Protocol for the examination of specimens from patients with carcinoma of the esophagus (2021). *Protocol for the examination of specimens from patients with carcinoma of the esophagus*. Available from: [https://documents.cap.org/protocols/Esophagus\\_4.2.0.0.REL\\_CAPCP.pdf](https://documents.cap.org/protocols/Esophagus_4.2.0.0.REL_CAPCP.pdf) (Accessed 4th November 2021).
- 15 Stein HJ, Feith M and Siewert JR (2000). Cancer of the esophagogastric junction. *Surg Oncol* 9(1):35-41.
- 16 Brierley JD, Gospodarowicz MK and Wittekind C (eds) (2016). *Union for International Cancer Control. TNM Classification of Malignant Tumours, 8th Edition*, Wiley, USA.
- 17 Wang YC, Deng HY, Wang WP, He D, Ni PZ, Hu WP, Wang ZQ and Chen LQ (2016). Positive esophageal proximal resection margin: an important prognostic factor for esophageal cancer that warrants adjuvant therapy. *J Thorac Dis* 8(9):2512-2518.

- 18 Lam AK (2018). Application of pathological staging in esophageal adenocarcinoma. *Methods Mol Biol* 1756:93-103.
- 19 Fritz A, Percy C, Jack A, Shanmugaratnam K, Sobin L, Parkin DM and Whelan S (eds) (2020). *International Classification of Diseases for Oncology, Third Edition, Second Revision ICD-O-3.2*. Available from: [http://www.iacr.com.fr/index.php?option=com\\_content&view=category&layout=blog&id=100&Itemid=577](http://www.iacr.com.fr/index.php?option=com_content&view=category&layout=blog&id=100&Itemid=577) (Accessed 17th November 2021).
- 20 Lam AK (2020). Updates on World Health Organization classification and staging of esophageal tumors: implications for future clinical practice. *Hum Pathol* 108:100-112.
- 21 Lam AK (2020). Application of pathological staging in esophageal squamous cell carcinoma. *Methods Mol Biol* 2129:19-31.
- 22 Ishwaran H, Blackstone EH, Apperson-Hansen C and Rice TW (2009). A novel approach to cancer staging: application to esophageal cancer. *Biostatistics* 10(4):603-620.
- 23 Lagarde SM, Phillips AW, Navidi M, Disep B, Immanuel A and Griffin SM (2015). The presence of lymphovascular and perineural infiltration after neoadjuvant therapy and oesophagectomy identifies patients at high risk for recurrence. *Br J Cancer* 113(10):1427-1433.
- 24 Hsu PK, Chien LI, Lin CH, Yeh YC, Chuang CY, Hsu HS, Wu YC and Hsu CP (2019). Impact of perineural invasion as a histopathological prognostic factor in ypStage II/III oesophageal squamous cell carcinoma. *Eur J Cardiothorac Surg* 55(5):927-933.
- 25 Mandard AM, Dalibard F, Mandard JC, Marnay J, Henry-Amar M, Petiot JF, Roussel A, Jacob JH, Segol P, Samama G, Ollivier J-M, Bonvalot S and Gignoux M (1994). Pathologic assessment of tumor regression after preoperative chemoradiotherapy of esophageal carcinoma. Clinicopathologic correlations. *Cancer* 73(11):2680-2686.
- 26 Langer R and Becker K (2018). Tumor regression grading of gastrointestinal cancers after neoadjuvant therapy. *Virchows Arch* 472(2):175-186.
- 27 Ryan R, Gibbons D, Hyland JM, Treanor D, White A, Mulcahy HE, O'Donoghue DP, Moriarty M, Fennelly D and Sheahan K (2005). Pathological response following long-course neoadjuvant chemoradiotherapy for locally advanced rectal cancer. *Histopathology* 47(2):141-146.
- 28 Noble F, Lloyd MA, Turkington R, Griffiths E, O'Donovan M, O'Neill JR, Mercer S, Parsons SL, Fitzgerald RC and Underwood TJ (2017). Multicentre cohort study to define and validate pathological assessment of response to neoadjuvant therapy in oesophagogastric adenocarcinoma. *Br J Surg* 104(13):1816-1828.
- 29 Yang YS, Wang YC, Deng HY, Yuan Y, Wang ZQ, He D and Chen LQ (2018). Prognostic value of circumferential resection margin in T3N0M0 esophageal squamous cell carcinoma. *Ann Transl Med* 6(15):303.



- 30 Patrao AS, Papaxoinis G, Kordatou Z, Weaver JM, Owen-Holt V, Alkhaffaf B, Galloway S and Mansoor W (2019). Prognostic significance of positive circumferential resection margin post neoadjuvant chemotherapy in patients with esophageal or gastro-esophageal junction adenocarcinoma. *Eur J Surg Oncol* 45(3):439-445.
- 31 Karstens KF, Izbicki JR and Reeh M (2018). Does the Margin Matter in Esophageal Cancer. *Dig Surg* 35(3):196-203.
- 32 Rao VS, Yeung MM, Cooke J, Salim E and Jain PK (2012). Comparison of circumferential resection margin clearance criteria with survival after surgery for cancer of esophagus. *J Surg Oncol* 105(8):745-749.
- 33 Visser E, Edholm D, Smithers BM, Thomson IG, Burmeister BH, Walpole ET, Gotley DC, Joubert WL, Atkinson V, Mai T, Thomas JM and Barbour AP (2018). Neoadjuvant chemotherapy or chemoradiotherapy for adenocarcinoma of the esophagus. *J Surg Oncol* 117(8):1687-1696.
- 34 Ajani JA, Bentrem DJ, Besh S, D'Amico TA, Das P, Denlinger C, Fakih MG, Fuchs CS, Gerdes H, Glasgow RE, Hayman JA, Hofstetter WL, Ilson DH, Keswani RN, Kleinberg LR, Korn WM, Lockhart AC, Meredith K, Mulcahy MF, Orringer MB, Posey JA, Sasson AR, Scott WJ, Strong VE, Varghese TK, Jr., Warren G, Washington MK, Willett C, Wright CD, McMillian NR and Sundar H (2013). Gastric cancer, version 2.2013: featured updates to the NCCN Guidelines. *J Natl Compr Canc Netw* 11(5):531-546.
- 35 Philippon A, Bollschweiler E, Kunikata A, Plum P, Schmidt C, Favi F, Drebber U and Holscher AH (2016). Prognostic Relevance of Lymph Node Regression After Neoadjuvant Chemoradiation for Esophageal Cancer. *Semin Thorac Cardiovasc Surg* 28(2):549-558.
- 36 Nieman DR, Peyre CG, Watson TJ, Cao W, Lunt MD, Lada MJ, Han MS, Jones CE and Peters JH (2015). Neoadjuvant treatment response in negative nodes is an important prognosticator after esophagectomy. *Ann Thorac Surg* 99(1):277-283.
- 37 Davies AR, Myoteri D, Zylstra J, Baker CR, Wulaningsih W, Van Hemelrijck M, Maisey N, Allum WH, Smyth E, Gossage JA, Lagergren J, Cunningham D and Green M (2018). Lymph node regression and survival following neoadjuvant chemotherapy in oesophageal adenocarcinoma. *Br J Surg* 105(12):1639-1649.
- 38 Bollschweiler E, Holscher AH, Metzger R, Besch S, Monig SP, Baldus SE and Drebber U (2011). Prognostic significance of a new grading system of lymph node morphology after neoadjuvant radiochemotherapy for esophageal cancer. *Ann Thorac Surg* 92(6):2020-2027.
- 39 Okada N, Daiko H, Kanamori J, Sato A, Horikiri Y, Sato T, Fujiwara H, Tomioka T, Fujita T, Kojima T and Fujii S (2019). Impact of pathologically assessing extranodal extension in the thoracic field on the prognosis of esophageal squamous cell carcinoma. *Surgery* 165(6):1203-1210.