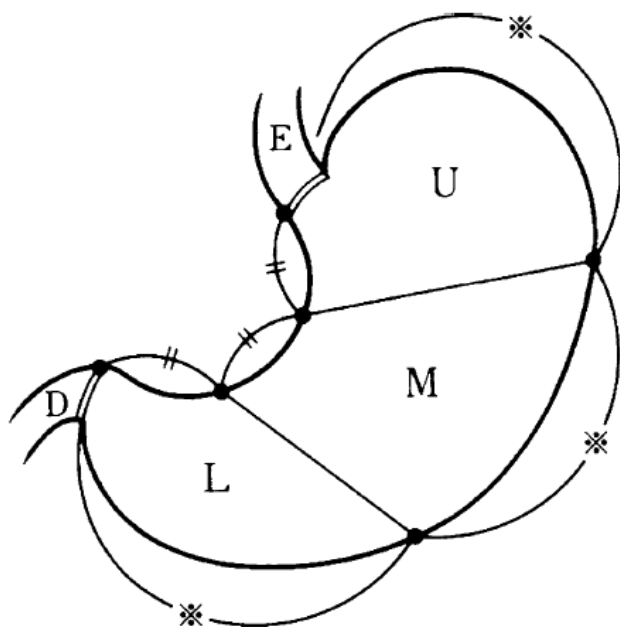


## Tumour site (Core)

The stomach is divided into the cardia, fundus, body, antrum and pylorus, but these regions are difficult to define macroscopically, which is especially true for the cardia and fundus. The Japanese Gastric Cancer Association (JGCA) guidelines divide the stomach into upper third, middle third and distal third by the lines connecting the trisected points on the lesser and greater curvatures (Figure 1).<sup>1</sup> Primary gastric cancer located in the upper third of the stomach, especially at the oesophagogastric junction (OGJ)/cardia, are reported to be more aggressive and associated with a poor prognosis.<sup>2</sup>



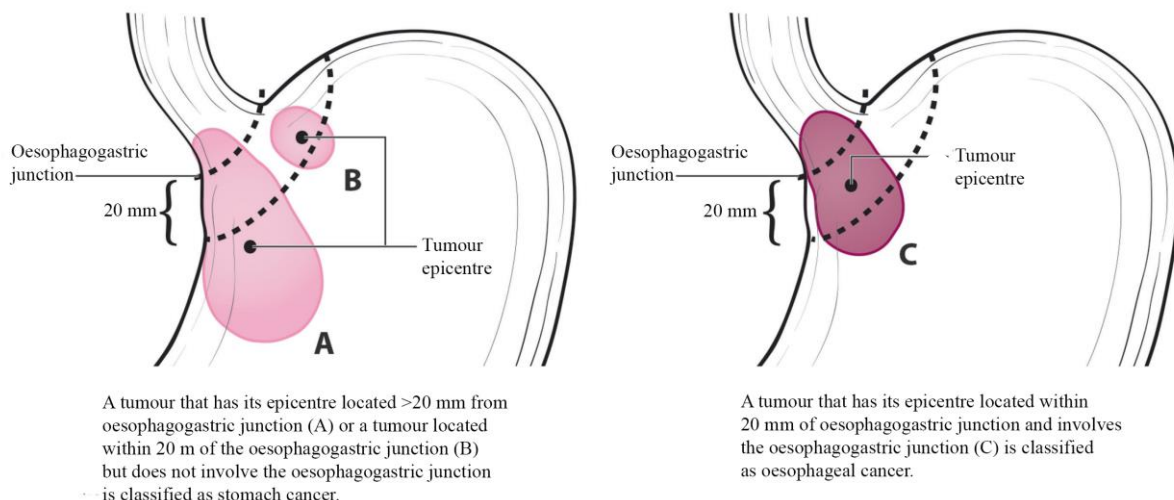
**Figure 1: The stomach can be divided into 3 portions: upper third (U), middle third (M) and distal third (L). (E) oesophagus and (D) duodenum.** Reproduced with permission from Japanese Gastric Cancer Association (2011). *Japanese classification of gastric carcinoma: 3rd English Edition*. Springer; London.<sup>1</sup>

The OGJ is defined as the border between the oesophageal and gastric muscles, irrespective of the type of epithelial lining of the oesophagus. However, it can be challenging to determine the exact location of the OGJ, especially in individuals with conditions affecting OGJ landmarks. Four methods have been proposed to locate the OGJ anatomically:<sup>1-3</sup>

1. The distal end of the longitudinal palisading small vessels in the lower oesophagus. It can be seen endoscopically as well as microscopically and is commonly used by Japanese pathologists. However, it can be obscured by inflammation.
2. The horizontal level of the angle of His (defined as starting from the peritoneal reflection of the stomach onto the diaphragm), as shown by barium meal examination. It can be altered by hiatal hernia or tumour invasion.
3. The proximal end of the gastric longitudinal mucosal folds, which is the most commonly used definition by endoscopists in Western countries. However, it can be obscured by the presence of gastric mucosal atrophy (i.e., post chemoradiation therapy and atrophic gastritis) or a large gastric mass.
4. The level of the macroscopic calibre changes of the resected oesophagus and stomach.

The current recommendation is to use the proximal end of the gastric longitudinal mucosal folds as the landmark for the OGJ. If it cannot be identified, use the distal end of the longitudinal palisading small vessels.

The Siewert classification categorises OGJ cancer into Siewert type I (tumours with their epicentre located 1-5 cm above the OGJ), type II (tumour epicentre located from 1 cm above to 2 cm below the OGJ) and type III (tumour epicentre located from 2 cm - 5 cm below the OGJ).<sup>4</sup> In the Siewert classification, the proximal end of the gastric longitudinal mucosa folds is used as pragmatic reference for the endoscopic cardia/OGJ (zero point).<sup>4</sup> The current Union for International Cancer Control (UICC)<sup>5</sup>/American Joint Committee on Cancer (AJCC)<sup>6</sup> 8<sup>th</sup> Edition Staging System definition of gastric cancer includes those tumours involving the OGJ but with the epicentre >2 cm into the proximal stomach and cardia cancer without involvement of the OGJ (Figure 2).<sup>6</sup> Therefore, all Siewert type III and some Siewert type II tumours are classified as gastric cancer based on the UICC/AJCC 8<sup>th</sup> Edition Staging Systems.<sup>5,6</sup>



**Figure 2: (A) Oesophagogastric junction (OGJ) tumours with their epicentre located >2 cm into the proximal stomach are staged as stomach cancers. (B) Cardia cancers not involving the OGJ are staged as stomach cancers. (C) Tumours involving the OGJ with their epicentre <2 cm into the proximal stomach are staged as esophageal cancer.** Used with permission of the American College of Surgeons, Chicago, Illinois. The original source for this information is the American Joint Committee on Cancer Staging Manual, Eighth Edition (2016) published by Springer Science+Business Media.<sup>6</sup>

## References

- 1 Sano T and Kodera Y (2011). Japanese classification of gastric carcinoma: 3rd English Edition. *Gastric Cancer* 14(2):101-112.
- 2 Petrelli F, Ghidini M, Barni S, Steccanella F, Sgroi G, Passalacqua R and Tomasello G (2017). Prognostic role of primary tumor location in non-metastatic gastric cancer: a systematic review and meta-analysis of 50 studies. *Ann Surg Oncol* 24(9):2655-2668.
- 3 Huang Q (2011). Definition of the esophagogastric junction: a critical mini review. *Arch Pathol Lab Med* 135(3):384-389.
- 4 Stein HJ, Feith M and Siewert JR (2000). Cancer of the esophagogastric junction. *Surg Oncol* 9(1):35-41.
- 5 Brierley JD, Gospodarowicz MK and Wittekind C (eds) (2016). *Union for International Cancer Control. TNM Classification of Malignant Tumours, 8th Edition*, Wiley-Blackwell, USA.
- 6 Amin MB, Edge SB, Greene FL, Byrd DR, Brookland RK, Washington MK, Gershenwald JE, Compton CC, Hess KR, Sullivan DC, Jessup JM, Brierley JD, Gaspar LE, Schilsky RL, Balch CM, Winchester DP, Asare EA, Madera M, Gress DM and Meyer LR (eds) (2017). *AJCC Cancer Staging Manual. 8th Edition*, Springer, New York.