

Tumour dimensions (Core)

Reasons for accurate tumour measurement

Measurement of tumour dimensions in cervical carcinomas is important for accurate FIGO staging of early cervical cancers, patient management and patient prognostication. Tumours should be measured in mm in three dimensions, namely two measurements of horizontal extent and the depth of invasion (Figure 1). There are multiple problems with regard to measuring cervical tumours and these are discussed in detail in this section. In addition, it may not be possible to provide accurate tumour dimensions in fragmented or thermally damaged specimens. In situations where the tumour extends to resection margins, the tumour dimensions should be qualified by use of the term 'at least' to indicate that the measurements may not indicate the true/final tumour size.

In most datasets, separate gross and microscopic measurements are mandated but this may result in confusion if different measurements are given. Some tumours (especially larger ones) are more accurately measured grossly while others (especially smaller tumours and some larger tumours with a diffusely infiltrative pattern or with marked tumour associated fibrosis) are best measured (or can only be measured) microscopically. In this dataset, separate gross and microscopic measurements are not included but rather one set of measurements is required which is based on a correlation of the gross and microscopic features with gross examination being more important in some cases and microscopic examination in others. A few other points are emphasised:-

1. In providing the final tumour dimensions, the measurements in any prior specimens, for example loop/cone excisions, will need to be taken into account. Although it may overestimate the maximum horizontal extent, it is recommended to add together the maximum horizontal measurement in different specimens when calculating the final horizontal extent. The depth of invasion can be taken as the maximum depth of invasion in the two different specimens. Similar comments pertain if loop/cone excisions are received in more than one piece and where multifocal tumour can be excluded.
2. Many cervical carcinomas of large size or advanced stage are treated by chemoradiation, without surgical resection, once the diagnosis has been confirmed on a small biopsy specimen. In such cases, the tumour dimensions will be derived from clinical examination and the radiological appearances. As indicated previously, this dataset applies only to excision/resection specimens and not to small biopsy specimens.
3. Occasionally resections are undertaken following chemoradiation for cervical carcinoma. In such cases, there may be no residual tumour or only small microscopic foci making it impossible to assess the tumour dimensions. In such cases, the pre-treatment clinical or radiological tumour dimensions should be used for staging and the dimensions of the tumour in the resection should not be used for staging purposes.

Specific situations where tumour measurements are important

These include:-

1. Small carcinomas where accurate measurement is paramount in distinguishing between FIGO stage IA1, IA2 and small IB1 neoplasms.¹ As well as providing an accurate stage, this may also be critical in dictating patient management. For example, FIGO IA1 neoplasms are often treated by local excision ensuring that the margins are clear of pre-invasive and invasive disease while IA2 and IB1 neoplasms are usually treated by radical surgery (radical hysterectomy or trachelectomy).
2. In patients with FIGO stage IB tumours treated by radical hysterectomy, the tumour size is often one of the parameters used (in conjunction with tumour differentiation, presence or absence of lymphovascular invasion (LVI) and distance to margins) in assessing the need for adjuvant therapy.
3. The tumour measurements may be important in helping to determine whether radical hysterectomy or trachelectomy is performed; sometimes a cut-off size of 2 cm is used for performing a radical trachelectomy, although some surgeons would still perform this procedure for larger size lesions. Following radical trachelectomy, the recurrence rate is statistically higher with tumour size greater than 2 cm and rates of adjuvant treatment are higher.^{2,3} There is also a trend towards more conservative surgery (simple as

opposed to radical hysterectomy) in patients with tumours less than 2 cm as the probability of parametrial infiltration is very low.

4. Several studies have shown that in FIGO stage IB1 cervical carcinomas, a cut-off size of 2 cm may be of prognostic value.^{4,5} In the 2018 FIGO staging system, a cut-off of 2 cm distinguishes between IB1 and IB2 carcinomas. A cut-off of 4 cm is also of prognostic significance and in FIGO 2018 distinguishes between FIGO IB2 and IB3 neoplasms and between IIA1 and IIA2 neoplasms.^{1,6,7}

Measurement of horizontal extent of tumour (Figures 1 and 2)

The horizontal extent (two dimensions, i.e. both tumour length and width, measurements 'b' and 'c' in Figure 1) must be measured in all cases. As discussed earlier, in large tumours, this may best be done grossly if large block processing is not available, because in many cases these neoplasms will need to be submitted in multiple cassettes and the maximum tumour dimension may not be represented on a single slide. If a gross measurement is not performed in large circumferential tumours, there is a risk of overestimating the maximum horizontal extent of the tumour. This can occur when a circumferential tumour is "opened-up" and submitted in several sequential cassettes. When the other horizontal dimension (the third dimension) is calculated by adding up sequential slices in this situation (see below), this may result in an artificially greater measurement than is accurate.

In smaller neoplasms, the horizontal extent is best determined histologically (Figure 2). One dimension is the measurement in a single slide in which the extent of invasion is the greatest (measurement 'e', Figure 2). If the invasive focus is only represented in 1 block, then the other horizontal dimension is taken to be the thickness of the block (usually 2.5-3 mm, or estimated as indicated below). In some cases, the maximum horizontal extent may need to be calculated in the manner below if this is not represented in one section but is spread over several adjacent sections (measurement 'c', Figure 1). If invasive carcinoma is present in several adjacent sections of tissue and the invasive foci co-localise in the sections, the horizontal extent of the carcinoma should be calculated by an estimate of the thickness of the blocks, which is determined from the macroscopic dimensions of the specimen and the number of blocks taken. However, pathologists should be mindful that thickness of large or outsize blocks can vary from block to block, as compared with standard-sized blocks. Whilst it is acknowledged that measurements from calculating block thickness may be somewhat inaccurate, it will in some cases be the only way to determine the maximum horizontal extent and this may affect staging, especially in small tumours. A few points regarding measurement of the horizontal extent of tumours are listed below:-

1. in a case where a single tongue of stromal invasion is seen in continuity with the epithelium of origin (surface or glandular), the width of the single focus of invasion is measured across the invasive tongue.
2. where clustered foci of stromal invasion arise close together from a single crypt or from dysplastic surface epithelium as detached cell groups, the maximum horizontal extent must encompass all the foci of invasion in the immediate area and the horizontal extent should be measured from the edge at which invasion is first seen to the most distant edge at which invasion is detected.
3. where several foci of invasion arise in one single piece of cervical tissue as separate foci of invasion, but in close proximity (see section below on **MEASUREMENT OF MULTIFOCAL CARCINOMAS**), either as contiguous tongues of invasion or detached epithelial groups, the maximum horizontal extent is taken from the edge at which invasion is first seen to the most distant edge at which invasion is detected. The small amount of intervening tissue with no invasion (usually with in situ neoplasia) is included in the measurement.

Measurement of depth of invasion (Figure 2)

The maximum depth of invasion must be measured in all cases. This measurement is taken from the base of the epithelium (surface or crypt) from which the carcinoma arises to the deepest point of invasion, as specified in the FIGO classification.¹ If the deepest point of invasion involves the deep margin of the specimen, comment should be made regarding the possibility of underestimation of the depth of invasion; this is particularly applicable to loop/cone specimens. When the invasive focus

is in continuity with the dysplastic epithelium from which it originates, this measurement is straightforward. If the invasive focus or foci are not in continuity with the dysplastic epithelium, the depth of invasion should be measured from the tumour base (deepest focus of tumour invasion) to the base of the nearest dysplastic crypt or surface epithelium (Figure 2, measurements 'a' and 'c'). If there is no obvious epithelial origin despite multiple levels of the tissue block, the depth is measured from the tumour base (deepest focus of tumour invasion) to the base of the nearest surface epithelium, regardless of whether it is dysplastic or not (Figure 2, measurement 'd').

There are some situations where it is impossible to measure the depth of invasion. In such cases, the tumour thickness may be measured and this should be clearly stated on the pathology report along with the reasons for providing the thickness rather than the depth of invasion. In such cases, the pathologist and clinician should equate the tumour thickness with depth of invasion for staging and management purposes.

Situations where it may be necessary to measure the tumour thickness rather than the depth of invasion include:-

1. in some glandular lesions, it may be impossible to accurately assess where adenocarcinoma in situ (AIS) ends and where invasive adenocarcinoma begins. This is because, in general, identification of invasion in a glandular lesion is more difficult than in a squamous lesion and this is an area where a specialist opinion may be of value. In some cases where the thickness is measured (from the epithelial surface to the deepest point of the tumour) because the point of origin is impossible to establish, this may result in overestimation of the depth of invasion.
2. in ulcerated tumours with no obvious origin from overlying epithelium, the thickness may need to be measured. In this situation, measurement of tumour thickness may result in an underestimate of the depth of invasion.
3. uncommonly, squamous carcinomas, adenocarcinomas and other morphological subtypes are polypoid with an exclusive or predominant exophytic growth pattern. In such cases, the carcinoma may project above the surface with little or even no invasion of the underlying stroma. These should not be regarded as in-situ lesions and the tumour thickness will need to be measured in such cases (from the surface of the tumour to the deepest point of invasion). Depth of invasion i.e. the extent of infiltration below the level of the epithelial origin, should not be provided in these cases as it may not be a true reflection of the biological potential of such tumours.

Avoid the term microinvasive carcinoma

The term "microinvasive carcinoma" appears in the 2018 FIGO staging system for cervical cancer where it is equated with stage IA disease.¹ However, use of the term "microinvasive carcinoma" has different connotations in different geographical areas. For example, in the United Kingdom, microinvasive carcinoma was considered to be synonymous with FIGO stage IA1 and IA2 disease in most, but not all, institutions (some used the term "microinvasive carcinoma" to denote only FIGO stage IA1 tumours). In the United States and Canada where the Lower Anogenital Squamous Terminology (LAST)⁸ recommendations have been adopted, the term superficially invasive squamous cell carcinoma (SISCCA) is used to describe FIGO stage 1A1 tumours with negative margins, and the term "microinvasive squamous cell carcinoma" is no longer in routine use. Thus, in order to avoid confusion, it is recommended to avoid using the term "microinvasive carcinoma" for all morphological subtypes and to use the specific FIGO stage.

Measurement of multifocal carcinomas

Early invasive carcinomas of the cervix, especially squamous, are sometimes multifocal comprising tumours that show multiple foci of invasion arising from separate sites in the cervix and separated by uninvolved cervical tissue. Specifically, multifocal tumours should be diagnosed if foci of invasion are:

- separated by blocks of uninvolved cervical tissue (levels must be cut to confirm this)
- located on separate cervical lips with discontinuous tumour, not involving the curvature of the canal

- situated far apart from each other in the same section (see below).

The individual foci of stromal invasion may be attached to, or discontinuous from, the epithelium from which they arise. Multifocal carcinomas should not be confused with the scenario in which tongues or buds of invasion originate from more than one place in a single zone of transformed epithelium and will, over time, coalesce to form a single invasive tumour which represents unifocal disease (and should be measured as indicated above, in three dimensions).

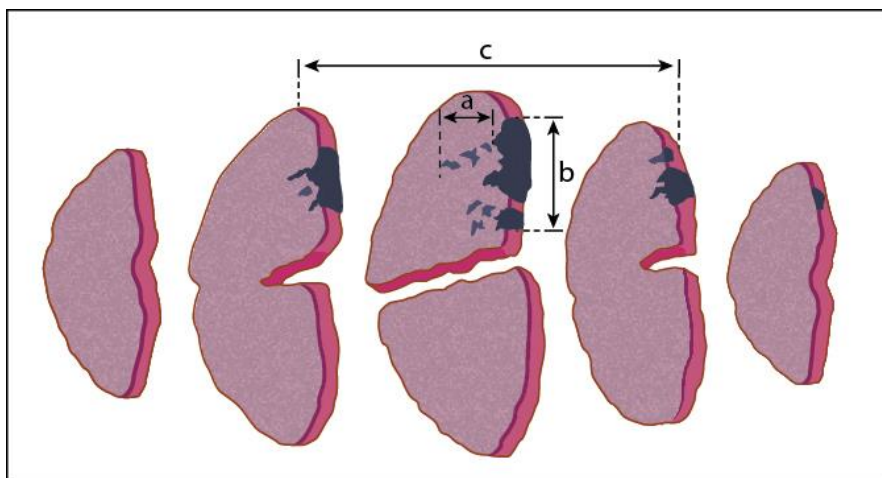
The frequency of multifocality in FIGO stage IA1 cervical squamous carcinomas has been reported to be between 12 and 25%⁹⁻¹¹ although multifocality in larger, advanced tumours is uncommon. There are few (and some rather dated) guidelines regarding measurement of multifocal carcinomas. Although pre-invasive disease may be present, when foci of stromal invasion arise from separate sites or are separated by cervical tissue without invasion (after levels/deeper sections have been cut to confirm this), the foci of invasion should be measured separately, in 3 dimensions, as described above, and staged according to the dimensions of the larger/largest tumour with a clear statement that the tumour is multifocal. However, in the last of the scenarios mentioned above (foci of stromal invasion situated far apart from each other in the same section) measurement of the multifocal disease is problematical. Options include measuring from the edge of one invasive focus to the edge of the furthest invasive focus according to FIGO guidelines (irrespective of the distance between foci of invasion), adding the maximum horizontal extent of each invasive focus together (which clearly does not reflect the biological potential of the individual invasive foci) or regarding widely separated foci as representing small independent areas of invasion.⁹⁻¹³ Two recent studies have regarded such lesions as representing multiple foci of invasion (multifocal FIGO IA1 carcinomas) if the foci of invasion are clearly separated. An arbitrary minimum distance of 2 mm between each separate focus of invasion has been applied in the 2 studies.^{9,10} Follow-up of patients in these two studies, which include a combined total of 46 cases of “multifocal IA1 cervical squamous carcinomas” treated by local excisional methods (loop/cone excision) with margins clear of premalignant and malignant disease, has shown no evidence of recurrent premalignant or malignant disease with median follow-up periods of 45 months and 7 years respectively.^{9,10} Moreover, one of the studies also showed that the prevalence of residual pre-invasive (20%) and invasive disease (5%) on repeat excision were comparable to data available for unifocal FIGO stage IA1 cases.¹⁰ These studies included cases which would have been regarded as FIGO stage IB1 in the 2009 staging system (but IA in the 2018 staging system) had the horizontal extent been measured from the edge of one invasive focus to the edge of the furthest invasive focus, as per FIGO guidelines. Although limited by a relatively small number of cases and the selection of an arbitrary distance of separation of 2 mm, the findings support the hypothesis that with regard to tumour staging and management, it may be appropriate to consider superficial, widely separated foci of invasion as representing multifocal lesions, to measure each focus separately, and to determine the FIGO stage on the basis of the invasive focus with the higher/highest FIGO stage. Although the International Collaboration on Cancer Reporting (ICCR) does not have a mandate to implement an approach based only on 2 studies involving 46 patients in total, the ICCR recommends that this approach be considered and discussed at the Tumour Board/MDTM meetings to avoid unnecessary surgery in young patients who wish to preserve their fertility in this specific clinical situation. This approach needs to be verified by additional larger collaborative studies and trials. It is also stressed that in such cases, the tissue blocks containing the invasive foci and those in between should be levelled to confirm that the invasive foci are truly separate and ensure that there is no occult stromal invasion in the intervening areas. If this approach is adopted, the pathology report should clearly indicate how the measurements have been obtained to arrive at a diagnosis of multifocal invasion, provide the dimensions of the separate foci of invasion and indicate how the FIGO stage has been ascertained. Such cases may need to be referred to cancer centres for review and, as indicated above, should be discussed individually at the Tumour Board/MDTM meeting. There have been no similar studies for multifocal adenocarcinomas but anecdotally these are less common than multifocal squamous carcinomas and until further evidence becomes available, a similar approach is recommended.

Measurement of tumour volume

In most studies, tumour size is based on measurement of two dimensions but in a few studies, tumour volume (based on the three measured tumour dimensions) has been shown to predict prognosis more reliably than measurements in only one or two dimensions. Some older studies have suggested tumour volume as a reliable prognostic factor for early stage tumours: a volume of less than 420 mm³ has been suggested to be associated with no lymph node metastasis.¹⁴⁻¹⁶ This is one of

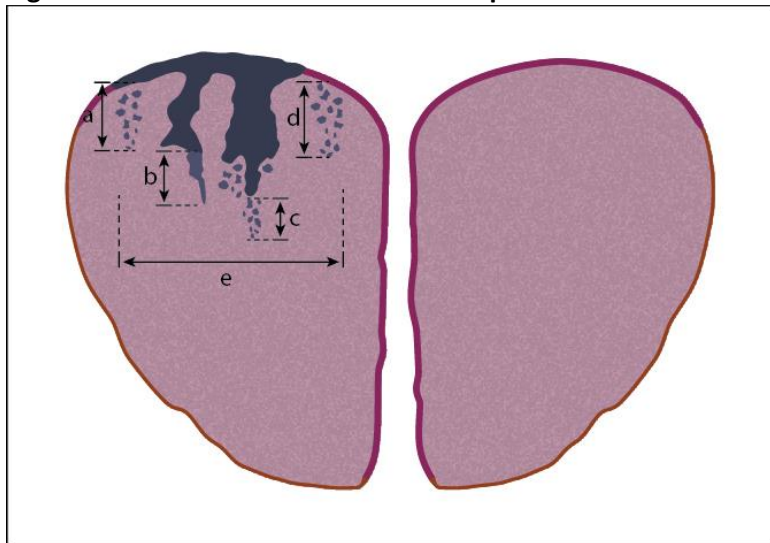
the main reasons for recommending that three tumour dimensions (two of horizontal extent and one of depth of invasion or tumour thickness) are provided. However, only a few centres continue to routinely factor tumour volume into patient management.

Figure 1: Measurement of cervical tumours in three dimensions



CIN3 with involvement of endocervical gland crypts is represented by the dark blue-coloured areas, non-dysplastic squamous epithelium is pink, and grey areas indicate foci of stromal invasion. The depth of invasion, (a), and horizontal tumour dimension/width, (b) are measured in unifocal disease. **Third dimension:** This dimension is determined by calculating the block thickness (usually 2.5 - 3.0 mm) from the macroscopic specimen dimensions and multiplying this by the number of sequential blocks through which the invasion extends.

Figure 2: Measurement of width and depth of invasion in cervical tumours



The dark blue-coloured areas represent CIN3 with involvement of endocervical gland crypts, non-dysplastic squamous epithelium is pink, and grey areas indicate foci of stromal invasion.

Depth of invasion: when invasion originates from the surface epithelium, (a), or gland crypts (b and c), the depth of invasion is taken from the base of the epithelium from which the invasive carcinoma arises, to the deepest focus of invasion, as specified in the FIGO classification. Measurements are taken in the same way, regardless of whether the invasive foci remain attached to the gland crypt (b) or not (c). Where invasion occurs and no obvious surface (or crypt) epithelial origin is seen, the depth of invasion is measured from the deepest focus of tumour invasion, to the base of the nearest non-neoplastic surface epithelium, (d).

Horizontal dimension/width in unifocal tumours, (e): this is measured in the slice of tissue in which the width is greatest (from the edge at which invasion is first seen, to the most distant edge at which invasion is identified), in sections where the foci of invasion arise in close proximity to each other, even if those foci are separated by short stretches of normal epithelium.

References

- 1 Bhatla N, Berek JS, Cuello Fredes M, Denny LA, Grenman S, Karunaratne K, Kehoe ST, Konishi I, Olawaiye AB, Prat J, Sankaranarayanan R, Brierley J, Mutch D, Querleu D, Cibula D, Quinn M, Botha H, Sigurd L, Rice L, Ryu HS, Ngan H, Maenpaa J, Andrijono A, Purwoto G, Maheshwari A, Bafna UD, Plante M and Natarajan J (2019). Revised FIGO staging for carcinoma of the cervix uteri. *Int J Gynaecol Obstet* 145(1):129-135.
- 2 Plante M, Gregoire J, Renaud MC and Roy M (2011). The vaginal radical trachelectomy: an update of a series of 125 cases and 106 pregnancies. *Gynecol Oncol* 121(2):290-297.
- 3 Park JY, Joo WD, Chang SJ, Kim DY, Kim JH, Kim YM, Kim YT and Nam JH (2014). Long-term outcomes after fertility-sparing laparoscopic radical trachelectomy in young women with early-stage cervical cancer: an Asan Gynecologic Cancer Group (AGCG) study. *J Surg Oncol* 110(3):252-257.
- 4 Turan T, Yildirim BA, Tulunay G, Boran N and Kose MF (2010). Prognostic effect of different cut-off values (20mm, 30mm and 40mm) for clinical tumor size in FIGO stage IB cervical cancer. *J Surg Oncol* 19(2):106-113.
- 5 Horn LC, Bilek K, Fischer U, Einkenkel J and Hentschel B (2014). A cut-off value of 2 cm in tumor size is of prognostic value in surgically treated FIGO stage IB cervical cancer. *Gynecol Oncol* 134(1):42-46.
- 6 Pecorelli S, Zigliani L and Odicino F (May 2009). Revised FIGO staging for carcinoma of the cervix. *Int J Gynaecol Obstet*. 105(2):107-108. Epub 2009 Apr 2001.
- 7 Horn LC, Fischer U, Raptis G, Bilek K and Hentschel B (2007). Tumor size is of prognostic value in surgically treated FIGO stage II cervical cancer. *Gynecol Oncol* 107(2):310-315.
- 8 Darragh TM, Colgan TJ, Cox JT, Heller DS, Henry MR, Luff RD, McCalmont T, Nayar R, Palefsky JM, Stoler MH, Wilkinson EJ, Zaino RJ, Wilbur DC and Members of LAST Project Work Groups (2012). The Lower Anogenital Squamous Terminology Standardization Project for HPV-Associated Lesions: background and consensus recommendations from the College of American Pathologists and the American Society for Colposcopy and Cervical Pathology. *Arch Pathol Lab Med* 136(10):1266-1297.
- 9 McIlwaine P, Nagar H and McCluggage WG (2014). Multifocal FIGO stage 1A1 cervical squamous carcinomas have an extremely good prognosis equivalent to unifocal lesions. *Int J Gynecol Pathol* 33(3):213-217.
- 10 Day E, Duffy S, Bryson G, Syed S, Shanbhag S, Burton K, Lindsay R, Siddiqui N and Millan D (2016). Multifocal FIGO Stage IA1 Squamous Carcinoma of the Cervix: Criteria for Identification, Staging, and its Good Clinical Outcome. *Int J Gynecol Pathol*.
- 11 Reich O, Pickel H, Tamussino K and Winter R (2001). Microinvasive carcinoma of the cervix: site of first focus of invasion. *Obstet Gynecol* 97(6):890-892.
- 12 Reich O and Pickel H (2002). Multifocal Stromal Invasion in Microinvasive Squamous Cell Carcinoma of the Cervix: How to Measure and Stage these Lesions. *Int J Gynecol Pathol* 21:416-417.
- 13 Hirschowitz L, Nucci M and Zaino RJ (2013). Problematic issues in the staging of endometrial, cervical and vulval carcinomas. *Histopathology* 62(1):176-202.
- 14 Burghardt E, Baltzer J, Tulusan AH and Haas J (1992). Results of surgical treatment of 1028 cervical cancers studied with volumetry. *Cancer* 70(3):648-655.
- 15 Trattner M, Graf AH, Lax S, Forstner R, Dandachi N, Haas J, Pickel H, Reich O, Staudach A and Winter R (2001). Prognostic factors in surgically treated stage ib-iiB cervical carcinomas with special emphasis on the importance of tumor volume. *Gynecol Oncol* 82(1):11-16.
- 16 Burghardt E and Holzer E (1977). Diagnosis and treatment of microinvasive carcinoma of the cervix uteri. *Obstet Gynecol* 49(6):641-653.