

# Invasive Melanoma Histopathology Reporting Guide



Family/Last name  Date of birth

Given name(s)

Patient identifiers  Date of request  Accession/Laboratory number

Elements in **black text** are CORE. Elements in **grey text** are NON-CORE.

indicates multi-select values  indicates single select values

[SCOPE OF THIS DATASET](#)

## TUMOUR SITE (Note 1)

- Not specified  
 Specify

## CLINICAL INTENT OF PROCEDURE (Note 2)

- Not specified  
 Excisional/complete diagnostic biopsy  
 Incisional/incomplete (partial) diagnostic biopsy  
 Wide excision

## SPECIMEN LATERALITY (Note 3)

- Not specified  
 Left  Midline  Right

## SPECIMEN(S) SUBMITTED (Note 4)

- Not specified  
 Punch technique  
 Shave technique (superficial)  
 Saucerization/scoop/deep shave technique  
 Curette  
 Fusiform/elliptical/disc (full-thickness)  
 Other, specify

## Lymph nodes

- Not submitted  
 Submitted, specify site(s)

## SPECIMEN ORIENTATION

(Per information received from the surgeon on orientation of specimen by marking sutures, clips or other techniques)

- Not specified  
 Specify, if known

## MACROSCOPIC PRIMARY LESION DESCRIPTION

(The description of the lesion includes such features as shape, colour, border, contour, evidence of surface crusting or ulceration and proximity to resection margins)

## MACROSCOPIC PRIMARY LESION DIMENSIONS

x  x

- Indeterminate (Note: Depth is optional)

## MACROSCOPIC SATELLITE LESIONS (Note 5)

(Applicable to invasive tumours only)

- Not identified  Indeterminate  
 Present

## OTHER LESION(S) (Note 6)

- Not identified  
 Present

### Macroscopic description of other lesion(s)

## SURGICAL MARGIN/TISSUE EDGES (Note 7)

- Cannot be assessed  
 Not involved by melanoma in situ or invasive melanoma

Distance of melanoma in situ or invasive tumour  ≤1 mm  >1 mm from closest margin

Specify closest location(s), if possible

- Involved by melanoma in situ

Specify location(s), if possible

- Involved by invasive melanoma

Specify location(s), if possible

## BRESLOW THICKNESS (Note 8)

(Measurement should be to the nearest 0.1 mm per AJCC staging)

- Specify    Indeterminate  
At least

## ULCERATION (Note 9)

- Not identified  Indeterminate  
 Present

**MITOTIC COUNT (Note 11)**

Indeterminate

**MICROSATELLITES (Note 12)**

- Not identified       Indeterminate  
 Present



**MICROSATELLITES: MARGINS (Note 13)**

- Cannot be assessed  
 Not involved by microsatellite  
 Involved by microsatellite

**CLARK LEVEL (Note 14)**

- Confined to epidermis (Level 1)  
 Infiltrates but does not fill papillary dermis-(Level 2)  
 Fills/expands papillary dermis (Level 3)  
 Infiltrates into reticular dermis (Level 4)  
 Infiltrates into subcutaneous fat (Level 5)

**LYMPHOVASCULAR INVASION (Note 15)**

- Not identified       Indeterminate  
 Present

**TUMOUR-INFILTRATING LYMPHOCYTES (Note 16)**

- Not identified  
 Brisk  
 Non brisk

**TUMOUR REGRESSION (Note 17)**

- Not identified       Indeterminate  
 Present



**TUMOUR REGRESSION: MARGINS (Note 18)**

- Cannot be assessed  
 Not involved by regression  
 Involved by regression

**NEUROTROPISM (Note 19)**

- Not identified       Indeterminate  
 Present

**DESMOPLASTIC MELANOMA COMPONENT (Note 20)**

- Not identified  
 Present  
     Pure (>90% desmoplastic melanoma)  
     Mixed desmoplastic/non-desmoplastic melanoma

**ASSOCIATED MELANOCYTIC LESION (Note 21)**

- Not identified  
 Present, describe

**LYMPH NODES STATUS (Note 22)**

*(Required only if lymph nodes submitted)*

**Sentinel nodes**

Number of sentinel nodes examined

Number of positive sentinel nodes

Number cannot be determined

- Extranodal extension\*  Not identified  
 Present  
 Indeterminate

Maximum dimension of largest metastasis in sentinel node\*

Location of largest sentinel node metastases\*

- Subcapsular  
 Intraparenchymal  
 Both subcapsular and intraparenchymal

**Non-sentinel lymph nodes (clinically occult)**

Number of non-sentinel nodes examined

Number of positive non-sentinel nodes

Number cannot be determined

- Extranodal extension\*  Not identified  
 Present  
 Indeterminate

Maximum dimension of largest metastasis in a non-sentinel node\*

**Clinically apparent lymph nodes**

Number of non-sentinel nodes examined

Number of positive non-sentinel nodes

Number cannot be determined

- Extranodal extension\*  Not identified  
 Present  
 Indeterminate

Maximum dimension of largest metastasis in a non-sentinel node\*

\* Required only in the presence of positive nodes.

**MELANOMA SUBTYPE** (select all that apply) (Note 23)  
 (Value list modified from the WHO Classification of Tumours. Pathology and Genetics of Skin Tumours.(2018))

- Low-CSD melanoma (superficial spreading melanoma)
- Lentigo maligna melanoma (high-CSD melanoma)
- Desmoplastic melanoma
- Malignant Spitz tumour (Spitz melanoma)
- Acral melanoma
- Mucosal melanomas (genital, oral, sinonasal)
- Melanoma arising in blue naevus
- Melanoma arising in giant congenital naevus
- Nodular melanoma
- Naevoid melanoma
- Melanoma, not otherwise classified
- Other, specify

**ANCILLARY STUDIES** (Note 24)

**BRAF testing**

- Not performed
- Performed

Record results and methodology

**Other testing, specify if performed**

Test	Result

**PATHOLOGICAL STAGING (UICC TNM 8th edition)\*\***

**TNM Descriptors** (only if applicable) (select all that apply)

- m - multiple primary tumours
- r - recurrent
- y - post-therapy
- sn - sentinel node biopsy

**Primary tumour (pT)** (Note 25)

- TX Primary tumour cannot be assessed\*
- T0 No evidence of primary tumour or regressed melanomas
- Tis Melanoma in situ (Clark level I)
- T1 Tumour 1 mm or less in thickness
  - T1a less than 0.8mm in thickness without ulceration
  - T1b less than 0.8mm in thickness with ulceration or 0.8mm or more but no more than 1mm in thickness, with or without ulceration
- T2 Tumour more than 1 mm but not more than 2 mm in thickness
  - T2a Without ulceration
  - T2b With ulceration
- T3 Tumour more than 2 mm but not more than 4 mm in thickness
  - T3a Without ulceration
  - T3b With ulceration
- T4 Tumour more than 4 mm in thickness
  - T4a Without ulceration
  - T4b With ulceration

**Regional lymph nodes (pN)** (Note 26)

- No nodes submitted or found
- NX Regional nodes not assessed
- N0 No regional lymph node metastases
- N1 Metastasis in one regional lymph node or intralymphatic regional metastasis without nodal metastases
  - N1a Only microscopic metastasis (clinically occult)
  - N1b Macroscopic metastasis (clinically apparent)
  - N1c Satellite or in-transit metastasis without regional nodal metastasis
- N2 Metastasis in two or three regional lymph nodes or intralymphatic regional metastasis with lymph node metastases
  - N2a Only microscopic nodal metastasis
  - N2b Macroscopic nodal metastasis
  - N2c Satellite or in-transit metastasis with only one regional nodal metastasis
- N3 Metastasis in four or more regional lymph nodes, or matted metastatic regional lymph nodes, or satellite(s) or in-transit metastasis with metastasis in two or more regional lymph node(s)
  - N3a Only microscopic nodal metastasis
  - N3b Macroscopic nodal metastasis
  - N3c Satellite or in-transit metastasis with two or more regional nodal metastasis

**Notes**

\* pTX includes shave biopsies and curettage that do not fully assess the thickness of the primary.

Satellites are tumour nests or nodules (macro or microscopic) within 2 cm of the primary tumour. In-transit metastasis involves skin or subcutaneous tissue more than 2 cm from the primary tumour but not beyond the regional lymph nodes.

\*\* Reproduced with permission. Source: Brierley JD, Gospodarowicz MK and Wittekind C (eds) (2016). UICC TNM Classification of Malignant Tumours, 8th Edition, Wiley-Blackwell.

## Scope

This dataset has been developed for reporting of primary cutaneous invasive melanoma.

The second edition of this dataset includes changes to align the dataset with the TNM Pathological staging 8th edition and the World Health Organization (WHO) Classification of Tumours. Pathology and Genetics of Skin Tumours. (2018). Other significant changes are the inclusion of Clinical Intent and Ancillary studies i.e. BRAF. Other minor changes have been made to bring the dataset into alignment with recent terminology and formatting updates.

[↑ Back](#)

### Note 1 - Tumour site (Core)

1. Sufficient information is required to localise the lesion for subsequent therapy. A diagram or photograph can facilitate this.<sup>1,2</sup>
2. It is important that the site of the biopsy be recorded as specifically/accurately as possible to reduce the risk of any required additional re-excision occurring at the incorrect site.
3. When matched for other known prognostic factors, melanomas on the scalp, other head and neck areas, upper back, axial skeleton and acral regions are reported to have a worse prognosis than extremity-based lesions.<sup>3-7</sup>
4. The anatomic site of the tumour may also affect the pathologic interpretation of the histologic features observed, and this may, in turn, influence the proffered pathologic diagnosis. For example, naevi occurring on certain sites (including the palms, sole, fingers and toes, flexural sites, genitalia, the breast and ear, sometimes referred to as “special sites”) often display features that could be considered evidence favouring melanoma in melanocytic tumours occurring at other sites.<sup>1,2,8,9</sup>

[↑ Back](#)

### Note 2 - Clinical intent of procedure (Core)

When interpreting a pigmented lesion, it is helpful for the pathologist to be advised by the clinician on whether the specimen was taken with the intent of its complete removal or as a partial sample (incomplete removal) of the lesion. This may not only influence the interpretation of the biopsy, but reporting of the surgical edges/margins of the specimen. While complete excision with narrow clearance margins is generally recommended when sampling clinically suspicious pigmented lesions, partial biopsy remains an acceptable practice in certain instances (see below).

An excisional (or complete) biopsy with narrow clearance margins (generally 1-3 mm) is usually the most appropriate method of biopsy of a clinically suspicious melanocytic tumour.<sup>10</sup> This enables an accurate assessment and will allow definitive treatment to be planned appropriately if a diagnosis of melanoma is confirmed. Diagnostic excisional biopsies with intent to remove the concerning neoplasm may involve an elliptical/fusiform, ovoid (or other shaped) full-thickness excision, punch, or deep shave/saucerization technique.

Incomplete diagnostic biopsies of melanocytic tumours (also termed “incisional” or “partial”) may also include specimens taken with elliptical/fusiform, punch, and shave techniques. Incomplete/partial/incisional biopsies may contribute to pathological misdiagnosis, because of unrepresentative sampling of a heterogenous tumour

(i.e., a partial biopsy may sample only the benign part of a lesion and miss a coexisting melanoma) or may not provide sufficient tissue for adequate assessment of the pathological criteria necessary to permit correct diagnosis.<sup>11-13</sup> Nevertheless, it remains an accepted clinical practice to partially sample melanocytic tumours in some instances, such as large pigmented lesions in surgically challenging locations—for example, the face or digits/acral sites. If two samples are from different parts of the same tumour, this should be explicitly noted.

Pathological diagnostic criteria for melanoma include features at the peripheral and deep aspects of the tumour, which may not be included in an incomplete biopsy. Another potential pitfall of an incomplete biopsy of a naevus is that it may regrow from residual naevocytes after incomplete removal. Regenerating (“recurrent” or “persistent”) naevi often display many histological features that commonly occur in melanomas (including pagetoid epidermal invasion, cytological atypia, occasional dermal mitoses and HMB45 positivity). For these reasons, such lesions have been termed ‘pseudomelanomas’ and are prone to overdiagnosis as melanomas.<sup>14-16</sup>

Incomplete biopsies of melanomas may also provide inaccurate assessment of important pathological features, such as Breslow thickness. Accurate assessment of pathological features of a primary melanoma allows prognosis to be reliably estimated; it also guides selection of appropriate management (width of excision margins, appropriateness of sentinel node biopsy); inaccurate pathological assessment can lead to inappropriate (and potentially insufficient) therapy.

↑ [Back](#)

### Note 3 - Specimen laterality (Core)

1. Specimen laterality information is needed for identification purposes and to localize the lesion for subsequent therapy. A diagram or photograph can facilitate this.<sup>1,2</sup>
2. It is important that the site of the biopsy be recorded as specifically/accurately as possible to reduce the risk of any required additional re-excision occurring at the incorrect site.

↑ [Back](#)

### Note 4 - Specimen(s) submitted (Core)

Although clinical considerations are important in determining the most appropriate biopsy technique for a melanocytic tumour, the type of biopsy performed may affect the accuracy of pathological evaluation<sup>12,17</sup> At times partial biopsies are performed of melanocytic lesions. Possible reasons include a very low suspicion of melanoma, the melanocytic lesion being large or located in a cosmetically sensitive area, and in some instances, no clinical suspicion of the lesion being melanocytic (e.g., melanocytic lesions that are amelanotic and exhibit no clinical pigment) (see also, **Note 1 Tumour site**).

Further, correlation of the type of procedure with the material received can be important for patient safety. For instance, if the clinician states that the procedure was a punch biopsy but the specimen examined is a skin ellipse, it is possible that there may be a misidentification of the specimen.

↑ [Back](#)

## Note 5 - Macroscopic satellite lesions (Core)

The presence of clinically/macroscopically apparent (or microscopically identified) metastases between the primary tumour and the regional lymph nodes is associated with adverse prognosis in melanoma and is classified as stage III melanoma in the 8<sup>th</sup> edition of the American Joint Commission on Cancer (AJCC) melanoma staging system.<sup>18-20</sup> Microsatellite, satellite and in-transit metastases, are thought to represent metastases that have occurred as a consequence of intralymphatic tumour spread. In the 8<sup>th</sup> edition AJCC melanoma staging system “(1) *satellite* metastases are defined as grossly visible cutaneous and/or subcutaneous metastases occurring within 2 cm of the primary melanoma); (2) *microsatellites* – microscopic cutaneous and/or subcutaneous metastases found adjacent or deep to a primary melanoma on pathological examination (see detailed discussion in Pathological Staging). The metastatic tumour cells must be discontinuous from the primary tumour (but not separated only by fibrosis or inflammation because this could signify regression of the intervening tumour); or (3) *in transit* metastases (defined as clinically evident dermal and/or subcutaneous metastases identified at a distance greater than 2 cm from the primary melanoma in the region between the primary and the first regional lymph nodes).”<sup>18</sup> There was no substantial difference in survival outcome for these anatomically defined entities in the 8<sup>th</sup> edition AJCC international melanoma database of contemporary patients and hence they were grouped together for staging purposes.<sup>20</sup>

↑ Back

## Note 6 - Other lesion(s) (Non-core)

Other lesions are often naevi or other benign lesions; however, it is particularly important to identify the presence of satellite metastases because these portend a worse prognosis.<sup>20</sup>

The description of the lesion includes such features as shape, colour, border, contour, evidence of surface crusting or ulceration and its proximity to the primary lesion and the resection margins.

↑ Back

## Note 7 - Surgical margin/Tissue edges (Core and Non-core)

When the clinical intention of the biopsy is to completely remove a melanoma, it is important to document when the surgical margins are microscopically involved (positive) by in situ or invasive melanoma and to specify the precise area of the positive margin, if possible. If the margins are microscopically clear, for clinical management purposes, it is usually sufficient to simply state this in the pathology report, unless the microscopic margin is narrow (where there is a risk that limited routine pathological sampling may fail to detect a positive margin). What constitutes a narrow microscopic margin in the excision specimen probably varies with the type of melanoma. For most cases of superficial spreading and nodular melanoma, a 1 mm peripheral rim of histologically uninvolved tissue is likely to be sufficient. However, with lentigo maligna and other melanomas with less well circumscribed and well-defined peripheral edges, a wider rim of histologically uninvolved tissue may be advisable.

When the deep margin is microscopically positive with invasive melanoma, it is often helpful to know whether the margin involvement represents focal transection or broad involvement by invasive tumour. This may be clinically useful, as an invasive melanoma with broad transection at the peripheral and deep margins in a partial biopsy of a larger lesion may influence future treatment planning. In contrast, focal transection at the deep margin is unlikely to result in a thicker melanoma in a wide excision specimen or to ultimately affect the AJCC stage defined by T category.

The standard treatment for primary melanoma is wide local excision of the skin and subcutaneous tissues around the melanoma. Such definitive treatment is not usually performed until after a pathological diagnosis of melanoma has been established. The aim is complete surgical excision of all in situ and invasive melanoma components. Involvement of the surgical margin may result in regrowth or metastasis from residual melanoma, and may adversely affect patient outcome.<sup>21-23</sup> On the basis of several randomized controlled trials (RCTs)<sup>24-28</sup> national guidelines from several countries have recommended wide excision margins according to the thickness of the primary cutaneous melanoma.<sup>29-31</sup> The trials were based on surgical margins measured clinically at the time of wide excision. Clinically measured wide excision margins are a less precise measure of the extent of excision of normal tissues surrounding the tumour than the histopathological margins. However, little prospective evidence is available that demonstrates a definite relationship between histopathological measured margin and local, in transit and regional recurrence. A number of recent retrospective studies have correlated histological and clinical margins with recurrence of melanoma.<sup>32-36</sup> These studies suggest that a histological margin of <8 mm in T1-T3 melanomas and <16 mm in T4 melanomas may be associated with adverse outcomes (such as locoregional recurrence and recurrence-free survival), but this requires validation in prospective studies.

Providing data on distance of melanoma from the margins may be helpful not only to clinicians in guiding patient management but also for pathologists when examining any subsequent specimen (e.g., re-excision specimen or for determining whether recurrent tumour at the primary site represents local persistence of melanoma or a metastasis).

↑ Back

## Note 8 - Breslow thickness (Core)

Breslow thickness/depth is the single most important prognostic factor for clinically localised primary melanoma.<sup>3</sup> Breslow thickness is measured from the top of the granular layer of the epidermis (or, if the surface is ulcerated, from the base of the ulcer) to the deepest invasive cell across the broad base of the tumour (dermal/subcutaneous) as described by Breslow.<sup>2,37,38</sup> Deep, vertical extensions of the tumour, perpendicular to the base should be assumed to be periadnexal and should not be included in the Breslow thickness. Similarly, satellite lesions or areas of vascular invasion should not be included. "Thickness should be measured by using an ocular micrometer calibrated to the magnification of the microscope used for the measurement. In accordance with consensus recommendations,<sup>39</sup> thickness measurements should be recorded to the nearest 0.1 mm, not the nearest 0.01 mm, because of impracticality and imprecision of measurement, particularly for tumours >1 mm thick. Tumours ≤1 mm thick may be measured to the nearest 0.01 mm if practical, but the measurement should be rounded up or down to be recorded as a single digit after the decimal (i.e., to the nearest 0.1 mm). The convention for rounding decimal values is to round down those ending in 1 to 4 and to round up for those ending in 5 to 9. For example, a melanoma measuring 0.75 mm in thickness would be recorded as 0.8 mm in thickness. Tumour measuring 0.95 mm and one measuring 1.04 mm both would be rounded to 1.0 mm (i.e., T1b)."<sup>18</sup>

To promote consistency in the evaluation of the Breslow thickness the following points are worthy of note:

1. The Breslow thickness can only be evaluated accurately in sections cut perpendicular to the epidermal surface. Otherwise, a note should be included indicating that "the section is cut tangentially and an accurate Breslow thickness cannot be provided." Nevertheless, in some tangentially cut sections, it is often still possible to report a tangentially measured tumour thickness. The latter may be clinically useful because it can be reasonably inferred that the true Breslow thickness must be less than this measurement, and, when appropriate, this should be stated clearly in the report. At other times, particularly when the epidermis is not visualized, no tumour thickness can be provided, and supplementary prognostic information must be obtained from other factors (including ulceration, mitotic rate, and Clark level). When sections have been tangentially cut, it may be fruitful to melt the

paraffin block and reembedded the tissue as it may then be possible to obtain perpendicular sections for determination of the Breslow thickness.

2. The Breslow thickness should be measured in the standard way when there is dermal regression (i.e., dermal regression extending to a greater thickness than the melanoma should not be included in the measurement of Breslow thickness).
3. In the case of periadnexal extension of melanoma (i.e., in the adventitial or extra-adventitial tissue immediately adjacent to skin appendageal structures usually apparent as an extension or “tongue” of tumour extending beyond the depth of the main tumour mass), it is uncertain from current evidence where the measurement of tumour thickness should be made to most accurately predict patient prognosis. (This does not include adnexal involvement by melanoma, which is regarded as in situ disease.) It is generally agreed that thickness measurements should not be based on periadnexal extension (either periadnexal adventitial or extra-adventitial extension), except when it is the only focus of invasion. In that circumstance, Breslow thickness may be measured from the centre of the hair follicle or sweat gland, to the furthest extent of infiltration into the periadnexal dermis. The depth of extension of such foci beneath the granular layer of the epidermis may also be measured and reported (but it should be clearly stated how the measurements were obtained and that the periadnexal measurement represents the estimated “true” Breslow thickness).
4. The Breslow thickness cannot be determined if a superficial biopsy transects a melanoma and includes only its superficial portion. In such instances, the pathologist can only report the melanoma to be ‘at least’ a certain thickness. Correlation with the re-excision specimen is necessary. As discussed in **Note 7**, it may be clinically useful to document whether the surgical transection by melanoma is focal or broad as this may assist the clinician in determining the appropriateness of sentinel node biopsy in T1 melanomas and the extent of wide excision in T2 melanomas.
5. Other problems may arise from differing interpretations of the nature of dermal cells (i.e., whether they represent melanoma or a pre-existing naevus) and of tumours with verruciform architecture.
6. The inclusion of neurotropic spread of melanoma in the measurement of Breslow thickness is controversial. In this instance, it is recommended that the thicknesses of the tumour including and excluding the neurotropic component be recorded in the pathology report.
7. Microsatellites, as discussed in detail below, are foci of tumour discontinuous from the primary melanoma (probably representing local metastases) and should not be included in the measurement of tumour thickness.
8. In some instances, particularly when a melanoma arises in association with a nevus, it may be difficult to distinguish small “nevoid” melanoma cells from nevus cells, and this may have implications for measuring tumour thickness. Careful assessment of architectural and especially cytologic features should assist in distinction, but at times this remains difficult, subjective, and prone to interobserver variability.

**The presence of any of the above attributes may warrant the inclusion of an explanatory note in the report to ensure that any uncertainty or nuance is clearly communicated.**

The standard method for measurement of tumour thickness in ulcerated lesions may lead to an underestimate of thickness, because the recommended measurement from the base of the ulcer to the base of the tumour makes no allowance for the amount of tumour lost through ulceration.

The thickness (measured from the top of the granular layer) of any zone of regression may also be recorded in the pathology report (but does not represent the Breslow thickness). If any measurement of regression is included in the report, it should not be included in the measurement of the Breslow thickness.

↑ **Back**

## Note 9 - Ulceration (Core)

Ulceration is an integral component of the AJCC/Union for International Cancer Control (UICC) staging system and an independent predictor of outcome in patients with clinically localised primary cutaneous melanoma.<sup>38,40,41</sup>

Assessing the presence of ulceration may be difficult in recently biopsied lesions and in cases in which there is only a focal loss of the epidermis; in this case, it is difficult to determine whether the epidermal deficiency is due to ulceration or to sectioning artifact. Absence of fibrin or granulation tissue from putative areas of ulceration would be clues that the apparent ulceration is actually due to sectioning of only part of the epidermis.<sup>42</sup>

↑ Back

## Note 10 - Extent of ulceration (Non-core)

Extent of ulceration measured microscopically as a diameter in mm (or as a percentage of the dermal invasive tumour width), provides more accurate prognostic information than the mere presence of ulceration.<sup>43-46</sup>

↑ Back

## Note 11 - Mitotic count (Core)

Multiple studies indicate that mitotic rate in the invasive portion is an important prognostic factor for localised primary melanomas (including very large studies utilizing the methodology for mitotic count determination described below).<sup>3,42,43,47-54</sup>

The number of mitotic figures can vary greatly between different parts of a tumour. For consistency and reproducibility, a standardised method must be used to assess mitotic count.<sup>55</sup> It is recommended that the field diameter of a microscope be formally calibrated using a stage micrometer to determine the number of high-power fields that equates to a 1 mm<sup>2</sup>.

In the 8<sup>th</sup> edition of the AJCC/UICC melanoma staging system, the recommended method to enumerate mitotic figures is to find an area in the dermis with obvious mitotic activity (the “hot spot”), and begin the count in this area, then extending the area counted to immediately adjacent non-overlapping high-power fields in a 1 mm<sup>2</sup> area. If no hot spot is identified and the mitotic figures are sparse and randomly scattered, then the count should begin in a field containing a mitosis, then extended to immediately adjacent non-overlapping high-power fields until a 1 mm<sup>2</sup> area of tissue containing melanoma is assessed. When the invasive component of the tumour involves an area <1 mm<sup>2</sup>, a 1 mm<sup>2</sup> area of dermal tissue that includes the tumour should be assessed and recorded as a number per mm<sup>2</sup>. The number of mitotic figures should be listed as a whole number/mm<sup>2</sup>. If no mitotic figures are identified, the mitotic count may be recorded “none identified” or “0/mm<sup>2</sup>”. This methodology for determining the mitotic count of a melanoma has been shown to have excellent interobserver reproducibility including amongst pathologists with widely differing experiences in the assessment of melanocytic tumours.<sup>42</sup>

It is also recommended in 8<sup>th</sup> edition of the AJCC/UICC staging manual that the mitotic count should be assessed in all primary melanomas (as whole number/mm<sup>2</sup>) for prognostic purposes.

The data that demonstrated the strong prognostic significance of mitotic count were obtained from the melanoma pathology reports of routinely assessed H&E stained sections. It is therefore not recommended that any additional sections be cut and examined (or immunochemical analysis be performed), in excess of those that would normally be used to report and diagnose the melanoma, to determine the mitotic count (i.e., no

additional sections should be cut and examined for the purpose of determining the mitotic count; this includes the situation when no mitotic figures are identified on the initial, routinely examined sections).

[↑ Back](#)

## Note 12 - Microsatellites (Core)

In the 8<sup>th</sup> edition of the AJCC melanoma staging system the definition of microsatellite was clarified and refined. A microscopic satellite is any nest of metastatic tumour cells discontinuous from the primary tumour (but not separated only by fibrosis or inflammation). There is no longer a minimum size threshold or distance from the primary tumour that defines a microsatellite. Fibrous scarring and/or inflammation between an apparently separate nodule and the primary tumour (rather than normal stroma) may represent regression of the intervening tumour; if these findings are present, the nodule is considered to be an extension of the primary tumour and not a microsatellite. The terms 'microsatellites', 'satellites' and 'in-transit metastases' probably represent biologically identical processes with identical (worse) prognostic implications.<sup>56-59</sup> Microsatellites, satellites and in-transit metastases are included in the same prognostic group by the AJCC and are classified as stage III melanoma in the 8<sup>th</sup> edition of the AJCC melanoma staging system.<sup>38,40,41,59</sup>

[↑ Back](#)

## Note 13 - Microsatellites: Margins (Core)

The presence of a melanoma satellite metastasis at a peripheral excision margin is usually an indication for re-excision, because it may serve as a source of recurrence and may imply that there might be further melanoma in the skin beyond the visible margins.

[↑ Back](#)

## Note 14 - Clark level (Non-core)

Clark-McGovern level may provide useful prognostic information if an accurate Breslow thickness cannot be determined e.g. where the specimen has been tangentially sectioned. Most evidence suggests that the Breslow thickness of a melanoma is a more accurate prognostic indicator than the Clark level.<sup>3</sup> In the 2017, 8<sup>th</sup> edition of the AJCC/UICC melanoma staging system, Clark level is not used as a primary criterion for the definition of T1b tumours (which are now defined by the presence of ulceration in a tumour <0.8 mm or 0.8-1.0 mm thickness with or without ulceration) except in the instance referred to above (e.g. occasionally mal-embedded lesions where no accurate measurement of thickness is possible).<sup>5,38,60</sup> It is also recommended that alphanumeric numbers be used to specify each of the Clark levels, rather than using the traditional Roman numerals to avoid confusion of Clark level with tumour stage.

[↑ Back](#)

## Note 15 - Lymphovascular invasion (Core)

Lymphovascular invasion refers to the presence of melanoma cells within the lumina of blood vessels (termed vascular invasion) or lymphatics (termed lymphatic invasion), or both. Lymphovascular invasion is identified by the demonstration of melanoma cells within the lumina of blood vessels or lymphatics, or both.

Lymphovascular invasion is recorded as present or absent. It is an uncommon finding in the excision specimens of primary cutaneous melanoma, but is generally regarded as a marker of poor prognosis.<sup>61,62 63,64</sup> There is a possible role for immunohistochemistry to highlight the presence of vascular invasion in selected cases.<sup>63,65</sup> At times it may be difficult to distinguish whether invasive tumour is present within a lymphatic channel or

represents a microsatellite. In this instance, the use of immunohistochemistry for a specific lymphatic marker such as D2-40 may assist in distinction. Invasion of tumour into the wall of a blood vessel but without tumour within the lumen of the blood vessel, should not be recorded as lymphovascular invasion.

↑ Back

## Note 16 - Tumour-infiltrating lymphocytes (Non-core)

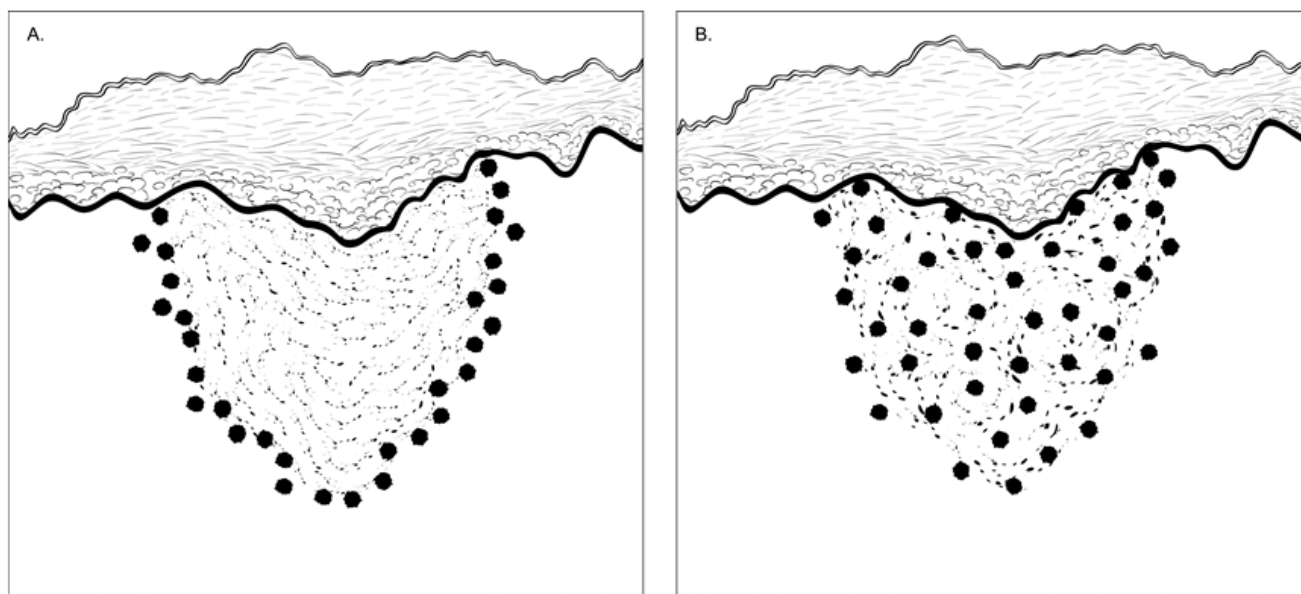
To be regarded as tumour-infiltrating lymphocytes (TILs), lymphocytes must infiltrate and disrupt tumour nests and/or directly oppose tumour cells. The degree of infiltration can be described by both the extent and the intensity of the TIL infiltrate.

The most commonly applied grading scheme for quantitating the presence of TILs is the system described by Clark, Mihm and Elder and is summarised below:

1. Absent TIL infiltrate: no lymphocytes present or, if present, they do not interact with tumour cells. For example, a cuff of lymphocytes around the periphery of the tumour with no infiltration is considered absent. Furthermore, lymphocytes within the tumour nodule but in perivenular array or in fibrous nodules in the tumour substance, without infiltration of the tumour itself, are considered absent.
2. Non-brisk TIL infiltrate: focal areas of lymphocytic infiltration in the tumour. They may be isolated, multifocal or segmental.
3. Brisk TIL infiltrate: TIL infiltration either of the entire base of the tumour or diffuse permeation of the tumour.

Other systems for grading TIL infiltrates based on the density and distribution of them have also been proposed, but these have not been independently validated.

Reports on the prognostic effect of TILs vary but most suggest the presence of 'brisk' or dense TILs is associated with a more favourable prognosis.<sup>43,66,67</sup> A recent report suggested a strong association between TIL infiltrates and sentinel node status and survival when utilizing a novel grading system.<sup>68</sup> Absent TILs predicted sentinel lymph node positivity in a number of recent studies.<sup>68,69</sup>



**Figure 1.** Brisk tumour-infiltrating lymphocytes. A. Lymphocytes diffusely infiltrate the entire base of the invasive tumour. B. Lymphocytes diffusely infiltrate the entire invasive component of the melanoma. Copyright College of American Pathologists.

↑ Back

## **Note 17 - Tumour regression (Non-core)**

A host immunologic response may be directed against melanoma and may result in elimination of part or all of the melanoma; this is termed regression. Regression may result in partial or complete loss of melanoma and is characterized by immature and mature dermal fibrosis, often accompanied by the presence of melanophages and effacement of the rete architecture, with absence of melanoma in the region of regression.

The prognostic significance of regression is controversial.<sup>2</sup> Some studies report that it portends a worse prognosis, whereas others report that it is associated with a more favourable outcome.<sup>2,70</sup> Difficulties in interpreting such studies include lack of a standardised definition or criteria for its diagnosis, selection bias, and poor interobserver reproducibility.

**↑ Back**

## **Note 18 - Tumour regression: margins (Non-core)**

Regression at a peripheral excision margin may be an indication for re-excision because it implies that there may be further melanoma in the skin beyond the visible margins.

**↑ Back**

## **Note 19 - Neurotropism (Core)**

Neurotropism is identified by the presence of melanoma cells around nerve sheaths (perineural invasion) or within nerves (intranural invasion).<sup>71-73,63,65,71,74</sup> It is recommended that pathologists be cautious not to overinterpret the presence of melanoma cells around nerves in the main tumour mass (which often represents “entrapment” of nerves in the expanding tumour) as neurotropism. Where possible neurotropism is identified in the main tumour mass, the presence of intraneural invasion or clear perineural invasion (PNI) (often recognised by the presence of “onion skinning”) can be useful to distinguish true neurotropism from entrapment. Some authorities also regard neural transformation (sometimes seen in desmoplastic melanoma) as a form of neurotropism.

Infiltration along nerve sheaths (or occasionally within the endoneurium) may be associated with an increased local recurrence rate (local persistence).<sup>75</sup> Neurotropism is common in desmoplastic melanoma (desmoplastic neurotropic melanoma), but may occur in other forms of melanoma.<sup>73,76-78</sup> One recent large study<sup>79</sup> reported that the presence of neurotropism was not associated with increased risk of local recurrence compared with other non-neurotropic melanomas if adequate surgical margins were obtained. However, adjuvant radiotherapy reduced the risk of recurrence if adequate surgical margins could not be achieved. It may be helpful for the clinician if the pathologist reports whether the PNI is “extensive” or “focal” (i.e., involving only a single or multiple nerves) and/or size of involved nerves, but evidence for this is lacking.

**↑ Back**

## Note 20 - Desmoplastic melanoma component (Core)

Desmoplastic melanoma (DM) is a rare subtype of melanoma characterized by malignant spindle cells separated by prominent fibrocollagenous or fibromyxoid stroma. Primary melanomas may be entirely or almost entirely desmoplastic ("pure" DM) or exhibit a desmoplastic component admixed with a non-desmoplastic component ("mixed" DM).<sup>80</sup> Spindle (or epithelioid) melanoma cells not separated by desmoplastic stroma are not regarded as desmoplastic melanoma but may form the non-desmoplastic component of a mixed desmoplastic/non-desmoplastic melanoma. In 2004, Busam *et al* reported a clinicopathologic study of DM patients in which subdividing the tumours into "pure" and "mixed" subtypes correlated with clinical outcome.<sup>81</sup> In that study, the authors classified melanomas as "pure" DM if "the overwhelming majority ( $\geq 90\%$ ) of invasive tumour was desmoplastic", or "mixed" DM if "typical features of DM were mixed with densely cellular tumour foci without fibrosis and desmoplasia" and the DM areas involved  $< 90\%$  and  $> 10\%$  of the invasive melanoma. Similar findings have since been reported by others.<sup>71-73,75,81-90</sup> Improved disease-specific survival is seen in patients with "pure" DM, when compared with patients with "mixed" DM and those with melanomas lacking a desmoplastic component.<sup>71-73,75,81-90</sup> Furthermore, regional nodal metastasis (including that detected by sentinel lymph node biopsy) is less common in patients presenting with clinically localized pure DM compared with those who had mixed DM or conventional melanomas.<sup>71-73,75,81-90</sup>

↑ Back

## Note 21 - Associated melanocytic lesion (Non-core)

Although of no known prognostic value, the recognition of an associated benign melanocytic lesion is relevant to the pathogenesis of melanoma, and may be important for clinicopathological correlation and epidemiological, clinical and genetic studies.<sup>91</sup> Documentation of associated benign melanocytic tumour is also of relevance where there may be residual melanocytic tumour in the re-excision specimen, and when knowledge of this may assist in the interpretation of the residual tumour overlying a scar as pseudomelanoma/recurrent naevus, rather than melanoma.

In some instances, it can be difficult or even impossible to determine whether part of the dermal component of a melanocytic tumour represents melanoma or an associated naevus. This is particularly the situation in melanoma composed of small, minimally atypical 'naevoid' cells, or in cases in which the dermal component of a melanoma 'matures' with depth.<sup>92</sup> Careful assessment of cytological characteristics — including the presence of mitotic figures and the identification of a second discrete cell population — may assist in some cases.

↑ Back

## Note 22 - Lymph node status (Core and Non-core)

If lymph nodes are NOT received, this element should not be reported.

The presence or absence of nodal metastasis is an important N category criterion in the AJCC staging system.

Regional lymph nodes are the most common site of initial metastasis in patients with cutaneous melanoma. Among patients with regional lymph node metastasis, the majority have clinically occult disease that is detected by the technique of lymphatic mapping and sentinel lymph node biopsy. Patients without clinical or radiographic evidence of regional lymph node metastases but who have microscopically documented nodal metastases (usually detected by lymphatic mapping and sentinel node biopsy) are defined as "clinically occult" whereas nodal metastases detected by palpation or radiological imaging are defined as "clinically apparent".<sup>18</sup> Patients with "clinically occult" metastases are designated (as in the prior edition) as N1a, N2a, or N3a based

on the number of tumour-involved nodes unless microsattellites, satellites, or in-transit metastases are present.<sup>18</sup> Patients who present with clinical evidence of regional disease are assigned as N1b, N2b, or N3b based on the number of nodes involved. If at least one node was clinically evident, and there are additional involved nodes detected only on microscopic examination, the total number of involved nodes (e.g., both those clinically apparent and those detected only on microscopic examination of a complete lymphadenectomy specimen) should be recorded for N categorization.<sup>18</sup> If a node is “clinically apparent” it is not, strictly speaking, a sentinel node.

If a lymph node is received but it is not specifically stated that it is a sentinel node then it should be reported as a non-sentinel node. Any additional relevant microscopic comments should be recorded.

Extranodal extension (ENE) is an adverse prognostic factor in melanoma patients. It is defined as the presence of a nodal metastasis extending through the lymph node capsule and into adjacent tissue, which may be apparent macroscopically but must be confirmed microscopically. Matted nodes (defined as two or more nodes adherent to one another through involvement by metastatic disease, identified at the time the specimen is examined macroscopically in the pathology laboratory) often suggest the presence of ENE but the latter must be confirmed microscopically.<sup>20</sup>

### **Sentinel Lymph Nodes**

Tumour-harboring status of the sentinel lymph nodes (SLN) is the strongest predictor of outcome for clinically localized primary cutaneous melanoma patients.<sup>68,93-96</sup>

There are a number of potential pitfalls in the microscopic examination of SLNs.<sup>97</sup> The most common diagnostic problem is distinguishing nodal nevus cells from a melanoma metastasis. This can usually be resolved by careful assessment of the location, morphologic features, and immunohistochemical staining characteristics of the cells and, in some instances, comparing the cytology of the nodal melanocytes with the cells of the primary invasive melanoma. Nodal nevi are usually located in the fibrous capsule and trabeculae of lymph nodes (but may rarely occur within the nodal parenchyma) and consist of small cytologically bland cells that are devoid of mitotic activity and, on immunohistochemistry, show strong diffuse positivity for S-100 and Melan-A, minimal staining for HMB-45, and a low (<2%) Ki-67 proliferative index. In contrast, melanoma deposits in SLNs are typically located in the subcapsular sinus or parenchyma and often comprise large, cytologically atypical cells with variably prominent nucleoli, mitotic activity, HMB-45 positivity, and Ki-67 positivity (variable but usually >2%).<sup>98,99</sup> Other cells that may be found within lymph nodes and that are positive for S-100 include interdigitating (antigen presenting dendritic) cells, nerves, and, occasionally, macrophages. These can usually be distinguished from melanoma cells on the basis of their location, size, shape, nuclear and cytoplasmic characteristics, distribution within the node, and immunohistochemical profile.<sup>100</sup> Positive Melan-A/MART-1 staining of small numbers of cells in the intraparenchymal portion of lymph nodes from patients without a history of melanoma has been reported, and in our view caution should be exercised to not overinterpret isolated Melan-A/MART-1-positive (or HMB-45-positive) cells in SLNs as melanoma in the absence of other corroborative evidence (such as cytologic atypia, mitotic activity, or immunohistochemical positivity for HMB-45 and an increased high Ki-67/MIB-1 index).<sup>101</sup> In our experience, the occurrence of such cells has become a more frequent diagnostic problem in recent years, presumably reflecting the utilization of more sensitive antibodies and immunohistochemical techniques.<sup>102,103</sup> These cells could represent nevus cells, macrophages passively carrying melanoma-associated antigens, or some other cell type carrying antigens that cross-react with Melan-A/MART-1. Similarly, weak positive staining for HMB-45 is sometimes observed in pigment-laden macrophages and nevus cells. For a node to be interpreted as positive for melanoma, the immuno-positive cells in question should be morphologically consistent with being melanoma cells.

Histologic parameters of melanoma deposits in SLNs have been shown to be predictive of the presence or absence of tumour in non-SLNs and clinical outcome.<sup>104-118</sup> If there are only a small number of metastatic melanoma cells in the subcapsular sinus of the SLN, the patient’s prognosis is very good and the chance of finding additional metastases in a completion lymph node dissection specimen is very small. However, if there

are multiple large deposits of melanoma cells that extend deeply into the central part of an SLN, the prognosis is much worse, and the chance of finding additional metastases in non-SLNs in a completion lymph node dissection specimen is much higher. SLN parameters predictive of non-SLN status and survival include the size of metastases, tumour penetrative depth (also known as maximal subcapsular depth and centripetal thickness and defined as the maximum distance of melanoma cells from the nearest inner margin of the lymph node capsule), the location of tumour deposits in the SLN, the percentage cross-sectional area of the SLN that is involved, and the presence of extracapsular spread. However, the power of individual features of melanoma metastases in SLNs to predict tumour in non-SLNs, as well as survival, reported in some studies has not been reported by others. The determination of some of these parameters may not always be reliable, because tumour deposits are often irregularly shaped, the limits of tumour deposits can be difficult to discern, and tumour burden is to some degree dependent on sectioning protocols, as more extensive sectioning may reveal additional tumour deposits or demonstrate a greater dimension of deposit(s) in the deeper sections.<sup>119</sup>

It is recommended that guidelines provided for the measurement of the maximum dimension of the largest sentinel node metastasis in the AJCC Melanoma Staging System be used. The single largest maximum dimension (measured in millimetres to the nearest 0.1 mm using an ocular micrometre) of the largest discrete metastatic melanoma deposit in sentinel nodes should be measured and recorded. To be considered a discrete deposit, the tumour cells must be in direct continuity with adjacent tumour cells. In some instances, multiple small tumour aggregates may be disbursed within a lymph node and separated by lymphoid cells. In this circumstance, the size of the largest discrete single deposit (not the nodal area over which the multiple deposits are contained) should be recorded. The measurement may be made either on H&E-stained sections or on sections stained immunohistochemically.<sup>1120</sup>

↑ [Back](#)

## **Note 23 - Melanoma subtype (Non-core)**

The common subtypes listed (superficial spreading melanoma, nodular melanoma, and lentigo maligna melanoma), have little prognostic significance independent of tumour thickness,<sup>2,121-124</sup> and their use is principally for clinicopathological correlation. Nevertheless, the traditional (“Clark-McGovern”) melanoma histogenetic classification highlights the myriad clinical and histological guises of melanoma, which if not recognized by clinicians and pathologists will inevitably lead to a delay in diagnosis and a concomitant adverse clinical outcome.<sup>125</sup> The traditional classification has been criticised because the criteria upon which it is based include clinical features (such as the site of the melanoma) and non-tumourous histopathological features (such as the character of the associated epidermis and the degree of solar elastosis) and also because of overlap in defining features. Nevertheless, there are instances where the melanoma subtype may influence prognosis and clinical management. For example, desmoplastic melanoma is less frequently associated with sentinel node positivity and some patients with desmoplastic melanoma may be managed with post operative radiotherapy. Similarly, melanoma in situ of lentigo maligna subtype in some patients may be better managed with staged surgical or alternative therapy considerations.

Based upon epidemiological and molecular evidence Bastian proposed a multidimensional classification for melanoma based on the role of ultraviolet radiation, the cell of origin and characteristic recurrent genetic alterations.<sup>126</sup> Building upon this proposal, in the latest addition of the World Health Organization(WHO) Classification of Skin Tumours, nine pathways for melanoma development are described.<sup>127</sup> Melanomas occurring predominantly in sun exposed skin include 1. Low cumulative sun damage (CSD) melanoma/superficial spreading melanoma, 2. High CSD melanoma/lentigo maligna melanoma and 3. Desmoplastic melanoma. Melanomas arising in sun shielded sites or without a known etiological association with UV exposure include 1. Malignant Spitz tumour (Spitz melanoma), 2. Acral melanoma, 3. Mucosal melanoma, 4. Melanoma arising in congenital naevus, 5. Melanoma arising in blue naevus and 6. Uveal melanoma. The commonest driver mutations identified in melanomas have included BRAF (40%), NRAS (15-20%), KIT (2%), and GNAQ/GNA11 (50% of uveal melanomas and almost universal melanomas in blue nevi, but

rare overall). BRAF mutations are most frequently identified in melanomas occurring in skin with a low degree of CSD whereas NRAS, NF1 and nonV600E BRAF mutations predominate in melanomas occurring in skin with a high degree of CSD. TERT promoter mutations and CDKN2A copy number loss and/or mutations are also implicated relatively early in the melanoma pathogenesis.

↑ [Back](#)

## Note 24 - Ancillary studies (Non-core)

### BRAF testing

Based on recent advances in our understanding of the molecular basis of melanoma and the role of the immune system in controlling the disease have led to multiple new therapeutic strategies that have radically transformed the care of melanoma patients, particularly those with advanced stage disease. These treatments were initially shown to be effective in patients with stage IV melanoma but more recently have demonstrated a 50% reduction in the rate of relapse for patients with stage III melanoma and are now being trialed in patients with earlier stage melanoma. Examples of these new effective drug therapies approaches are immunotherapy, using immune system checkpoint inhibitors against CTLA-4<sup>128,129</sup> and/or PD-1,<sup>130-132</sup> and molecularly-targeted therapy using BRAF inhibitors alone (monotherapy)<sup>133-137</sup> or in combination with MEK inhibitors<sup>138-142</sup> for the approximately 40-50% of patients with metastatic melanoma whose melanoma harbors a BRAF V600 mutation.<sup>143,144</sup>

BRAF mutations in melanoma are predominantly V600E (73-90%) and V600K (5-20%), but occasionally are other genotypes. There is an inverse relationship between BRAF mutation prevalence and age. Almost all patients <30 years and only 25% of patients ≥70 years had BRAF-mutant melanoma. Amongst BRAF-mutant melanoma, the frequency of non-V600E genotypes (including V600K) increase with increasing age. There are various molecular techniques for detecting BRAF and other somatic gene mutations within melanoma and these techniques are associated with varying sensitivity and specificity. With all techniques, careful macrodissection by pathologists to enrich for tumour cells is usually an important pre-analytical step to ensure optimal results of testing. The presence of BRAFV600E mutation can be detected by immunohistochemistry, but there are as yet no validated antibodies available for the detection of BRAFV600K mutations, and hence alternative techniques are required.

### Other ancillary testing

In selected circumstances, molecular ancillary studies can be helpful when evaluating melanocytic tumours. In difficult melanocytic tumours, in which accurate characterization of the tumour as benign or malignant is difficult based on routine histopathology, it may be useful to assess for the presence of chromosomal copy number aberrations.

Comparative genomic hybridization (CGH) and fluorescence in situ hybridization (FISH) can be used to detect chromosomal copy number aberrations in formalin-fixed, paraffin-embedded tissue.<sup>145,146</sup> FISH can be utilized to directly visualize specific chromosomal copy number changes within individual tumour cells. While it has the limitation of being able to test for only a limited number of changes (compared to CGH, which tests for chromosomal aberrations in the entire genome), FISH is more easily applied in routine clinical practice and can be successfully performed on small tumour samples. CGH is generally only available in specialist centres, and is expensive and not applicable to small samples.

Gene expression has also been used to assist in the classification of borderline melanocytic tumours and a number of commercially available tests have been developed utilising this technique. However, these tests need further validation before they can be recommended for routine (i.e. beyond adjunct) use in the clinical setting.<sup>147,148</sup>

With recent rapid advances in molecular techniques, it is likely that massively parallel next generation sequencing will become widely available in coming years.<sup>149</sup> This will provide an opportunity to perform more

comprehensive molecular evaluation of a tumour from data generated in a single assay including mutation analysis, copy number changes, structural rearrangements and mutation burden. Although challenges remain in performing detailed analysis in a timely fashion within the constraints of a diagnostic setting, this will provide an unprecedented opportunity to incorporate molecular data into routine pathological evaluation and provide new insights into diagnosis, and prognostic and predictive biomarkers as well as tumour classification.

While some studies have shown correlation between mutation burden, gene signatures and/or PDL1 expression and response to immunotherapies, at present there are no biomarkers with sufficiently high sensitivity or specificity to be of clinical utility in routine practice.

↑ Back

## Note 25 - Pathological staging (TNM 8th ed.) - Primary tumour (T) (Core)

In the 8th edition of the AJCC/UICC melanoma staging system,<sup>18</sup> tumour thickness and ulceration continue to define T1, T2, T3 and T4 categories.

If a partial biopsy of a melanoma has been performed, the maximum tumour thickness from the thicker of either the biopsy or definitive excision and presence of (nontraumatic) ulceration in either specimen should be recorded for pathological T categorization purposes.<sup>18</sup>

The reference document: TNM Supplement: A commentary on uniform use, 4th Edition (C Wittekind editor) may be of assistance when staging.<sup>150</sup>

↑ Back

## Note 26 - Pathological staging (TNM 8th ed.) - Regional lymph nodes (N) (Core)

“Thickness should be measured by using an ocular micrometer calibrated to the magnification of the microscope used for the measurement. In accordance with consensus recommendations,<sup>39</sup> thickness measurements should be recorded to the nearest 0.1 mm, not the nearest 0.01 mm, because of impracticality and imprecision of measurement, particularly for tumours >1 mm thick. Tumours ≤1 mm thick may be measured to the nearest 0.01 mm if practical, but the measurement should be rounded up or down to be recorded as a single digit after the decimal (i.e., to the nearest 0.1 mm). The convention for rounding decimal values is to round down those ending in 1 to 4 and to round up for those ending in 5 to 9. For example, a melanoma measuring 0.75 mm in thickness would be recorded as 0.8 mm in thickness. Tumour measuring 0.95 mm and one measuring 1.04 mm both would be rounded to 1.0 mm (i.e., T1b).”<sup>18</sup>

“Patients without clinical or radiographic evidence of regional lymph node metastases but who have microscopically documented nodal metastases (usually detected by lymphatic mapping and SLN biopsy) are defined as having “clinically occult” (previously termed *microscopic* in the 7th Edition) disease, and represent the vast majority of patients who are diagnosed with regional metastasis at presentation.<sup>151,152</sup> Patients with clinically occult metastases are designated as N1a, N2a, or N3a based on the number of tumour-involved nodes, unless microsattellites, satellites, or in-transit metastases are present. If they are, the patient is assigned N1c, N2c, or N3c according to the number of involved nodes. Patients who may undergo systemic treatment after needle biopsy of a clinically detected node or an SLN biopsy only are clinically staged as cN1 or greater. There is growing evidence that microscopic tumour burden in the sentinel node is prognostically significant.<sup>107-110,113,114,117,118,153-157</sup> Though this histopathologic characteristic was not proposed for the N category in the 8th Edition, it was recommended to be recorded; documentation of sentinel node burden is an important factor that will be included in and likely guide future prognostic models and the development of clinical tools for

patients with regional disease. Sentinel node tumour burden is discussed in detail in Additional Factors Recommended for Clinical Care.”<sup>18</sup>

“In melanoma, there is no unequivocal evidence that there is a lower threshold of microscopically identifiable sentinel node tumour burden that should be used to define node-positive disease for staging purposes. A sentinel lymph node in which any metastatic tumour cells are identified, irrespective of how few the cells are or whether they are identified on hematoxylin and eosin (H&E) or immunostained sections, should be designated as a tumour-positive lymph node. This is unchanged from the 7th Edition. If melanoma cells are found within a lymphatic channel within or immediately adjacent to a lymph node, that node is regarded as tumour- involved for staging purposes.”<sup>18</sup>

To determine the number of nodes involved for pathological staging, the number of tumour-positive sentinel nodes should be added to the number of tumour-positive nonsentinel nodes, if any, identified after completion lymph node dissection (if performed). Not all patients with a positive SLN biopsy undergo completion lymph node dissection (CLND). If a patient undergoes SLN biopsy that is positive for metastasis, and does not undergo CLND, the designation of pN1 (sn) is appropriate and may be used. In the context of patients who undergo completion lymphadenectomy after SLN biopsy, the pN1a, pN1b, or pN1c subcategory (without the suffix “(sn)”) implying that a CLND has been performed and the (sn) description is not used.<sup>18</sup>

“Patients who present with clinical evidence of regional disease are assigned as N1b, N2b, or N3b based on the number of nodes involved. If at least one node was clinically evident and there are additional involved nodes detected only on microscopic examination, the total number of involved nodes (e.g., both those clinically apparent and those detected only on microscopic examination of a complete lymphadenectomy specimen) should be recorded for N categorization. As noted for patients with clinically occult disease, those with clinically evident disease who also have microsatellites, satellites, or in-transit metastases at diagnosis are assigned as N1c, N2c, or N3c, based on the number of nodes involved by metastasis.”<sup>18</sup>

“Patients with clinically occult regional disease have been shown to have better survival than patients with clinically evident disease.”<sup>40,158,159</sup> Overall, there is marked heterogeneity in prognosis among patients with Stage III regional node disease by N-category designation or by T category among patients with N+ disease. Although N category alone predicts outcome, more accurate prognostic estimation is obtained by also incorporating features of the primary tumour.”<sup>18</sup>

M category criteria continue to be determined both by site of distant metastases and serum lactate dehydrogenase (LDH), but patients with regionally isolated metastasis from an unknown primary site should be categorised as Stage III rather than Stage IV, because their prognosis corresponds to that of Stage III disease from a known primary site.

**↑ Back**

## References

- 1 Scolyer RA, Thompson JF and Stretch JR (2004). Pathology of melanocytic lesions: new, controversial, and clinically important issues. *Journal of Surgical Oncology* 86(4):200–211.
- 2 Scolyer RA, Mihm Jr MC, Cochran AJ, Busam KJ and McCarthy SW (2009). Pathology of melanoma. In: *Cutaneous Melanoma*, Balch CM, Houghton Jr A, Sober A and Soong SJ (eds), Quality Medical Publishing, St. Louis, Missouri, 205–248.
- 3 Azzola MF, Shaw HM, Thompson JF, Soong S-J, Scolyer RA, Watson GF, Colman MH and Zhang Y (2003). Tumor mitotic rate is a more powerful prognostic indicator than ulceration in patients with primary cutaneous melanoma. Analysis of 3661 patients from a single center. *Cancer* 97(6):1488–1498.
- 4 Balch CM, Murad TM and Soong SJ (1978). A multifactorial analysis of melanoma: prognostic histopathological features comparing Clark's and Breslow's staging methods. *Annals of Surgery* 188(6):732–742.
- 5 Balch CM, Soong SJ, Gershenwald JE, Thompson JF, Reintgen DS, Cascinelli N, Urist M, McMasters KM, Ross MI, Kirkwood JM, Atkins MB, Thompson JA, Coit DG, Byrd D, Desmond R, Zhang Y, Liu PY, Lyman GH and Morabito A (2001). Prognostic factors analysis of 17,600 melanoma patients: validation of the American Joint Committee on Cancer melanoma staging system. *Journal of Clinical Oncology* 19(16):3622–3634.
- 6 Ozao-Choy J, Nelson DW, Hiles J, Stern S, Yoon JL, Sim MS and Faries MB (2017). The prognostic importance of scalp location in primary head and neck melanoma. *J Surg Oncol* 116(3):337-343.
- 7 Chakera AH, Quinn MJ, Lo S, Drummond M, Haydu LE, Bond JS, Stretch JR, Saw RPM, Lee KJ, McCarthy WH, Scolyer RA and Thompson JF (2018). Subungual Melanoma of the Hand. *Ann Surg Oncol*.
- 8 Scolyer RA, Crotty KA, Palmer AA and McCarthy SW (2002). Pagetoid spread of melanocytes in Spitz naevi: authors' reply *Pathology* 34(6):591.
- 9 Tan K-B, Murali R, Thompson JF, Arnold CJ, McCarthy SW and Scolyer RA (2007). Current perspectives on the pathologic diagnosis and reporting of melanocytic tumors. *Italian Journal of Dermatology and Venereology* 142(2):83–97.
- 10 Thompson JF, Scolyer RA and Kefford RF (2005). Cutaneous melanoma. *Lancet* 365(9460):687–701.
- 11 Scolyer RA, McCarthy SW and Elder DE (2004). Frontiers in melanocytic pathology. *Pathology* 36(5):385–386.

- 12 Scolyer RA, Thompson JF, McCarthy SW, Strutton GM and Elder DE (2006). Incomplete biopsy of melanocytic lesions can impair the accuracy of pathological diagnosis. *Australasian Journal of Dermatology* 47(1):71–73.
- 13 Armour K, Mann S and Lee S (2005). Dysplastic naevi: to shave, or not to shave? A retrospective study of the use of the shave biopsy technique in the initial management of dysplastic naevi. *Australasian Journal of Dermatology* 46(2):70–75.
- 14 Dymock RB and Menz J (1986). Recurrent melanocytic naevi following partial removal (pseudomelanoma). *Australasian Journal of Dermatology* 27(2):67–69.
- 15 Kornberg R and Ackerman AB (1975). Pseudomelanoma: recurrent melanocytic nevus following partial surgical removal. *Archives of Dermatology* 111(12):1588–1590.
- 16 Suster S (1986). Pseudomelanoma. A pathologist's perspective. *International Journal of Dermatology* 25(8):506–507.
- 17 Scolyer RA and Prieto VG (2011). Melanoma pathology: important issues for clinicians involved in the multidisciplinary care of melanoma patients. *Surg Oncol Clin N Am* 20(1):19–37.
- 18 Amin MB, Edge SB and Greene FL et al (eds) (2017). *AJCC Cancer Staging Manual. 8th ed.*, Springer, New York.
- 19 Read RL, Haydu L, Saw RP, Quinn MJ, Shannon K, Spillane AJ, Stretch JR, Scolyer RA and Thompson JF (2015). In-transit melanoma metastases: incidence, prognosis, and the role of lymphadenectomy. *Ann Surg Oncol* 22(2):475–481.
- 20 Gershenwald JE, Scolyer RA, Hess KR, Sondak VK, Long GV, Ross MI, Lazar AJ, Faries MB, Kirkwood JM, McArthur GA, Haydu LE, Eggermont AMM, Flaherty KT, Balch CM and Thompson JF (2017). Melanoma staging: Evidence-based changes in the American Joint Committee on Cancer eighth edition cancer staging manual. *CA Cancer J Clin* 67(6):472–492.
- 21 Pasquali S, Haydu LE and Scolyer RA et al (2013). The importance of adequate primary tumor excision margins and sentinel node biopsy in achieving optimal locoregional control for patients with thick primary melanomas. *Ann Surg.* 258:152–157.
- 22 Sladden MJ, Balch C and Barzilai DA et al (2009). Surgical excision margins for primary cutaneous melanoma. *Cochrane Database Syst Rev.*:CD004835.
- 23 Heenan PJ (2004). Local recurrence of melanoma. *Pathology* 36(5):491–495.
- 24 Veronesi U and Cascinelli N (1992). Narrow Excision (1-cm Margin) - A Safe Procedure For Thin Cutaneous Melanoma. *Archives of Surgery* 126:438–441.

- 25 Cohn-Cedermark G, Rutqvist LE and Andersson R et al (2000.). Long term results of a randomized study by the Swedish Melanoma Study Group on 2-cm versus 5-cm resection margins for patients with cutaneous melanoma with a tumor thickness of 0.8-2.0 mm. *Cancer* 89:1495-1501.
- 26 Balch CM, Soong S and Smith T et al (2001). Long-term results of a prospective surgical trial comparing 2 cm vs. 4 cm excision margins for 740 patients with 1-4 mm melanomas. *Annals of Surgical Oncology* 8:101-108.
- 27 Khayat D, Rixe O and Martin G et al (2003). Surgical margins in cutaneous melanoma (2 cm versus 5 cm for lesions measuring less than 2.1-mm thick) - Long-term results of a large European multicentric phase III study. *Cancer* 97:1941-1946.
- 28 Thomas JM, Newton-Bishop J and A'Hern R et al (2004). Excision margins in high-risk malignant melanoma. *New England Journal of Medicine* 350:757-766.
- 29 Garbe C, Peris K and Hauschild A et al (2010). Diagnosis and treatment of melanoma: European consensus-based interdisciplinary guideline. *Eur J Cancer* 46:270-283.
- 30 Marsden JR, Newton-Bishop JA, Burrows L et al and (2010). Revised U.K. guidelines for the management of cutaneous melanoma. *Br J Dermatol* 163:238-256.
- 31 Coit DG, Andtbacka R and Bichakjian CK et al (2009). Melanoma. *Journal of the National Comprehensive Cancer Network* 7:250-275.
- 32 Friedman EB, Dodds TJ, Lo S, Ferguson PM, Beck M, Saw RPM, Stretch JR, Lee KK, Nieweg OE, Spillane AJ, Scolyer RA and Thompson JF (2019). Correlation Between Surgical and Histologic Margins in Melanoma Wide Excision Specimens. *Ann Surg Oncol* 26(1):25-32.
- 33 MacKenzie Ross AD, Haydu LE, Quinn MJ, Saw RP, Shannon KF, Spillane AJ, Stretch JR, Scolyer RA and Thompson JF (2016). The Association Between Excision Margins and Local Recurrence in 11,290 Thin (T1) Primary Cutaneous Melanomas: A Case-Control Study. *Ann Surg Oncol* 23(4):1082-1089.
- 34 Haydu LE, Stollman JT, Scolyer RA, Spillane AJ, Quinn MJ, Saw RP, Shannon KF, Stretch JR, Bonenkamp JJ and Thompson JF (2016). Minimum Safe Pathologic Excision Margins for Primary Cutaneous Melanomas (1-2 mm in Thickness): Analysis of 2131 Patients Treated at a Single Center. *Ann Surg Oncol* 23(4):1071-1081.
- 35 Lamboo LG, Haydu LE, Scolyer RA, Quinn MJ, Saw RP, Shannon KF, Spillane AJ, Stretch JR, Bonenkamp JJ and Thompson JF (2014). The optimum excision margin and regional node management for primary cutaneous T3 melanomas (2-4 mm in Thickness): a retrospective study of 1587 patients treated at a single center. *Ann Surg* 260(6):1095-1102.

- 36 Harish V, Bond JS, Scolyer RA, Haydu LE, Saw RP, Quinn MJ, Bengner RS, Uren RF, Stretch JR, Shannon KF and Thompson JF (2013). Margins of excision and prognostic factors for cutaneous eyelid melanomas. *J Plast Reconstr Aesthet Surg* 66(8):1066-1073.
- 37 Breslow A (1970). Thickness, cross-sectional areas and depth of invasion in the prognosis of cutaneous melanoma. *Annals of Surgery* 172(5):902–908.
- 38 Edge SE, Byrd DR, Compton CC, Fritz AG, Greene FL and Trotti A (eds) (2010). *AJCC Cancer Staging Manual 7th ed.*, New York, NY.: Springer.
- 39 Scolyer RA, Judge MJ, Evans A, Frishberg DP, Prieto VG, Thompson JF, Trotter MJ, Walsh MY, Walsh NMG and Ellis DW (2013). Data Set for Pathology Reporting of Cutaneous Invasive Melanoma: Recommendations From the International Collaboration on Cancer Reporting (ICCR). *Am J Surg Pathol.* 37:1797-1814.
- 40 Balch CM, Buzaid AC, Soong SJ, Atkins MB, Cascinelli N, Coit DG, Fleming ID, Gershenwald JE, Houghton A, Jr., Kirkwood JM, McMasters KM, Mihm MF, Morton DL, Reintgen DS, Ross MI, Sober A, Thompson JA and Thompson JF (2001). Final version of the American Joint Committee on Cancer staging system for cutaneous melanoma. *Journal of Clinical Oncology* 19(16):3635–3648.
- 41 AJCC (American Joint Committee on Cancer) (2002). *AJCC Cancer Staging Manual, 6th edition.* Springer-Verlag, New York.
- 42 Scolyer RA, Shaw HM, Thompson JF, Li LX, Colman MH, Lo S, McCarthy SW, Palmer AA, Nicoll KD, Dutta B, Slobedman E, Watson GF and Stretch JR (2003). Interobserver reproducibility of histopathologic prognostic variables in primary cutaneous melanomas. *American Journal of Surgical Pathology* 27(12):1571–1576.
- 43 Clark W, Jr, Elder D, Guerry D, Braitman L, Trock B, Schultz D, Jynnestvedt M and Halpern A (1989). Model predicting survival in stage I melanoma based on tumor progression. *Journal of the National Cancer Institute* 81(24):1893–1904.
- 44 Grande Sarpa H, Reinke K, Shaikh L, Leong SP, Miller JRr, Sagebiel RW and Kashani-Sabet M (2006). Prognostic significance of extent of ulceration in primary cutaneous melanoma. *American Journal of Surgical Pathology* 30(11):1396–1400.
- 45 Balch CM, Wilkerson JA, Murad TM, Soong S, Ingalls AL and Maddox WA (1980). The prognostic significance of ulceration of cutaneous melanoma. *Cancer* 45(12):3012–3017.
- 46 in't Hout FEM, Haydu LE, Murali R, Bonenkamp JJ, Thompson JF and Scolyer RA (2012). Prognostic importance of the extent of ulceration in clinically localized cutaneous melanoma. *Ann Surg* 255(6):1165-1170.
- 47 Barnhill RL, Katzen J, Spatz A, Fine J and Berwick M (2005). The importance of mitotic rate as a prognostic factor for localized cutaneous melanoma. *J Cutan Pathol* 32(4):268–273.

- 48 Gimotty P, Elder D, Fraker D, Botbyl J, Sellers K, Elenitsas R, Ming ME, Schuchter L, Spitz FR, Czerniecki BJ and Guerry D (2007). Identification of high-risk patients among those diagnosed with thin cutaneous melanomas. *Journal of Clinical Oncology* 25(9):1129–1134.
- 49 Ostmeier H, Fuchs B, Otto F, Mawick R, Lippold A, Krieg V and Suter L (1999). Can immunohistochemical markers and mitotic rate improve prognostic precision in patients with primary melanoma? *Cancer* 85(11):2391–2399.
- 50 Retsas S, Henry K, Mohammed MQ and MacRae K (2002). Prognostic factors of cutaneous melanoma and a new staging system proposed by the American Joint Committee on Cancer (AJCC): validation in a cohort of 1284 patients. *European Journal of Cancer* 38(4):511–516.
- 51 Gimotty P, Van Belle P, Elder DE, Murry T, Montone KT, Xu X, Hotz S, Raines S, Ming ME, Wahl P and Guerry D (2005). Biologic and prognostic significance of dermal Ki67 expression, mitoses, and tumorigenicity in thin invasive cutaneous melanoma. *Journal of Clinical Oncology* 23(31):8048–8056.
- 52 Nagore E, Oliver V, Botella-Estrada R, Morena-Picot S, Insa A and Fortea J (2005). Prognostic factors in localized invasive cutaneous melanoma: high value of mitotic rate, vascular invasion and microscopic satellitosis. *Melanoma Res* 15(3):169–177.
- 53 Francken AB, Shaw HM, Thompson JF, Soong SJ, Accortt NA, Azzola MF, Scolyer RA, Milton GW, McCarthy WH, Colman MH and McGovern VJ (2004). The prognostic importance of tumor mitotic rate confirmed in 1317 patients with primary cutaneous melanoma and long follow-up. *Annals of Surgical Oncology* 11(4):426–433.
- 54 Thompson JF, Soong SJ, Balch CM, Gershenwald JE, Ding S, Coit DG, Flaherty KT, Gimotty PA, Johnson T, Johnson MM, Leong SP, Ross MI, Byrd DR, Cascinelli N, Cochran AJ, Eggermont AM, McMasters KM, Mihm MC Jr, Morton DL and Sondak VK (2011 Jun 1). Prognostic significance of mitotic rate in localized primary cutaneous melanoma: an analysis of patients in the multi-institutional American Joint Committee on Cancer melanoma staging database. *J Clin Oncol.* 29(16):2199-2205.
- 55 Scolyer RA and Thompson JF (2013). Mitotic rate in melanoma should be recorded as the number of mitoses per mm<sup>2</sup> (not per high power field): surgeons tell your pathologists! . *Am J Surg Pathol* 206(1):142-143.
- 56 Harrist TJ, Rigel DS, Day CLJ, Sober AJ, Lew RA, Rhodes AR, Harris MN, Kopf AW, Friedman RJ, Golomb FM, Cosimi AB, Gorstein F, Malt RA, Wood WC, Postel A, Hennessey P, Gumport SL, Roses DF, Mintzis MM, Raker JW, Fitzpatrick TB and Mihm Jr MC (1984). 'Microscopic satellites' are more highly associated with regional lymph node metastases than is primary melanoma thickness. *Cancer* 53(10):2183–2187.
- 57 León P, Daly JM, Synnestvedt M, Schultz DJ, Elder DE and Clark Jr WH (1991). The prognostic implications of microscopic satellites in patients with clinical stage I melanoma. *Archives of Surgery* 126(12):1461–1468.

- 58 Day Jr CL, Harrist TJ, Gorstein F, Sober AJ, Lew RA, Friedman RJ, Pasternack BS, Kopf AW, Fitzpatrick TB and Mihm Jr MC (2001). Malignant melanoma. Prognostic significance of "microscopic satellites" in the reticular dermis and subcutaneous fat. *Annals of Surgery* 194(1):108–112.
- 59 Shaikh L, Sagebiel RW, Ferreira CM, Nosrati M, Miller 3rd JR and Kashani-Sabet M (2005). The role of microsattellites as a prognostic factor in primary malignant melanoma. *Archives of Dermatology* 141:739–742.
- 60 Kelly J, Sagebiel R, Clyman S and Blois M (1985). Thin level IV malignant melanoma — a subset in which level is the major prognostic indicator. *Annals of Surgery* 202(1):98–103.
- 61 Schmoeckel C, Bockelbrink A, Bockelbrink H, Koutsis J and Braun-Falco O (1983). Low- and high-risk malignant melanoma. I. Evaluation of clinical and histological prognosticators in 585 cases. *European Journal of Cancer and Clinical Oncology* 19(2):227–235.
- 62 Kashani-Sabet M, Sagebiel RW, Ferreira CM, Nosrati M and Miller 3rd JR (2001). Vascular involvement in the prognosis of primary cutaneous melanoma. *Archives of Dermatology* 137(9):1169–1173.
- 63 Yun SJ, Gimotty PA and Hwang WT et al (2011). High lymphatic vessel density and lymphatic invasion underlie the adverse prognostic effect of radial growth phase regression in melanoma. *Am J Surg Pathol Case Rev* 35:235-242.
- 64 Xu X, Chen L and Guerry D et al (2012). Lymphatic invasion is independently prognostic of metastasis in primary cutaneous melanoma. *Clin Cancer Res* 18:229-237.
- 65 Petersson F, Diwan AH and Ivan D et al (2009). Immunohistochemical detection of lymphovascular invasion with D2-40 in melanoma correlates with sentinel lymph node status, metastasis and survival. *J Cutan Pathol.* 36:1157-1163.
- 66 Clemente CG, Mihm MC, Jr, Bufalino R, Zurrida S, Collini P and Cascinelli N (1996). Prognostic value of tumor infiltrating lymphocytes in the vertical growth phase of primary cutaneous melanoma. *Cancer* 77(7):1303–1310.
- 67 Mihm Jr MC, Clemente CG and Cascinelli N (1996). Tumor infiltrating lymphocytes in lymph node melanoma metastases: a histopathologic prognostic indicator and an expression of local immune response. *Laboratory Investigation* 74(1):43–47.
- 68 Azimi F, Scolyer RA, Rumcheva P, Moncrieff M, Murali R, McCarthy SW, Saw RP and Thompson JF (2012). Tumor-infiltrating lymphocyte grade (TIL grade) is an independent predictor of sentinel lymph node status and survival in cutaneous melanoma patients. *J Clin Oncol* 30:2678-2683.
- 69 Taylor RC, Patel A, Panageas KS, Busam KJ and Brady MS (2007). Tumor-infiltrating lymphocytes predict sentinel lymph node positivity in patients with cutaneous melanoma. *Journal of Clinical Oncology* 25(7):869–875.

- 70 Aung PP, Nagarajan P and Prieto VG (2017). Regression in primary cutaneous melanoma: etiopathogenesis and clinical significance. *Lab Invest*.
- 71 Smithers BM, McLeod GR and Little JH (1990). Desmoplastic, neural transforming and neurotropic melanoma: a review of 45 cases. *Australian and New Zealand Journal of Surgery* 60(12):967–972.
- 72 Carlson JA, Dickersin GR, Sober AJ and Barnhill R (1995). Desmoplastic neurotropic melanoma. A clinicopathologic analysis of 28 cases. *Cancer* 75(2):478–494.
- 73 McCarthy SW, Crotty KA and Scolyer RA (2006). Desmoplastic melanoma and desmoplastic neurotropic melanoma. In: *World Health Organization Classification of Tumors. Pathology and Genetics of Skin Tumours*, LeBoit PE, Burg G, Weedon D and Sarasin A (eds), IARC Press, Lyon, France, 76–78.
- 74 Pasquali S, van der Ploeg AP and Mocellin S et al (2013). Lymphatic biomarkers in primary melanomas as predictors of regional lymph node metastasis and patient outcomes. *Pigment Cell Melanoma Res*. 26:326-337.
- 75 Baer SC, Schultz D, Synnestvedt M and Elder DE (1995). Desmoplasia and neurotropism. Prognostic variables in patients with stage I melanoma. *Cancer* 76(11):2242–2247.
- 76 Murali R, Shaw HM and Lai K et al (2010). Prognostic factors in cutaneous desmoplastic melanoma: a study of 252 patients. *Cancer* 116:4130-4138.
- 77 Sassen S, Shaw HM and Colman MH et al (2008). The complex relationships between sentinel node positivity, patient age, and primary tumor desmoplasia: analysis of 2303 melanoma patients treated at a single center. *Ann Surg Oncol*. 15:630-637.
- 78 Chen JY, Hruby G and Scolyer RA et al (2008). Desmoplastic neurotropic melanoma: a clinicopathologic analysis of 128 cases. *Cancer* 113:2770-2778.
- 79 Varey AHR, Goumas C, Hong AM, Mann GJ, Fogarty GB, Stretch JR, Saw RPM, Spillane AJ, Shannon KF, Lee KJ, Quinn MJ, Thompson JF and Scolyer RA (2017). Neurotropic melanoma: an analysis of the clinicopathological features, management strategies and survival outcomes for 671 patients treated at a tertiary referral center. *Mod Pathol* 30(11):1538-1550.
- 80 Scolyer RA and Thompson JF (2005). Desmoplastic melanoma: a heterogeneous entity in which subclassification as “pure” or “mixed” may have important prognostic significance. *Ann Surg Oncol*. 12:197-199.
- 81 Busam K, Mujumdar U, Hummer A, Nobrega J, Hawkins W, Coit D and Brady M (2004). Cutaneous desmoplastic melanoma: reappraisal of morphologic heterogeneity and prognostic factors. *American Journal of Surgical Pathology* 28(11):1518–1525.

- 82 Quinn MJ, Crotty KA, Thompson JF, Coates AS, O'Brien CJ and McCarthy WH (1998). Desmoplastic and desmoplastic neurotropic melanoma: experience with 280 patients. *Cancer* 83(6):1128–1135.
- 83 Jain S and Allen PW (1989). Desmoplastic malignant melanoma and its variants. A study of 45 cases. *American Journal of Surgical Pathology* 13(5):358–373.
- 84 Hawkins WG, Busam KJ, Ben-Porat L, Panageas KS, Coit DG, Gyorki DE, Linehan DC and Brady MS (2005). Desmoplastic melanoma: a pathologically and clinically distinct form of cutaneous melanoma. *Annals of Surgical Oncology* 12(3):207–213.
- 85 Gyorki DE, Busam K, Panageas K, Brady MS and Coit DG (2003). Sentinel lymph node biopsy for patients with cutaneous desmoplastic melanoma. *Annals of Surgical Oncology* 10(4):403–407.
- 86 Pawlik TM, Ross MI, Prieto VG, Ballo MT, Johnson MM, Mansfield PF, Lee JE, Cormier JN and Gershenwald JE (2006). Assessment of the role of sentinel lymph node biopsy for primary cutaneous desmoplastic melanoma. *Cancer* 106(4):900–906.
- 87 Arora A, Lowe L, Su L, Rees R, Bradford C, Cimmino VC, Chang AE, Johnson TM and Sabel MS (2005). Wide excision without radiation for desmoplastic melanoma. *Cancer* 104(7):1462–1467.
- 88 Shaw HM, Quinn MJ, Scolyer RA and Thompson JF (2006). Survival in patients with desmoplastic melanoma. *Journal of Clinical Oncology* 24(8):E12–E13.
- 89 Busam KJ (2005). Cutaneous desmoplastic melanoma. *Advances in Anatomic Pathology* 12(2):92–102.
- 90 McCarthy S, Scolyer R and Palmer A (2004). Desmoplastic melanoma: a diagnostic trap for the unwary. *Pathology* 36(5):445–451.
- 91 Curtin JA, Fridlyand J, Kageshita T, Patel HN, Busam KJ, Kutzner H, Cho KH, Aiba S, Brocker EB, LeBoit PE, Pinkel D and Bastian BC (2005). Distinct sets of genetic alterations in melanoma. *New England Journal of Medicine* 353(20):2135–2147.
- 92 McCarthy SW and Scolyer RA (2010). Pitfalls and important issues in the pathologic diagnosis of melanocytic tumors. *Ochsner J* 10:66-74.
- 93 Chakera AH, Hesse B and Burak Z et al (2009). EANM-EORTC general recommendations for sentinel node diagnostics in melanoma. *Eur J Nucl Med Mol Imaging*. 36:1713-1742.
- 94 Scolyer RA, Murali R and McCarthy SW et al (2008). Pathologic examination of sentinel lymph nodes from melanoma patients. *Semin Diagn Pathol*. 25:100-111.
- 95 Scolyer RA, Murali R and Satzger I et al (2008). The detection and significance of melanoma micrometastases in sentinel nodes. *Surg Oncol*. 17:165-174.

- 96 Gershenwald JE, Thompson W, Mansfield PF, Lee JE, Colome MI, Tseng CH, Lee JJ, Balch CM, Reintgen DS and Ross MI (1999). Multi-institutional melanoma lymphatic mapping experience: the prognostic value of sentinel lymph node status in 612 stage I or II melanoma patients. *J Clin Oncol* 17(3):976-983.
- 97 Starz H (2004). Pathology of the sentinel lymph node in melanoma. *Semin Oncol*. 31:357-362.
- 98 Carson KF, Wen DR and Li PX et al (1996). Nodal nevi and cutaneous melanomas. *Am J Surg Pathol*. 20:834-840.
- 99 Messina JL, Glass LF and Cruse CW et al (1999). Pathologic examination of the sentinel lymph node in malignant melanoma. *Am J Surg Pathol* 23:686-690.
- 100 Li LX, Scolyer RA and Ka VS et al (2003). Pathologic review of negative sentinel lymph nodes in melanoma patients with regional recurrence: a clinicopathologic study of 1152 patients undergoing sentinel lymph node biopsy. *Am J Surg Pathol*. 27:1197-1202.
- 101 Biddle DA, Evans HL, Kemp BL, El-Naggar AK, Harvell JD, White WL, Iskandar SS and Prieto VG (2003). Intraparenchymal nevus cell aggregates in lymph nodes: a possible diagnostic pitfall with malignant melanoma and carcinoma. *Am J Surg Pathol* 27(5):673-681.
- 102 Itakura E, Huang RR and Wen DR et al (2011). "Stealth" melanoma cells in histology-negative sentinel lymph nodes. *Am J Surg Pathol*. 35:1657-1665.
- 103 Yan S and Brennick JB (2004). False-positive rate of the immunoperoxidase stains for MART1/MelanA in lymph nodes. *Am J Surg Pathol*. 28:596-600.
- 104 Kunte C, Geimer T and Baumert J et al (2011). Analysis of predictive factors for the outcome of complete lymph node dissection in melanoma patients with metastatic sentinel lymph nodes. *J Am Acad Dermatol*. 64:655-662 quiz 637.
- 105 Murali R, Desilva C and Thompson JF et al (2011). Factors predicting recurrence and survival in sentinel lymph node-positive melanoma patients. *Ann Surg*. 253:1155-1164.
- 106 Ariyan C, Brady MS and Gonen M et al (2009). Positive nonsentinel node status predicts mortality in patients with cutaneous melanoma. *Ann Surg Oncol*. 16:186-190.
- 107 van Akkooi AC, Nowecki ZI and Voit C et al (2008). Sentinel node tumor burden according to the Rotterdam criteria is the most important prognostic factor for survival in melanoma patients: a multicenter study in 388 patients with positive sentinel nodes. *Ann Surg*. 248:949-955.
- 108 Francischetto T, Spector N and Neto Rezende JF et al (2010). Influence of sentinel lymph node tumor burden on survival in melanoma. *Ann Surg Oncol*. 17:1152-1158.

- 109 Cochran AJ, Wen DR and Huang RR et al (2004). Prediction of metastatic melanoma in nonsentinel nodes and clinical outcome based on the primary melanoma and the sentinel node. *Mod Pathol*. 17:747-755.
- 110 Dewar DJ, Newell B and Green MA et al (2004). The microanatomic location of metastatic melanoma in sentinel lymph nodes predicts nonsentinel lymph node involvement. *J Clin Oncol*. 22:3345-3349.
- 111 Wiener M, Acland KM and Shaw HM et al (2010). Sentinel node positive melanoma patients: prediction and prognostic significance of nonsentinel node metastases and development of a survival tree model. *Ann Surg Oncol*. 17:1995-2005.
- 112 Younan R, Bougrine A and Watters K ea (2010). Validation study of the s classification for melanoma patients with positive sentinel nodes: the Montreal experience. *Ann Surg Oncol*. 17:1414-1421.
- 113 Starz H, Balda BR and Kramer KU et al (2001). A micromorphometrybased concept for routine classification of sentinel lymph node metastases and its clinical relevance for patients with melanoma. *Cancer* 91:2110-2121.
- 114 van der Ploeg AP, van Akkooi AC and Rutkowski P et al (2011). Prognosis in patients with sentinel node-positive melanoma is accurately defined by the combined Rotterdam tumor load and Dewar topography criteria. *J Clin Oncol*. 29:2206-2214.
- 115 Murali R, Desilva C and Thompson JF et al (2010). Non-Sentinel Node Risk Score (N-SNORE): a scoring system for accurately stratifying risk of non-sentinel node positivity in patients with cutaneous melanoma with positive sentinel lymph nodes. *J Clin Oncol*. 28:4441-4449.
- 116 Cadili A, Scolyer RA and Brown PT et al (2010). Total sentinel lymph node tumor size predicts nonsentinel node metastasis and survival in patients with melanoma. *Ann Surg Oncol*. 17:3015-3020.
- 117 Scolyer RA, Li LX and McCarthy SW et al (2004). Micromorphometric features of positive sentinel lymph nodes predict involvement of nonsentinel nodes in patients with melanoma. *Am J Clin Pathol*. 122:532-539.
- 118 Gershenwald JE, Andtbacka RH, Prieto VG, Johnson MM, Diwan AH, Lee JE, Mansfield PF, Cormier JN, Schacherer CW and Ross MI (2008). Microscopic tumor burden in sentinel lymph nodes predicts synchronous nonsentinel lymph node involvement in patients with melanoma. *J Clin Oncol* 26(26):4296-4303.
- 119 Murali R, Cochran AJ and Cook MG et al (2009). Interobserver reproducibility of histologic parameters of melanoma deposits in sentinel lymph nodes: implications for management of patients with melanoma. *Cancer*. 115:5026-5037.
- 120 Gershenwald JE, Scolyer RA and Hess KR et al (2017). Melanoma of the Skin. In: *AJCC Cancer Staging Manual*. 8th ed Amin MB, Edge SB and Greene FL et al (eds), Springer New York, 563-585.

- 121 Australian Cancer Network Melanoma Guidelines Revision Working Party (2008). *Clinical Practice Guidelines for the Management of Melanoma in Australia and New Zealand*. Cancer Council Australia and Australian Cancer Network, Sydney and New Zealand Guidelines Group, Wellington.
- 122 Barnhill RL (2004). Malignant melanoma. In: *Pathology of Melanocytic Nevi and Malignant Melanoma*, Barnhill RL, Piepkorn M and Busam KJ (eds), Springer Publishing, New York, 238–356.
- 123 Massi D and LeBoit PE (2004). Patterns of melanoma in situ. In: *Histological Diagnosis of Nevi and Melanoma*, Steinkopff Verlag Darmstadt, Würzburg, Germany, 413–429.
- 124 Weyers W, Euler M, Diaz-Cascajo C, Schill WB and Bonczkowitz M (1999). Classification of cutaneous malignant melanoma: a reassessment of histopathologic criteria for the distinction of different types. *Cancer* 86(2):288-299.
- 125 Scolyer RA, Long GV and Thompson JF (2011). Evolving concepts in melanoma classification and their relevance to multidisciplinary melanoma patient care. *Mol Oncol*. 5(2):124-136.
- 126 Bastian BC (2014). The molecular pathology of melanoma: an integrated taxonomy of melanocytic neoplasia. *Annu Rev Pathol* 9:239-271.
- 127 WHO (World Health Organization) (2019). *World Health Organization Classification of Tumours. Pathology and Genetics of Skin Tumours*. 4th edition. IARC Press, Lyon, France.
- 128 Hodi FS, O'Day SJ, McDermott DF, Weber RW, Sosman JA, Haanen JB, Gonzalez R, Robert C, Schadendorf D, Hassel JC, Akerley W, van den Eertwegh AJ, Lutzky J, Lorigan P, Vaubel JM, Linette GP, Hogg D, Ottensmeier CH, Lebbe C, Peschel C, Quirt I, Clark JI, Wolchok JD, Weber JS, Tian J, Yellin MJ, Nichol GM, Hoos A and Urba WJ (2010). Improved survival with ipilimumab in patients with metastatic melanoma. *N Engl J Med* 363(8):711-723.
- 129 Robert C, Thomas L, Bondarenko I, O'Day S, Weber J, Garbe C, Lebbe C, Baurain JF, Testori A, Grob JJ, Davidson N, Richards J, Maio M, Hauschild A, Miller WH, Jr., Gascon P, Lotem M, Harmankaya K, Ibrahim R, Francis S, Chen TT, Humphrey R, Hoos A and Wolchok JD (2011). Ipilimumab plus dacarbazine for previously untreated metastatic melanoma. *N Engl J Med* 364(26):2517-2526.
- 130 Larkin J, Chiarion-Sileni V, Gonzalez R, Grob JJ, Cowey CL, Lao CD, Schadendorf D, Dummer R, Smylie M, Rutkowski P, Ferrucci PF, Hill A, Wagstaff J, Carlino MS, Haanen JB, Maio M, Marquez-Rodas I, McArthur GA, Ascierto PA, Long GV, Callahan MK, Postow MA, Grossmann K, Sznol M, Dreno B, Bastholt L, Yang A, Rollin LM, Horak C, Hodi FS and Wolchok JD (2015). Combined Nivolumab and Ipilimumab or Monotherapy in Untreated Melanoma. *N Engl J Med* 373(1):23-34.
- 131 Robert C, Long GV, Brady B, Dutriaux C, Maio M, Mortier L, Hassel JC, Rutkowski P, McNeil C, Kalinka-Warzocho E, Savage KJ, Hernberg MM, Lebbe C, Charles J, Mihalcioiu C, Chiarion-Sileni V, Mauch C, Cognetti F, Arance A, Schmidt H, Schadendorf D, Gogas H, Lundgren-Eriksson L, Horak C, Sharkey B,

- Waxman IM, Atkinson V and Ascierto PA (2015). Nivolumab in previously untreated melanoma without BRAF mutation. *N Engl J Med* 372(4):320-330.
- 132 Robert C, Schachter J, Long GV, Arance A, Grob JJ, Mortier L, Daud A, Carlino MS, McNeil C, Lotem M, Larkin J, Lorigan P, Neyns B, Blank CU, Hamid O, Mateus C, Shapira-Frommer R, Kosh M, Zhou H, Ibrahim N, Ebbinghaus S and Ribas A (2015). Pembrolizumab versus Ipilimumab in Advanced Melanoma. *N Engl J Med* 372(26):2521-2532.
- 133 Chapman PB, Hauschild A and Robert C et al (2011). Improved survival with vemurafenib in melanoma with BRAF V600E mutation. *N Engl J Med* 364:2507-2516.
- 134 Flaherty KT, Puzanov I and Kim KB et al (2010). Inhibition of mutated, activated BRAF in metastatic melanoma. *N Engl J Med* 363:809-819.
- 135 Falchook GS, Long GV, Kurzrock R, Kim KB, Arkenau TH, Brown MP, Hamid O, Infante JR, Millward M, Pavlick AC, O'Day SJ, Blackman SC, Curtis CM, Lebowitz P, Ma B, Ouellet D and Kefford RF (2012). Dabrafenib in patients with melanoma, untreated brain metastases, and other solid tumours: a phase 1 dose-escalation trial. *Lancet* 379(9829):1893-1901.
- 136 Hauschild A, Grob JJ, Demidov LV, Jouary T, Gutzmer R, Millward M, Rutkowski P, Blank CU, Miller WH, Jr., Kaempgen E, Martin-Algarra S, Karaszewska B, Mauch C, Chiarion-Sileni V, Martin AM, Swann S, Haney P, Mirakhur B, Guckert ME, Goodman V and Chapman PB (2012). Dabrafenib in BRAF-mutated metastatic melanoma: a multicentre, open-label, phase 3 randomised controlled trial. *Lancet* 380(9839):358-365.
- 137 Long GV, Trefzer U, Davies MA, Kefford RF, Ascierto PA, Chapman PB, Puzanov I, Hauschild A, Robert C, Algazi A, Mortier L, Tawbi H, Wilhelm T, Zimmer L, Switzky J, Swann S, Martin AM, Guckert M, Goodman V, Streit M, Kirkwood JM and Schadendorf D (2012). Dabrafenib in patients with Val600Glu or Val600Lys BRAF-mutant melanoma metastatic to the brain (BREAK-MB): a multicentre, open-label, phase 2 trial. *Lancet Oncol* 13(11):1087-1095.
- 138 Flaherty KT, Infante JR, Daud A, Gonzalez R, Kefford RF, Sosman J, Hamid O, Schuchter L, Cebon J, Ibrahim N, Kudchadkar R, Burris HA, 3rd, Falchook G, Algazi A, Lewis K, Long GV, Puzanov I, Lebowitz P, Singh A, Little S, Sun P, Allred A, Ouellet D, Kim KB, Patel K and Weber J (2012). Combined BRAF and MEK inhibition in melanoma with BRAF V600 mutations. *N Engl J Med* 367(18):1694-1703.
- 139 Larkin J, Ascierto PA, Dreno B, Atkinson V, Liskay G, Maio M, Mandala M, Demidov L, Stroyakovskiy D, Thomas L, de la Cruz-Merino L, Dutriaux C, Garbe C, Sovak MA, Chang I, Choong N, Hack SP, McArthur GA and Ribas A (2014). Combined vemurafenib and cobimetinib in BRAF-mutated melanoma. *N Engl J Med* 371(20):1867-1876.
- 140 Long GV, Stroyakovskiy D, Gogas H, Levchenko E, de Braud F, Larkin J, Garbe C, Jouary T, Hauschild A, Grob JJ, Chiarion Sileni V, Lebbe C, Mandala M, Millward M, Arance A, Bondarenko I, Haanen JB, Hansson J, Utikal J, Ferraresi V, Kovalenko N, Mohr P, Probachai V, Schadendorf D, Nathan P, Robert C, Ribas A, DeMarini DJ, Irani JG, Casey M, Ouellet D, Martin AM, Le N, Patel K and Flaherty K (2014).

Combined BRAF and MEK inhibition versus BRAF inhibition alone in melanoma. *N Engl J Med* 371(20):1877-1888.

- 141 Robert C, Karaszewska B, Schachter J, Rutkowski P, Mackiewicz A, Stroiakovski D, Lichinitser M, Dummer R, Grange F, Mortier L, Chiarion-Sileni V, Drucis K, Krajsova I, Hauschild A, Lorigan P, Wolter P, Long GV, Flaherty K, Nathan P, Ribas A, Martin AM, Sun P, Crist W, Legos J, Rubin SD, Little SM and Schadendorf D (2015). Improved overall survival in melanoma with combined dabrafenib and trametinib. *N Engl J Med* 372(1):30-39.
- 142 Long GV, Stroyakovskiy D, Gogas H, Levchenko E, de Braud F, Larkin J, Garbe C, Jouary T, Hauschild A, Grob JJ, Chiarion-Sileni V, Lebbe C, Mandala M, Millward M, Arance A, Bondarenko I, Haanen JB, Hansson J, Utikal J, Ferraresi V, Kovalenko N, Mohr P, Probachai V, Schadendorf D, Nathan P, Robert C, Ribas A, DeMarini DJ, Irani JG, Swann S, Legos JJ, Jin F, Mookerjee B and Flaherty K (2015). Dabrafenib and trametinib versus dabrafenib and placebo for Val600 BRAF-mutant melanoma: a multicentre, double-blind, phase 3 randomised controlled trial. *Lancet* 386(9992):444-451.
- 143 Long GV, Menzies AM, Nagrial AM, Haydu LE, Hamilton AL, Mann GJ, Hughes TM, Thompson JF, Scolyer RA and Kefford RF (2011). Prognostic and clinicopathologic associations of oncogenic BRAF in metastatic melanoma. *J Clin Oncol* 29(10):1239-1246.
- 144 Jakob JA, Bassett RL, Jr., Ng CS, Curry JL, Joseph RW, Alvarado GC, Rohlfs ML, Richard J, Gershenwald JE, Kim KB, Lazar AJ, Hwu P and Davies MA (2012). NRAS mutation status is an independent prognostic factor in metastatic melanoma. *Cancer* 118(16):4014-4023.
- 145 Gerami P, Jewell SS and Morrison LE et al (2009). Fluorescence in situ hybridization (FISH) as an ancillary diagnostic tool in the diagnosis of melanoma. *Am J Surg Pathol* 33:1146-1156.
- 146 Bastian BC, Wesselmann U, Pinkel D and Leboit PE (1999). Molecular cytogenetic analysis of Spitz nevi shows clear differences to melanoma. *J Invest Dermatol* 113(6):1065-1069.
- 147 Ko JS, Clarke LE, Minca EC, Brown K, Flake DD, 2nd and Billings SD (2018). Correlation of melanoma gene expression score with clinical outcomes on a series of melanocytic lesions. *Hum Pathol*.
- 148 Ko JS, Matharoo-Ball B, Billings SD, Thomson BJ, Tang JY, Sarin KY, Cai E, Kim J, Rock C, Kimbrell HZ, Flake DD, 2nd, Warf MB, Nelson J, Davis T, Miller C, Rushton K, Hartman AR, Wenstrup RJ and Clarke LE (2017). Diagnostic Distinction of Malignant Melanoma and Benign Nevi by a Gene Expression Signature and Correlation to Clinical Outcomes. *Cancer Epidemiol Biomarkers Prev* 26(7):1107-1113.
- 149 Bauer J (2017). The Molecular Revolution in Cutaneous Biology: Era of Cytogenetics and Copy Number Analysis. *J Invest Dermatol* 137(5):e57-e59.
- 150 Wittekind C (ed) (2012). *TNM Supplement : A Commentary on Uniform Use*, The Union for International Cancer Control (UICC), Wiley-Blackwell.

- 151 Balch CM, Gershenwald JE, Soong SJ, Thompson JF, Atkins MB, Byrd DR, Buzaid AC, Cochran AJ, Coit DG, Ding S, Eggermont AM, Flaherty KT, Gimotty PA, Kirkwood JM, McMasters KM, Mihm MC, Jr., Morton DL, Ross MI, Sober AJ and Sondak VK (2009). Final version of 2009 AJCC melanoma staging and classification. *J Clin Oncol* 27(36):6199-6206.
- 152 Balch CM, Gershenwald JE, Soong SJ, Thompson JF, Ding S, Byrd DR, Cascinelli N, Cochran AJ, Coit DG, Eggermont AM, Johnson T, Kirkwood JM, Leong SP, McMasters KM, Mihm MC, Jr., Morton DL, Ross MI and Sondak VK (2010). Multivariate analysis of prognostic factors among 2,313 patients with stage III melanoma: comparison of nodal micrometastases versus macrometastases. *J Clin Oncol* 28(14):2452-2459.
- 153 Egger ME, Bower MR, Czyszczon IA, Farghaly H, Noyes RD, Reintgen DS, Martin RC, 2nd, Scoggins CR, Stromberg AJ and McMasters KM (2014). Comparison of sentinel lymph node micrometastatic tumor burden measurements in melanoma. *J Am Coll Surg* 218(4):519-528.
- 154 Fink AM, Weihsengruber F, Duschek N, Schierl M, Wondratsch H, Jurecka W, Rappersberger K and Steiner A (2011). Value of micromorphometric criteria of sentinel lymph node metastases in predicting further nonsentinel lymph node metastases in patients with melanoma. *Melanoma Res* 21(2):139-143.
- 155 Frankel TL, Griffith KA, Lowe L, Wong SL, Bichakjian CK, Chang AE, Cimmino VM, Bradford CR, Rees RS, Johnson TM and Sabel MS (2008). Do micromorphometric features of metastatic deposits within sentinel nodes predict nonsentinel lymph node involvement in melanoma? *Ann Surg Oncol* 15(9):2403-2411.
- 156 Ranieri JM, Wagner JD, Azuaje R, Davidson D, Wenck S, Fyffe J and Coleman JJ, 3rd (2002). Prognostic importance of lymph node tumor burden in melanoma patients staged by sentinel node biopsy. *Ann Surg Oncol* 9(10):975-981.
- 157 van der Ploeg AP, van Akkooi AC, Haydu LE, Scolyer RA, Murali R, Verhoef C, Thompson JF and Eggermont AM (2014). The prognostic significance of sentinel node tumour burden in melanoma patients: an international, multicenter study of 1539 sentinel node-positive melanoma patients. *Eur J Cancer* 50(1):111-120.
- 158 Balch CM, Soong S, Ross MI, Urist MM, Karakousis CP, Temple WJ, Mihm MC, Barnhill RL, Jewell WR, Wanebo HJ and Harrison R (2000). Long-term results of a multi-institutional randomized trial comparing prognostic factors and surgical results for intermediate thickness melanomas (1.0 to 4.0 mm). Intergroup Melanoma Surgical Trial. *Ann Surg Oncol* 7(2):87-97.
- 159 Cascinelli N, Belli F, Santinami M, Fait V, Testori A, Ruka W, Cavaliere R, Mozzillo N, Rossi CR, MacKie RM, Nieweg O, Pace M and Kirov K (2000). Sentinel lymph node biopsy in cutaneous melanoma: the WHO Melanoma Program experience. *Ann Surg Oncol* 7(6):469-474.