

Thymic Epithelial Tumours Histopathology Reporting Guide



Family/Last name Date of birth

Given name(s)

Patient identifiers Date of request Accession/Laboratory number

Elements in **black text** are **CORE**. Elements in **grey text** are **NON-CORE**.

indicates multi-select values indicates single select values

SCOPE OF THIS DATASET

CLINICAL INFORMATION (select all that apply) (Note 1)

- Not provided
- Myasthenia gravis
- Pure red cell aplasia
- Rheumatoid arthritis
- Lupus
- Addison's disease
- Cushing's disease
- Hypogammaglobulinemia (Good's syndrome)
- Previous neoplasm, *specify*
- Preoperative therapy, *specify*
- Other, *specify*

OPERATIVE PROCEDURE (Note 2)

- Not specified
- Partial thymectomy
- Radical thymectomy
- Extended thymectomy
- Total thymectomy
- Other, *specify*

SPECIMEN(S) SUBMITTED (select all that apply) (Note 3)

- Not specified
- Partial thymus
- Complete thymus
- Thymus plus surrounding tissue (extended thymectomy)
- Mediastinal pleura
- Anterior mediastinal (pre-vascular) mass
- Pericardium
- Lung
 - Left
 - Wedge biopsy
 - Upper lobe
 - Lower lobe
 - Lobectomy
 - Upper lobe
 - Lower lobe
 - Pneumonectomy
 - Right
 - Wedge biopsy
 - Upper lobe
 - Middle lobe
 - Lower lobe
 - Lobectomy
 - Upper lobe
 - Middle lobe
 - Lower lobe
 - Pneumonectomy

- Phrenic nerve
 - Left Right Laterality not specified
- Great vessels
 - Brachiocephalic (innominate) vein
 - Left Right Laterality not specified
 - Superior vena cava
 - Extrapericardial pulmonary artery/veins
 - Aorta (ascending, arch or descending)
 - Arch vessels
 - Intrapericardial pulmonary artery
- Myocardium
- Diaphragm
- Separate extrathymic tumour nodules, *specify*
- Lymph nodes, *specify site(s)*
- Other, *specify*

SPECIMEN INTEGRITY (Note 4)

- Intact specimen
- Surface disrupted
- Fragmented specimen

MACROSCOPIC SITE OF PRIMARY TUMOUR (Note 5)

- Not specified
- Thymic
 - Single tumour
 - >1 tumour
- Ectopic, *specify site(s)*

MAXIMUM DIMENSION OF PRIMARY TUMOUR (Note 6)

- Cannot be assessed

BLOCK IDENTIFICATION KEY (Note 7)

(List overleaf or separately with an indication of the nature and origin of all tissue blocks)

HISTOLOGICAL TUMOUR TYPE (Note 8)

(Value list from the World Health Organization, Classification of Thoracic Tumours (2021))^a

Thymoma

- Not identified
- Present

Predominant subtype

	➔	%
--	---	---

Other subtypes

	➔	%
--	---	---

	➔	%
--	---	---

	➔	%
--	---	---

Thymic carcinoma

- Not identified
- Present

Predominant subtype

	➔	%
--	---	---

Other subtypes

	➔	%
--	---	---

	➔	%
--	---	---

	➔	%
--	---	---

Thymic neuroendocrine tumours

- Not identified
- Present

Typical carcinoid/ Neuroendocrine tumour, grade 1	➔	%
--	---	---

Atypical carcinoid/ Neuroendocrine tumour, grade 2	➔	%
---	---	---

Thymic neuroendocrine carcinomas

- Not identified
- Present

Large cell neuroendocrine carcinoma	➔	%
-------------------------------------	---	---

Small cell carcinoma	➔	%
----------------------	---	---

Final histological diagnosis

(Use 2021 WHO Classification for combined tumours)

--	--

^a Where relevant, if more than one subtype, list in 10% increments.

EXTENT OF DIRECT INVASION (Note 9)

Thymus

- No invasion beyond capsule or limit of the thymus
- Invasion beyond the mediastinum

Mediastinal pleura

- Not applicable
- Cannot be assessed
- Not involved
- Involved

Pericardium

- Not applicable
- Cannot be assessed
- Not involved
- Involved

Lung (pulmonary parenchyma, visceral pleura, or both)

- Not applicable
- Cannot be assessed
- Not involved
- Involved, specify lobe(s) of the lung

--

GREAT VESSELS

Brachiocephalic (innominate) vein

- Not applicable
- Cannot be assessed
- Not involved
- Involved

Superior vena cava

- Not applicable
- Cannot be assessed
- Not involved
- Involved

Extrapericardial pulmonary artery or veins

- Not applicable
- Cannot be assessed
- Not involved
- Involved

Aorta (ascending, arch or descending)

- Not applicable
- Cannot be assessed
- Not involved
- Involved

Arch vessels

- Not applicable
- Cannot be assessed
- Not involved
- Involved

Intrapericardial pulmonary artery

- Not applicable
- Cannot be assessed
- Not involved
- Involved

Phrenic nerve

- Not applicable
- Cannot be assessed
- Not involved
- Involved

Other involved organ(s)/site(s) by direct spread

--

SEPARATE EXTRATHYMIC TUMOUR NODULES/METASTASES (Note 10)

Pleural and/or pericardial

- Not identified
- Present

Specify location(s) Specify number/location

	→	
	→	
	→	

Pulmonary intraparenchymal

- Not identified
- Present

Distant organ

- Not identified
- Present, *specify site(s)*

RESPONSE TO NEOADJUVANT THERAPY (Note 11)

- Cannot be assessed
- Prior treatment not known
- No prior treatment
- No response
- Response present

Percentage viable tumour^b %

^b If more than one tumour is present record the percent viable tumour in each.

MARGIN STATUS (Note 12)

- Cannot be assessed
- Not involved
- Involved
- Macroscopic, *specify margin(s), if possible*

- Microscopic, *specify margin(s), if possible*

LYMPH NODE STATUS (Note 13)

- No nodes submitted or found
- Not involved
- Involved (select all that apply)

Anterior (perithymic) nodes (N1)

Number of lymph nodes examined

Number of positive lymph nodes

- Number cannot be determined

Deep intrathoracic or cervical nodes (N2)

Number of lymph nodes examined

Number of positive lymph nodes

- Number cannot be determined

Unspecified location within N1 or N2

Number of lymph nodes examined

Number of positive lymph nodes

- Number cannot be determined

Location(s) outside N1 or N2 (M1b disease)

Number of lymph nodes examined

Number of positive lymph nodes

- Number cannot be determined

COEXISTENT PATHOLOGY (select all that apply) (Note 14)

- Thymic hyperplasia
 - Follicular
 - Epithelial
 - True
 - Lymphoepithelial sialadenitis-like

- Cystic changes
 - In tumour
 - In adjacent thymus

Other, *specify*

ANCILLARY STUDIES**Immunohistochemical markers^c** (Note 15) Not performed Performed

Positive markers	
Negative markers	
Equivocal markers	

Interpretation and conclusions

Molecular studies (Note 16) Not performed Performed, *specify test(s) and result(s)*

Representative blocks for ancillary studies, *specify those blocks best representing tumour and/or normal tissue for further study*

^c *Applicable to all biopsies, thymectomy and resection specimens of thymic carcinomas and thymic neuroendocrine tumours.*

HISTOLOGICALLY CONFIRMED DISTANT METASTASES (Note 17) Not identified Present, *specify site(s)*

PATHOLOGICAL STAGING (Note 18)**TNM 8th edition pathologic staging for thymic epithelial tumours^d****TNM Descriptors** (only if applicable) (select all that apply) m - multiple primary tumours r - recurrent y - post-therapy**Primary tumour (pT)** TX^e Primary tumour cannot be assessed T0 No evidence of primary tumour T1 Tumour encapsulated or extending into the mediastinal fat, may involve the mediastinal pleura T1a No mediastinal pleural involvement T1b Direct invasion of the mediastinal pleura T2 Tumour with direct involvement of the pericardium (partial or full thickness) T3 Tumour with direct invasion into any of the following: lung, brachiocephalic vein, superior vena cava, phrenic nerve, chest wall, or extrapericardial pulmonary artery or vein T4 Tumour with direct invasion into any of the following: aorta (ascending, arch or descending), arch vessels, intrapericardial pulmonary artery, myocardium, trachea or oesophagus**Regional lymph nodes (pN)** No nodes submitted or found NX^e Regional lymph nodes cannot be assessed N0 No regional lymph node metastasis N1 Metastasis in anterior (perithymic) lymph nodes N2 Metastasis in deep intrathoracic or cervical lymph

^d *Reproduced with permission. Source: UICC TNM Classification of Malignant Tumours, 8th Edition, eds by James D. Brierley, Mary K. Gospodarowicz, Christian Wittekind. 2016, Publisher Wiley. (incorporating any errata published up until 6th October 2020).*

^e *TX and NX should be used only if absolutely necessary.*

Pathologic staging for thymomas and thymic carcinomas - modified Masaoka (with updated ITMIG definitions) Not applicable Cannot be determined I Grossly and microscopically completely encapsulated tumour IIa Microscopic transcapsular invasion IIb Macroscopic invasion into thymic or surrounding fatty tissue, or grossly adherent to but not breaking through mediastinal pleura or pericardium III Macroscopic invasion into neighbouring organ (i.e., pericardium, great vessel or lung) IVa Pleural or pericardial metastases IVb Lymphogenous or haematogenous metastases

Definitions

CORE elements

CORE elements are those which are essential for the clinical management, staging or prognosis of the cancer. These elements will either have evidentiary support at Level III-2 or above (based on prognostic factors in the National Health and Medical Research Council (NHMRC) levels of evidence¹). In rare circumstances, where level III-2 evidence is not available an element may be made a CORE element where there is unanimous agreement in the expert committee. An appropriate staging system e.g., Pathological TNM staging would normally be included as a CORE element.

The summation of all CORE elements is considered to be the minimum reporting standard for a specific cancer.

NON-CORE elements

NON-CORE elements are those which are unanimously agreed should be included in the dataset but are not supported by level III-2 evidence. These elements may be clinically important and recommended as good practice but are not yet validated or regularly used in patient management.

Key information other than that which is essential for clinical management, staging or prognosis of the cancer such as macroscopic observations and interpretation, which are fundamental to the histological diagnosis and conclusion e.g., macroscopic tumour details, may be included as either CORE or NON-CORE elements by consensus of the Dataset Authoring Committee.

[↑ Back](#)

Scope

This dataset has been developed for thymic epithelial tumours (TET). It applies to resection specimens of the thymus and is applicable for thymoma, neuroendocrine tumours of the thymus and thymic carcinoma but does not cover germ cell tumours, soft tissue tumours, haematolymphoid neoplasms, and other primary thymic neoplasms.

The third edition of this dataset includes changes to align the dataset with the World Health Organization (WHO) Classification of Thoracic Tumours, 5th edition, 2021.²

[↑ Back](#)

Note 1 – Clinical information (Non-core)

It is helpful to know whether the patient has myasthenia gravis, other autoimmune diseases, paraneoplastic syndromes, or other conditions that can be associated with thymomas. Knowledge of any neoadjuvant treatment is important as it may explain necrosis and scarring seen macroscopically and microscopically, and allows the pathologist to comment on histologic treatment response.^{3,4} It is also important to know of any other neoplasm the patient might have given that the anterior (prevascular) mediastinum is a common place for metastatic disease.

If clinical conditions other than those listed are provided, then these should be noted under ‘Other, specify’.

 [Back](#)

Note 2 – Operative procedure (Non-core)

Documentation of the operative procedure is useful, as correlation of the type of procedure with the material received can be important for both pathological diagnosis and patient safety. Further, the type of surgical procedure is important in determining the assessment of surgical margins.⁵

The surgeon should inform the pathologist of the type of operation/procedure.

A thymectomy is an operation to remove the thymus. A partial thymectomy is the removal of less than the whole thymus. A total (standard) thymectomy is the removal of the thymus gland without surrounding fatty tissue. An extended thymectomy is the removal of the thymus gland including the fatty tissue of the mediastinum and neck. Sampling of lymph nodes may include left, right, or bilateral lymph nodes, anterior and deep lymph nodes.

 [Back](#)

Note 3 – Specimen(s) submitted (Core)

Specimen type should indicate what was submitted.⁵ Specimen type varies according to the type of operation. If the specimen was obtained by an extended thymectomy, the specimen type is indicated as ‘Thymus plus surrounding tissue’.

Specimens obtained by combined resection with other organs or parts thereof, should be itemised, such as lung, pleura, pericardium, great vessels, and myocardium. Other organs or tissues are reported as ‘Other’ and details should be recorded.⁵⁻⁷

Separate extrathymic tumour nodules submitted should be recorded; these include pleural and pericardial implants, pulmonary intraparenchymal nodules, and distant organ metastases. The location, number and size of extrathymic nodules are described later in the dataset (see **Note 10 SEPARATE EXTRATHYMIC TUMOUR NODULES/METASTASES**).

Submitted lymph nodes should also be recorded.^{8,9} These may be submitted separately or within a combined mediastinal specimen, so labelling or discussion with the surgeon may be required. Further details on lymph nodes are captured later in the dataset (see **Note 13 LYMPH NODE STATUS**).

Orientation of the specimen is crucial given the prognostic importance of margin status and pathologic tumour stage in resected TETs. Once the tumour is removed from the tumour bed, orientation becomes difficult.

Furthermore, the fatty tissue can become easily disrupted. Therefore, orientation of the specimen ideally should be started in situ by the surgeon and areas of concern need to be clearly communicated to the pathologist. Orientating the specimen on a mediastinal board is encouraged (Figure 1).⁵ Anterior, posterior, right and left surfaces should be clearly distinguished (e.g., inked with different colours or with a detailed block key). Furthermore, the surgeon should mark areas of concern such as right/left mediastinal pleural surfaces and pericardium (if resected), and also areas adjacent to the pericardium, the innominate (brachiocephalic) vein and superior vena cava (or mark these structures if resected).

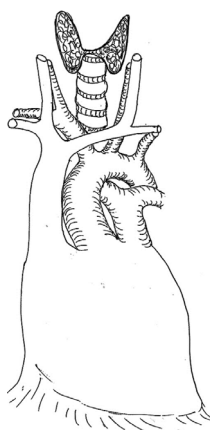


Figure 1: Mediastinal board that could be used to orient the specimen.⁵ A diagram on a soft board is useful in maintaining proper dimensions and orientation of specimens. Printing this figure as a full page corresponds roughly to the normal mediastinal dimensions and can be placed directly on a standard soft specimen board that is generally available in surgical pathology departments.

Reproduced from Detterbeck FC, Moran C, Huang J, Suster S, Walsh G, Kaiser L and Wick M (2011). Which way is up? Policies and procedures for surgeons and pathologists regarding resection specimens of thymic malignancy. *J Thorac Oncol* 6:S1730-1738 with permission from Elsevier.

↑ Back

Note 4 – Specimen integrity (Core)

Although there are no studies specifically evaluating the prognosis of patients who underwent thymectomy where the capsule was disrupted intraoperatively or the lesion was resected in fragments, it is important to record these features because in these circumstances the pathologist cannot properly evaluate the completeness of resection.^{5,7} Completeness of resection is an important prognostic feature. Specimen integrity is recorded as:

- ‘Intact specimen’ which refers to a TET that is either completely surrounded by a fibrous capsule or is present in its entirety within the submitted specimen, without rupture of the tumour into surrounding tissues or on to the external surface of the specimen.
- ‘Surface disrupted’ which refers to a TET that remains in one piece but shows exposure of the tumour onto the external surface of the specimen, secondary to disruption, or
- ‘Fragmented specimen’ which refers to a TET that is submitted in piecemeal form that precludes satisfactory identification of margins and usually orientation.

It is important to capture this information during the gross examination before sectioning the specimen.

↑ Back

Note 5 – Macroscopic site of primary tumour (Non-core)

Thymic epithelial tumours (TET) usually arise as a single nodule or mass in the thymus in the anterior (prevascular) mediastinum. However, cases of multiple, synchronous TETs have been described.¹⁰⁻¹² Although synchronous TETs generally occur in the thymus in the anterior (prevascular) mediastinum, these tumours can also occur at ectopic sites. Although rare, ectopic TETs have been described in the neck, posterior (paravertebral) mediastinum, pretracheal fat, deep to phrenic nerves, posterior to brachiocephalic (innominate) vein, aortopulmonary window, aortocaval groove, anterior (prevascular) mediastinal fat, cardiophrenic fat, and base of skull. Ectopic thymomas can also present in the lung, where they should be dealt with as primary pulmonary neoplasms. Importantly, ectopic TETs should be distinguished from pleural or pericardial implants and metastases because the latter will up-stage the tumour. Many reported synchronous TETs differ in tumour subtype and stage. In addition, a case of synchronous thymoma and thymic carcinoid tumour has been reported in a patient with multiple neuroendocrine neoplasia type I.¹³ Therefore, when synchronous TETs are identified, each tumour should be recorded, microscopically reviewed and staged separately.

↑ Back

Note 6 – Maximum dimension of primary tumour (Non-core)

Tumour size has not consistently been shown to be of prognostic value for TET. For instance, a retrospective analysis of 5,845 cases showed that size was not useful in predicting survival in relation to staging of TETs although other studies have supported the prognostic significance of TET size,^{14,15} so this is viewed as a non-core rather than as a core element.⁷

Identification of the primary tumour may be uncertain in cases with multiple foci and therefore, the maximum dimension of the largest tumour should be recorded.

The maximum tumour size should still be recorded as the number of blocks sampled in a resected tumour is recommended to be 1 per 10 millimetre (mm) of the maximum diameter. Inadequate sampling may lead to incorrect tumour classification.¹⁶

↑ Back

Note 7 – Block identification key (Non-core)

The origin/designation of all tissue blocks should be recorded. This information should ideally be documented in the final pathology report and is particularly important should the need for internal or external review arise. The reviewer needs to be clear about the origin of each block in order to provide an informed specialist opinion. If this information is not included in the final pathology report, it should be available on the laboratory computer system and relayed to the reviewing pathologist. It may be useful to have a digital image of the specimen and record of the origin of the tumour blocks in some cases.

Recording the origin/designation of tissue blocks also facilitates retrieval of blocks for further immunohistochemical or molecular analysis, research studies, or clinical trials.

↑ Back

Note 8 – Histological tumour type (Core)

All thymic tumours should be classified according to the most recent edition of the WHO Classification of Thoracic Tumours, 5th edition, 2021 (Table 2).²

In cases of TETs showing more than one morphological subtype the following should be applied:

1. TETs showing more than one histological thymoma subtype: The diagnosis in such tumours should list all the histological WHO types, starting with the predominant component and then minor components. All should be quantified in 10% increments. This rule does not apply to AB thymoma which is a distinct entity (this should be documented as type AB 100%).
2. TETs consisting of a thymic carcinoma component together with one or more thymoma component(s): Irrespective of the size/percentage of the thymic carcinoma component the diagnosis in such tumours should be labelled as ‘Combined thymic carcinoma and thymoma’ followed by the histological subtype and percentage of the ‘thymic carcinoma’ then by the thymoma component(s) (quantified in 10% increments).
3. TETs consisting of more than one thymic carcinoma component (with or without a thymoma component, and excluding thymic small cell carcinoma and thymic large cell neuroendocrine carcinoma, see below): the diagnosis in such tumours should begin with the predominant carcinoma (specifying the histological subtype and percentage) then minor carcinoma components should be histologically specified and quantified in 10% increments, and finally by the thymoma components, if present.
4. TETs consisting of thymic carcinoma and carcinoid should be reported as ‘Combined thymic carcinoma and carcinoid’ followed by first the ‘thymic carcinoma’ (specifying the histological subtype and percentage) then by the carcinoid (specifying the histologic subtype and quantified in 10% increments).
5. Heterogeneous thymic tumours with a small cell or large cell neuroendocrine carcinoma component: Irrespective of the size/percentage of the small cell and large cell neuroendocrine carcinoma component, such tumours are labelled as ‘combined small cell carcinoma’ or ‘combined large cell neuroendocrine carcinoma’; the various components should be given and quantified in 10% increments.
6. TETs consisting of a thymic carcinoid and thymoma: Irrespective of the size/percentage of the thymic carcinoid component, such tumours should be labelled as ‘Combined carcinoid and thymoma’ and then list the carcinoid first followed by thymoma component(s) each in 10% increments.

Table 1: Reporting of heterogeneous tumours showing more than one histological type of thymic epithelial tumour.

Component 1	Component 2	Terminology/reported diagnosis
Thymoma	Thymoma of a different type	Thymoma (state the components in 10% increments; start reporting with the most prevalent component)
Thymic carcinoma	Thymoma	Combined thymic carcinoma and thymoma
Thymic carcinoma	Thymic carcinoma of a different type	Combined thymic carcinoma (state the components in 10% increments; start reporting with the most prevalent component)
Thymic carcinoma	Carcinoid	Combined thymic carcinoma and carcinoid
Carcinoid	Thymoma	Combined carcinoid and thymoma
Small cell carcinoma	Thymic carcinoma	Combined small cell carcinoma and thymic carcinoma
Small cell carcinoma	Thymoma	Combined small cell carcinoma and thymoma
Small cell carcinoma	Carcinoid	Combined small cell carcinoma and carcinoid
Small cell carcinoma	LCNEC (<10%)	Small cell carcinoma
Small cell carcinoma	LCNEC (≥10%)	Combined small cell carcinoma and LCNEC
LCNEC	Thymic carcinoma	Combined LCNEC and thymic carcinoma
LCNEC	Thymoma	Combined LCNEC and thymoma
LCNEC	Carcinoid	Combined LCNEC and carcinoid

LCNEC, large cell neuroendocrine carcinoma.

Table 2: World Health Organization classification of tumours of the thymus.²

Descriptor	ICD-O code ^a
EPITHELIAL TUMOURS	
Thymomas	
Thymoma, NOS	8580/3
Thymoma, type A, including atypical variant	8581/3
Thymoma, type AB	8582/3
Thymoma, type B1	8583/3
Thymoma, type B2	8584/3
Thymoma, type B3	8585/3
Micronodular thymoma with lymphoid stroma	8580/1
Metaplastic thymoma	8580/3
Lipofibroadenoma	9010/0
Squamous cell carcinomas	
Squamous cell carcinoma, including subtype Micronodular carcinoma with lymphoid hyperplasia	8070/3
Basaloid carcinoma	8123/3
Lymphoepithelial carcinoma [†]	8082/3

Descriptor	ICD-O code ^a
Adenocarcinomas	
Adenocarcinoma, NOS	8140/3
Low-grade papillary adenocarcinoma†	8260/3
Thymic carcinoma with adenoid cystic carcinoma–like features	8200/3
Adenocarcinoma, enteric-type†	8144/3
Adenosquamous carcinomas	
Adenosquamous carcinomas	8560/3
NUT carcinomas	
NUT carcinoma	8023/3
Salivary gland–like carcinomas	
Mucoepidermoid carcinoma	8430/3
Clear cell carcinoma, including subtype hyalinising clear cell carcinoma	8310/3
Sarcomatoid carcinomas	8033/3
Carcinosarcoma	8980/3
Undifferentiated carcinomas	
Carcinoma, undifferentiated, NOS	8020/3
Thymic carcinomas NOS	8586/3
THYMIC NEUROENDOCRINE NEOPLASMS	
Neuroendocrine tumours	
Carcinoid tumour, NOS / neuroendocrine tumour, NOS	8240/3
Typical carcinoid / neuroendocrine tumour, grade 1	8240/3
Atypical carcinoid / neuroendocrine tumour, grade 2	8249/3
Neuroendocrine carcinomas	
Small cell carcinoma	8041/3
Combined small cell carcinoma	8045/3
Large cell neuroendocrine carcinoma	8013/3

^a These morphology codes are from the International Classification of Diseases for Oncology, third edition, second revision (ICD-O-3.2).¹⁷ Behaviour is coded /0 for benign tumours; /1 for unspecified, borderline, or uncertain behaviour; /2 for carcinoma in situ and grade III intraepithelial neoplasia; /3 for malignant tumours, primary site; and /6 for malignant tumours, metastatic site. Behaviour code /6 is not generally used by cancer registries.

This classification is modified from the previous 2015 WHO classification, taking into account changes in our understanding of these lesions. Subtype labels are indented.

† Labels marked with a dagger constitute a change in terminology of a previous code.

© World Health Organization/International Agency for Research on Cancer. Reproduced with permission.

↑ Back

Note 9 – Extent of direct invasion (Non-core)

The TNM staging as described in the Union for International Cancer Control (UICC)¹⁸/American Joint Committee on Cancer (AJCC)¹⁹ 8th Edition Staging Manuals is used for all TETs including thymomas, thymic carcinomas, and thymic neuroendocrine tumours. This TNM classification is based on data from the International Thymic Malignancy Interest Group (ITMIG) retrospective database of over 8,000 patients analysed by the International Association for the Study of Lung Cancer (IASLC), Thymic Domain Committee.^{7,9} Previously, the Masaoka-Koga system has been the most frequently used for staging,^{20,21} with refinement of definitions for anatomic staging parameters proposed in 2011.²² While the TNM staging^{18,19} should be the system that is now primarily used, the Masaoka-Koga stage might also be reported separately as some clinical trials and protocols are still based on that system. The T category is dependent on extent of direct local invasion.

Invasion of pericardium is defined as invasion of the TET into the fibrous (parietal) pericardium,⁶ either partial or full-thickness. Use of an elastic stain might be helpful in some occasions in assessing involvement of mediastinal structures in relation to elastic layers within mediastinal and visceral pleura, and the adventitia and media of the great vessels. Detterbeck et al (2011) defined invasion into pleura as a discontinuous elastic layer adjacent to tumour,²² however the application of this criteria can be challenging.

In relation to the TNM-based staging system,^{18,19} the presence of capsular invasion was not prognostically significant in data from the ITMIG retrospective database study and tumours are therefore categorised as pT1a, independent of whether the capsule is breached, if the tumour has not directly infiltrated the mediastinal pleura.⁶ Similar data were found in separate meta-analyses.^{7,23} Invasion through the mediastinal pleura was also not found to be of prognostic significance in the cases from the ITMIG database, although evidence from Japanese patients demonstrated that invasion of the mediastinal pleura was associated with the cumulative incidence of recurrence.²⁴ So this parameter remains part of the dataset, to be collected for further review and is categorised as pT1b, although it is recognised that this anatomic margin may not be easily identifiable on histology.⁷ Identification of the mediastinal pleura requires the surgeon to mark the structure at time of resection.⁵

To maintain consistency in data collection, the following definitions, agreed by expert consensus, were proposed by an ITMIG-based group (unpublished observations):

- Pericardial invasion - microscopic involvement of the pericardium (either partial in the fibrous layer or penetrating through the serosal layer);
- Visceral pleura - microscopically confirmed direct penetration through the outer elastin layer of the visceral pleura without invasion into the lung parenchyma.
- Lung - microscopic invasion through pleura into pulmonary parenchyma.

In relation to the great vessels, opinions differed between involvement being defined as tumour cells being present within the adventitia, media, or lumen. The consensus opinion, in the context of great vessels, was that tumour cells present within the media is the preferred histological compartment through which to define involvement, as it is easily seen compared to the adventitia on an elastic stain, and its involvement is likely relevant to surgical management in terms of need for partial resection and repair. Similarly, involvement of the phrenic nerve is defined as tumour cells being present within the perineurium. However, any type of entrapment of the nerve should be recorded, although sole entrapment of the nerve without perineural or neural invasion is not classified as pT3. 'Other' should be used if tumours infiltrate structures such as myocardium, trachea, oesophagus, or chest wall. Involvement of muscle layers is viewed as the most reproducible parameter through which to collect data on positive involvement.

 [Back](#)

Note 10 – Separate extrathymic tumour nodules/metastases (Core and Non-core)

Recording of separate extrathymic tumour nodules is important as they form part of the TNM staging system.^{18,19} These are divided into two groups: first, those nodules that are limited to the pericardium and/or pleura (in general referred to as pericardial and pleural implants), which constitute pM1a in TNM staging^{18,19}; second, nodules that are either within the lung parenchyma or distant organs, which constitute metastatic disease or pM1b.^{5,8} The number of nodules in the pleura/pericardium should be recorded as there is some evidence that greater numbers portend an adverse prognosis.²⁵

These synchronous metastatic foci will usually have the same morphology as the primary thymic neoplasm and need to be distinguished from the far rarer synchronous primary TET (see **Note 5 MACROSCOPIC SITE OF PRIMARY TUMOUR**).^{11,12}

↑ Back

Note 11 – Response to neoadjuvant therapy (Non-core)

There is no recommended or agreed system for assessing tumour regression in TETs. There are sparse reports documenting the effects of neoadjuvant therapy on TETs,^{26,4} but there are no systematic studies on this subject that show an association between tumour regression and outcome of patients. In other organ systems including carcinomas of the breast, stomach, oesophagus, and colorectum, there is evidence that the response to neoadjuvant therapy provides prognostic information. Steroid therapy may also affect morphology by eliminating lymphocytes although this is not viewed as part of neoadjuvant therapy.

In TETs, RECIST (Response Evaluation Criteria In Solid Tumours) parameters have been recorded as indicators of tumour regression. Histological features which have been assessed as indicators for tumour regression include percent necrosis and percent viable tumour on the basis of the entire tumour bed,⁴ decrease in number of viable cells,^{27,28} fibrosis,^{29,4} necrosis,^{30,31,4} cystic change,⁴ foamy histiocytes, calcifications, and cholesterol clefts.⁴ It should be noted that similar changes to those documented in neoadjuvant treated TETs may be observed in non-treated thymomas (necrosis, cystic change) as degenerative features.²⁶ Biological cell cycle markers (e.g., p53) were used in one study by Mineo et al (2010).²⁸ However, few studies have systematically recorded tumour regression elements in a methodical fashion,^{26,4,32} and there are no studies which have shown a correlation of tumour regression with disease outcome. While there is currently no well established tumour regression scoring system for TET, the College of American Pathologists Protocol for the examination of specimens from patients with thymic tumors³³ suggests to report the percent viable tumour.

It is recommended that the response to neoadjuvant treatment in TET be recorded with the following provisos:

1. The amount of viable tumour should be assessed as a percentage of the tumour on resection specimens, including metastases and implants; and
2. Resected specimens should be adequately sampled (at least one block per 10 mm of maximum tumour diameter) or in patients with complete pathologic response, the entire tumour if feasible.

↑ Back

Note 12 – Margin status (Core)

Complete resection has been repeatedly shown to be a prognostic parameter in thymomas and thymic carcinomas.³⁴⁻³⁶ Therefore, the evaluation and recording of the margin status is important. If the thymus is disrupted it may be difficult to assess margin status. To be able to assess the margins, orientation of the specimen is crucial. As discussed earlier (see **Note 5 MACROSCOPIC SITE OF PRIMARY TUMOUR**), once the tumour is removed from the tumour bed, orientation becomes difficult. Furthermore, the fatty tissue can become easily disrupted. Therefore, orientation of the specimen should ideally be started in situ by the surgeon and areas of concern need to be clearly communicated to the pathologist. Anterior, posterior, right and left surfaces should be clearly distinguished (e.g., inked with different colours or with a detailed block key). Furthermore, the surgeon should mark areas of concern: right/left mediastinal pleura and pericardium (if resected) and also representative areas adjacent to the pericardium, the large vessels (or mark these structures if resected). If the resection specimen includes neighbouring organs such as lung, or large vessels, margins need to be evaluated on those organs as well. However, only truly surgically resected areas should be marked as margins as not every surface of the resection specimen represents a surgical margin that potentially could be re-resected if found involved by the TET. As noted, orientation by the surgeon is imperative.

R0 resection is defined as complete resection without macroscopic or microscopic involvement of the margin by the tumour. R1 (incomplete) resection indicates microscopic tumour at the resection margin. R2 (incomplete) resection is defined as macroscopic tumour present at the resection margin. If the specimen is disrupted at the time of gross evaluation and cannot be reconstructed, then the assessment of margins might not be possible.

 [Back](#)

Note 13 – Lymph node status (Core)

Involvement of lymph nodes by TETs is an adverse prognostic factor.^{8,37} Lymph node status should be recorded according to the recommended anatomic map in relation to the ITMIG and IASLC TNM system,^{8,9} namely anterior (perithymic) nodes (N1) and deep intrathoracic or cervical nodes (N2), whilst any positive lymph node was viewed as stage IVb within the Masaoka-Koga system.²¹ As the location of lymph nodes found during the gross inspection of a thymectomy specimen may be problematic, the specimen needs to be either properly oriented by the surgeon or placed into separate pots that are each labelled specifically. Lymph nodes outside N1 and N2 are regarded as distant metastasis (pM1b).⁸ Direct invasion of the TET into a lymph node is regarded as lymph node involvement.⁸

 [Back](#)

Note 14 – Coexistent pathology (Non-core)

Thymectomy specimens from myasthenia gravis patients commonly demonstrate pathologic findings in the non-neoplastic thymus and the most common feature is thymic follicular hyperplasia. While thymic hyperplasia can be classified into four types: follicular, epithelial, true and lymphoepithelial sialadenitis-like hyperplasia, essentially only follicular hyperplasia and possibly epithelial hyperplasia play a role in thymectomy specimens for TET. Follicular hyperplasia is defined by the presence of B-cell follicles irrespective of the size or weight of the thymus.^{38,39} Epithelial hyperplasia (nodular epithelial hyperplasia, previously called ‘microscopic thymoma’) is a thymic epithelial cell proliferation forming discrete microscopic islands and it is not infrequently observed in thymic tissue from myasthenia gravis patients.^{40,41} True thymic hyperplasia is an increase in weight and/or size of the thymus which maintains normal histology.⁴² Because of wide variations of sizes and weights of the thymus in the normal population, true thymic hyperplasia is difficult to define except

for extreme cases; it also depends on the age of the patient as the weight of the thymic gland changes with age. The presence of thymic hyperplasia immediately adjacent to a thymoma, irrespective of the type, has no known clinical significance. Lymphoepithelial sialadenitis (LESA)-like thymic hyperplasia is a benign proliferation of thymic epithelial cells and lymphoid follicles.⁴³

Cystic changes can involve both thymic epithelial tumours and adjacent thymus.⁴⁴⁻⁴⁸ The description of cystic changes, although not of prognostic significance, may be important for clinicopathological correlation.

 [Back](#)

Note 15 – Immunohistochemical markers (Core)

This is a core element for all biopsies and for thymectomy and resections specimens of thymic carcinomas and thymic neuroendocrine tumours. Diagnosis on resection specimens of thymoma can generally be done on morphology alone.

Immunohistochemical analysis of thymic resection specimens may be performed for several reasons:

1. To exclude or confirm the presence of a tumour of thymic epithelial origin.⁴⁹
2. To aid in subtyping of thymic carcinomas and possibly thymomas and in diagnosing thymic neuroendocrine tumours.⁵⁰
3. Potentially to establish the origin of a carcinoma as either a primary thymic carcinoma or a metastasis.

The differential diagnostic spectrum of thymoma is related to either its epithelial component or to the lymphoid component. The lymphoid component of 'B-type' thymomas and of thymic follicular hyperplasia may raise the suspicion of non-Hodgkin lymphoma, especially T-lymphoblastic leukaemia/lymphoma. Immunohistochemistry may be applied to type the lymphoid population [normally composed of immature, CD3/terminal deoxynucleotidyl transferase (TdT/CD1a/CD99+) lymphocytes], or to confirm the presence of an epithelial component, which may be highlighted by pan-cytokeratin and/or p40/p63 stains. The epithelial component in thymic epithelial tumours with a sparse lymphoid component may raise the possibility of either a germ cell tumour or metastatic carcinoma.^{49,51} Germ cell tumours may be diagnosed by appropriate immunohistochemical stains including SALL4, OCT4, CD117, CD30, D2-40, human chorionic gonadotropin (hCG), placental alkaline phosphatase (PLAP), and α -fetoprotein (AFP) among others.⁴⁹

Subtyping of thymomas is primarily based on histology; immunohistochemical stains (cytokeratin and/or p40/p63) may be helpful in the evaluation of the density of the epithelial cells in B-type thymoma thus aiding the diagnosis of B1/2 thymoma. Similarly, cytokeratin stains may be used to confirm the epithelial nature of the spindle cells in type A, type AB and in metaplastic thymoma. Epithelial expression of CD20 is reported to be more frequent among type A and AB thymomas.⁵² Neuroendocrine markers may be useful to rule out neuroendocrine tumours.⁵⁰

Distinguishing thymoma (in particular type B3 thymoma) and thymic carcinoma may occasionally be problematic; there are no immunohistochemical markers that can reliably segregate these entities. However, CD5 and CD117 show a higher incidence of staining in thymic carcinoma (in particular, thymic squamous cell carcinoma) compared to thymoma.^{53,54}

The diagnosis of thymic carcinoma essentially involves the exclusion of metastasis; immunohistochemical analysis may support a diagnosis of thymic carcinoma but cannot establish the diagnosis with certainty. Expression of CD5 in combination with CD117 positivity, lends some support to a diagnosis of thymic carcinoma when compared to squamous cell carcinomas of lung origin.⁵⁵ PAX8 might support thymic carcinoma although it is not specific to TET. However, given the great diversity in histological subtypes of

thymic carcinoma, the specificity of markers routinely used to diagnose carcinoma of a particular origin may be considerably lower in this situation.

A diagnosis of NUT carcinoma needs immunohistochemical and/or molecular genetic confirmation.^{56,57} The sensitivities of NUT immunohistochemical staining have been reported as 60% and 87%.^{56,57}

Ki-67 proliferation index may be helpful in the distinction of carcinoid tumour from small cell carcinoma, especially in biopsies.

[↑ Back](#)

Note 16 – Molecular studies (Non-core)

Molecular studies have not been applied routinely for the diagnosis of thymic epithelial tumours. A subset of thymic mucoepidermoid carcinomas harbor *MAML2* rearrangements.⁵⁸ In addition, *MAML2-YAP1* gene fusion has been identified in metaplastic thymomas, and might aid in that diagnosis although metaplastic thymoma is in general a morphologic diagnosis that doesn't require molecular confirmation.⁵⁹ Testing for targetable *KIT* mutations may be requested by the oncologist in some thymic carcinomas for treatment purposes.

[↑ Back](#)

Note 17 – Histologically confirmed distant metastases (Core)

Documentation of known metastatic disease is an important part of the pathology report. Such information, if available, should be recorded with as much detail as is available including the site and reference to any relevant prior surgical pathology or cytopathology specimens.

[↑ Back](#)

Note 18 – Pathological staging (Core)

At least 15 different classification systems for staging of TET have been proposed since 1978.⁶⁰ Up until 2017, the most widely used was the Masaoka system,²⁰ modified and refined in 1994,²¹ with refinement of definitions for anatomic staging parameters proposed in 2011.²² This has now been replaced by a TNM staging system based on data from the ITMIG retrospective database of over 8,000 patients.⁹ In the new TNM 8th editions, both UICC¹⁸ and AJCC¹⁹ T stage is based on the extent of direct invasion of mediastinal structures,⁷ nodal disease is based on involvement of lymph nodes in anterior (perithymic) (N1) and deep/cervical (N2) compartments, and M stage based on the presence of separate pleural and pericardial nodules (M1a) and pulmonary intraparenchymal nodule or distant organ metastasis (M1b).⁸ While the TNM staging system should be used as the method of staging, the Masaoka-Koga system could still be used as part of ongoing studies or established clinical protocols.⁶¹ If the patient was treated with neoadjuvant therapy a 'y' should be placed before the pathologic TNM stage. If the TET is recurrent or multiple primary TET are resected then an 'r' or an 'm', respectively, should be added before the pathologic TNM stage.

The reference document: TNM Supplement: A commentary on uniform use, 5th Edition (C Wittekind et al. editors) may be of assistance when staging.⁶²

[↑ Back](#)

References

- 1 Merlin T, Weston A and Tooher R (2009). Extending an evidence hierarchy to include topics other than treatment: revising the Australian 'levels of evidence'. *BMC Med Res Methodol* 9:34.
- 2 WHO Classification of Tumours Editorial Board (2021). *Thoracic Tumours, 5th Edition, Volume 5*. IARC Press, Lyon.
- 3 Trimble EL, Ungerleider RS, Abrams JA, Kaplan RS, Feigal EG, Smith MA, Carter CL and Friedman MA (1993). Neoadjuvant therapy in cancer treatment. *Cancer* 72(11 Suppl):3515-3524.
- 4 Johnson GB, Aubry MC, Yi ES, Koo CW, Jenkins SM, Garces YI, Marks RS, Cassivi SD and Roden AC (2017). Radiologic Response to Neoadjuvant Treatment Predicts Histologic Response in Thymic Epithelial Tumors. *J Thorac Oncol* 12(2):354-367.
- 5 Detterbeck FC, Moran C, Huang J, Suster S, Walsh G, Kaiser L and Wick M (2011). Which way is up? Policies and procedures for surgeons and pathologists regarding resection specimens of thymic malignancy. *J Thorac Oncol* 6:S1730-1738.
- 6 Detterbeck FC, Stratton K, Giroux D, Asamura H, Crowley J, Falkson C, Filosso PL, Frazier AA, Giaccone G, Huang J, Kim J, Kondo K, Lucchi M, Marino M, Marom EM, Nicholson AG, Okumura M, Ruffini E and Van Schil P (2014). The IASLC/ITMIG Thymic Epithelial Tumors Staging Project: proposal for an evidence-based stage classification system for the forthcoming (8th) edition of the TNM classification of malignant tumors. *J Thorac Oncol* 9(9 Suppl 2):S65-72.
- 7 Nicholson AG, Detterbeck FC, Marino M, Kim J, Stratton K, Giroux D, Asamura H, Crowley J, Falkson C, Filosso PL, Giaccone G, Huang J, Kondo K, Lucchi M, Marom EM, Okumura M, Ruffini E and Van Schil P (2014). The IASLC/ITMIG Thymic Epithelial Tumors Staging Project: proposals for the T Component for the forthcoming (8th) edition of the TNM classification of malignant tumors. *J Thorac Oncol* 9(9 Suppl 2):S73-80.
- 8 Kondo K, Van Schil P, Detterbeck FC, Okumura M, Stratton K, Giroux D, Asamura H, Crowley J, Falkson C, Filosso PL, Giaccone G, Huang J, Kim J, Lucchi M, Marino M, Marom EM, Nicholson AG and Ruffini E (2014). The IASLC/ITMIG Thymic Epithelial Tumors Staging Project: proposals for the N and M components for the forthcoming (8th) edition of the TNM classification of malignant tumors. *J Thorac Oncol* 9(9 Suppl 2):S81-87.
- 9 Bhora FY, Chen DJ, Detterbeck FC, Asamura H, Falkson C, Filosso PL, Giaccone G, Huang J, Kim J, Kondo K, Lucchi M, Marino M, Marom EM, Nicholson AG, Okumura M, Ruffini E and Van Schil P (2014). The ITMIG/IASLC Thymic Epithelial Tumors Staging Project: A Proposed Lymph Node Map for Thymic Epithelial Tumors in the Forthcoming 8th Edition of the TNM Classification of Malignant Tumors. *J Thorac Oncol* 9(9 Suppl 2):S88-96.
- 10 Suzuki H, Yoshida S, Hiroshima K, Nakatani Y and Yoshino I (2010). Synchronous multiple thymoma: report of three cases. *Surgery today* 40:456-459.
- 11 Bernatz PE, Harrison EG and Clagett OT (1961). Thymoma: a clinicopathological study. *J Thorac Cardiovasc Surg* 42:424-444.
- 12 Leuzzi G, Marino M, Alessandrini G, Sciuto R, Pescarmona E and Facciolo F (2015). Synchronous triple thymoma and true thymic hyperplasia simultaneously detected by F FDG PET-CT. *Rev Esp Med Nucl Imagen Mol* 34(4):272-274.

- 13 Miller BS, Rusinko RY and Fowler L (2008). Synchronous thymoma and thymic carcinoid in a woman with multiple endocrine neoplasia type 1: case report and review. *Endocr Pract* 14:713-716.
- 14 Okumura M, Yoshino I, Yano M, Watanabe SI, Tsuboi M, Yoshida K, Date H, Yokoi K, Nakajima J, Toyooka SI, Asamura H and Miyaoka E (2019). Tumour size determines both recurrence-free survival and disease-specific survival after surgical treatment for thymoma. *Eur J Cardiothorac Surg* 56(1):174-181.
- 15 Roden AC, Yi ES, Jenkins SM, Edwards KK, Donovan JL, Cassivi SD, Marks RS, Garces YI and Aubry MC (2015). Modified Masaoka stage and size are independent prognostic predictors in thymoma and modified Masaoka stage is superior to histopathologic classifications. *J Thorac Oncol* 10(4):691-700.
- 16 Moran CA and Suster S (2000). On the histologic heterogeneity of thymic epithelial neoplasms. Impact of sampling in subtyping and classification of thymomas. *Am J Clin Pathol* 114(5):760-766.
- 17 Fritz A, Percy C, Jack A, Shanmugaratnam K, Lobin L, Parkin DM and Whelan S (eds) (2020). *International Classification of Diseases for Oncology. Third edition, Second revision ICD-O-3.2. Available from: http://www.iacr.com.fr/index.php?option=com_content&view=category&layout=blog&id=100&Itemid=577 (Accessed 16th June 2021).* World Health Organisation, Geneva.
- 18 Brierley JD, Gospodarowicz MK and Wittekind C (eds) (2016). *TNM Classification of Malignant Tumours, 8th Edition*, Wiley USA.
- 19 Amin MB, Edge SB, Greene FL, Byrd DR, Brookland RK, Washington MK, Gershenwald JE, Compton CC, Hess KR, Sullivan DC, Jessup JM, Brierley JD, Gaspar LE, Schilsky RL, Balch CM, Winchester DP, Asare EA, Madera M, Gress DM and Meyer LR (eds) (2017). *AJCC Cancer Staging Manual. 8th ed.*, Springer, New York.
- 20 Masaoka A, Monden Y, Nakahara K and Tanioka T (1981). Follow-up study of thymomas with special reference to their clinical stages. *Cancer* 48(11):2485-2492.
- 21 Koga K, Matsuno Y, Noguchi M, Mukai K, Asamura H, Goya T and Shimosato Y (1994). A review of 79 thymomas: modification of staging system and reappraisal of conventional division into invasive and non-invasive thymoma. *Pathol Int* 44(5):359-367.
- 22 Detterbeck FC, Nicholson AG, Kondo K, Van Schil P and Moran C (2011). The Masaoka-Koga stage classification for thymic malignancies: clarification and definition of terms. *J Thorac Oncol* 6(7 Suppl 3):S1710-1716.
- 23 Gupta R, Marchevsky AM, McKenna RJ, Wick M, Moran C, Zakowski MF and Suster S (2008). Evidence-based pathology and the pathologic evaluation of thymomas: transcapsular invasion is not a significant prognostic feature. *Arch Pathol Lab Med* 132(6):926-930.
- 24 Ogawa K, Uno T, Toita T, Onishi H, Yoshida H, Kakinohana Y, Adachi G, Itami J, Ito H and Murayama S (2002). Postoperative radiotherapy for patients with completely resected thymoma: a multi-institutional, retrospective review of 103 patients. *Cancer* 94(5):1405-1413.
- 25 Okuda K, Yano M, Yoshino I, Okumura M, Higashiyama M, Suzuki K, Tsuchida M, Usuda J and Tateyama H (2014). Thymoma patients with pleural dissemination: nationwide retrospective study of 136 cases in Japan. *Ann Thorac Surg* 97(5):1743-1748.

- 26 Weissferdt A and Moran CA (2013). The impact of neoadjuvant chemotherapy on the histopathological assessment of thymomas: a clinicopathological correlation of 28 cases treated with a similar regimen. *Lung* 191(4):379-383.
- 27 Korst R.J et al (2014). Neoadjuvant chemoradiotherapy for locally advanced thymic tumors: a phase II, multi-institutional clinical trial. *J Thorac Cardiovasc Surg* 147(1):36-44, 46 e31.
- 28 Mineo TC et al (2010). New predictors of response to neoadjuvant chemotherapy and survival for invasive thymoma: a retrospective analysis. *Ann Surg Oncol* 17(11):3022-3029.
- 29 Kawasaki H et al (2014). Weekly chemotherapy with cisplatin, vincristine, doxorubicin, and etoposide followed by surgery for thymic carcinoma. *Eur J Surg Oncol* 40(9):1151-1155.
- 30 Wright CD et al (2008). Induction chemoradiotherapy followed by resection for locally advanced Masaoka stage III and IVA thymic tumors. *Ann Thorac Surg* 85(2):385-389.
- 31 Kim ES et al (2004). Phase II study of a multidisciplinary approach with induction chemotherapy, followed by surgical resection, radiation therapy, and consolidation chemotherapy for unresectable malignant thymomas: final report. *Lung Cancer* 44(3):369-379.
- 32 White DB, Hora MJ, Jenkins SM, Marks RS, Garces YI, Cassivi SD and Roden AC (2019). Efficacy of chest computed tomography prediction of the pathological TNM stage of thymic epithelial tumours. *Eur J Cardiothorac Surg* 56(2):285–293.
- 33 College of American Pathologists (2021). *Protocol for the Examination of Specimens From Patients With Thymic Tumors*. Available from: https://documents.cap.org/protocols/Thymus_4.1.0.0.REL_CAPCP.pdf. (Accessed 10th Nov 2021)
- 34 Kondo K and Monden Y (2003). Lymphogenous and hematogenous metastasis of thymic epithelial tumors. *Ann Thorac Surg* 76(6):1859-1864; discussion 1864-1855.
- 35 Ruffini E, Detterbeck F, Van Raemdonck D, Rocco G, Thomas P, Weder W, Brunelli A, Evangelista A, Venuta F and European Association of Thoracic Surgeons (ESTS) Thymic Working Group (2014). Tumours of the thymus: a cohort study of prognostic factors from the European Society of Thoracic Surgeons database. *Eur J Cardiothorac Surg* 46(3):361-368.
- 36 Moser B, Scharitzer M, Hacker S, Ankersmit J, Matilla JR, Lang G, Aigner C, Taghavi S and Klepetko W (2014). Thymomas and thymic carcinomas: prognostic factors and multimodal management. *Thorac Cardiovasc Surg*. 62(2):153-160.
- 37 Viti A, Bertolaccini L and Terzi A (2014). What is the role of lymph nodal metastases and lymphadenectomy in the surgical treatment and prognosis of thymic carcinomas and carcinoids? *Interact Cardiovasc Thorac Surg* 19(6):1054-1058.
- 38 Ströbel P, Moritz R, Leite MI, Willcox N, Chuang WY, Gold R, Nix W, Schalke B, Kiefer R, Müller-Hermelink HK, Jaretzki III A, Newsom-Davis J and Marx A (2008). The ageing and myasthenic thymus: A morphometric study validating a standard procedure in the histological workup of thymic specimens. *J Neuroimmunol* 201-202:64-73.
- 39 Marx A, Pfister F, Schalke B, Nix W and Ströbel P (2012). Thymus pathology observed in the MGTX trial. *Ann NY Acad Sci* 1275:92-100
- 40 Pescarmona E, Rosati S, Pisacane A, Rendina EA, Venuta F and Baroni CD (1992). Microscopic thymoma: histological evidence of multifocal cortical and medullary origin. *Histopathology* 20:263-266.

- 41 Puglisi F, Finato N, Mariuzzi L, Marchini C, Floretti G and Beltrami CA (1995). Microscopic thymoma and myasthenia gravis. *J Clin Pathol* 48:682-683.
- 42 Hofmann WJ, Möller P and Otto HF (1987). Thymic hyperplasia. I. True thymic hyperplasia. Review of the literature. *Klin Wochenschr* 65:49-52.
- 43 Porubsky S, Popovic ZV, Badve S, Banz Y, Berezowska S, Borchert D, Brüggemann M, Gaiser T, Graeter T, Hollaus P, Huettl KS, Kotrova M, Kreft A, Kugler C, Lötscher F, Möller B, Ott G, Preissler G, Roessner E, Rosenwald A, Ströbel P and Marx A (2021). Thymic Hyperplasia with Lymphoepithelial Sialadenitis (LESA)-Like Features: Strong Association with Lymphomas and Non-Myasthenic Autoimmune Diseases. *Cancers (Basel)* 13(2).
- 44 Suster S and Rosai J (1991). Multilocular thymic cyst: an acquired reactive process. Study of 18 cases. *Am J Surg Pathol* 15(4):388-398.
- 45 Moran CA and Suster S (2001). Thymoma with prominent cystic and hemorrhagic changes and areas of necrosis and infarction: a clinicopathologic study of 25 cases. *Am J Surg Pathol* 25(8):1086-1090.
- 46 Weissferdt A and Moran CA (2011). Thymic carcinoma associated with multilocular thymic cyst: a clinicopathologic study of 7 cases. *Am J Surg Pathol* 35(7):1074-1079.
- 47 Nakamura S, Tateyama H, Taniguchi T, Ishikawa Y, Kawaguchi K, Fukui T, Mizuno T, Ishiguro F and Yokoi K (2012). Multilocular thymic cyst associated with thymoma. A clinicopathologic study of 20 cases with an emphasis on the pathogenesis of cyst formation. *Am J Surg Pathol* 36:1857-1864.
- 48 Araki T, Sholl LM, Gerbaudo VH, Hatabu H and Nishino M (2014). Intrathymic cyst: clinical and radiologic features in surgically resected cases. *Clin Radiol* 69(7):732-738
- 49 den Bakker MA and Oosterhuis JW (2009). Tumours and tumour-like conditions of the thymus other than thymoma; a practical approach. *Histopathology* 54(1):69-89.
- 50 den Bakker MA, Roden AC, Marx A and Marino M (2014). Histologic classification of thymoma: a practical guide for routine cases. *J Thorac Oncol* 9(9 Suppl 2):S125-130.
- 51 Marchevsky A, Marx A, Strobel P, Suster S, Venuta F, Marino M, Yousem S and Zakowski M (2011). Policies and reporting guidelines for small biopsy specimens of mediastinal masses. *J Thorac Oncol* 6(7 Suppl 3):S1724-1729.
- 52 Chilosi M, Castelli P, Martignoni G, Pizzolo G, Montresor E, Facchetti F, Truini M, Mombello A, Lestani M, Scarpa A and et al. (1992). Neoplastic epithelial cells in a subset of human thymomas express the B cell-associated CD20 antigen. *Am J Surg Pathol* 16(10):988-997.
- 53 Kaira K, Murakami H, Serizawa M, Koh Y, Abe M, Ohde Y, Takahashi T, Kondo H, Nakajima T and Yamamoto N (2011). MUC1 expression in thymic epithelial tumors: MUC1 may be useful marker as differential diagnosis between type B3 thymoma and thymic carcinoma. *Virchows Arch* 458(5): 615-620.
- 54 Kojika M, Ishii G, Yoshida J, Nishimura M, Hishida T, Ota SJ, Murata Y, Nagai K and Ochiai A (2009). Immunohistochemical differential diagnosis between thymic carcinoma and type B3 thymoma: diagnostic utility of hypoxic marker, GLUT-1, in thymic epithelial neoplasms. *Mod Pathol* 22(10):1341-1350.

- 55 Kriegsman M, Muley T, Harms A, Tavernar L, Goldmann T, Dienemann H, Herpel E and Warth A (2015). Differential diagnostic value of CD5 and CD117 expression in thoracic tumors: a large scale study of 1465 non-small cell lung cancer cases. *Diagn Pathol* 10:210.
- 56 French CA (2010). Demystified molecular pathology of NUT midline carcinomas. *J Clin Pathol* 63(6):492-496.
- 57 Haack H, Johnson LA, Fry CJ, Crosby K, Polakiewicz RD, Stelow EB, Hong SM, Schwartz BE, Cameron MJ, Rubin MA, Chang MC, Aster JC and French CA (2009). Diagnosis of NUT midline carcinoma using a NUT-specific monoclonal antibody. *Am J Surg Pathol* 33(7):984-991.
- 58 Roden AC, Erickson-Johnson MR, Yi ES and García JJ (2013). Analysis of MAML2 rearrangement in mucoepidermoid carcinoma of the thymus. *Hum Pathol* 44(12):2799-2805.
- 59 Vivero M, Davineni P, Nardi V, Chan JKC and Sholl LM (2020). Metaplastic thymoma: a distinctive thymic neoplasm characterized by YAP1-MAML2 gene fusions. *Mod Pathol* 33(4):560-565.
- 60 Filosso PL, Ruffini E, Lausi PO, Lucchi M, Oliaro A and Detterbeck F (2014). Historical perspectives: The evolution of the thymic epithelial tumors staging system. *Lung Cancer* 83(2):126-132.
- 61 Rami-Porta R (ed) (2016). *Staging Manual in Thoracic Oncology, 2nd edition: An International Association for the Study of Lung Cancer Publication, Developed in collaboration with AJCC and UICC*, Editorial Rx Press, North Fort Myers, FL, US.
- 62 Wittekind C, Brierley JD, van Eycken AL and van Eycken E (eds) (2019). *TNM Supplement: A Commentary on Uniform Use, 5th Edition* Wiley, USA.