

Lymphatic and blood vessel invasion (Core and Non-core)

All follicular carcinomas and the vast majority of Hürthle cell carcinomas spread hematogenously to distant sites bypassing lymph nodes while most papillary carcinomas (with the notable exception of encapsulated papillary carcinoma follicular variant) preferentially spread to lymph nodes. It is therefore assumed that the vessels invaded by tumour in follicular and Hürthle cell carcinoma are usually blood vessels while those in papillary carcinoma are usually lymphatic spaces. Invasion of the latter is however difficult to identify except in the rare diffuse sclerosing variant.¹ Lymphatic invasion can be undetected in many primary papillary carcinomas despite the patients having a large volume of nodal metastasis. Therefore, in contrast to blood vessel invasion, the presence of lymphatic space permeation has not been shown to date to have any prognostic value. Of note, blood vessel invasion can occur in papillary carcinomas (including classic) and the vessels involved are often readily identified as blood vessels because of their size and the presence of smooth muscle in their walls. Based on the type of carcinomas and the histologic appearance of the vessel, the pathologist can in most instances indicate the type of vessel involved by tumour. There are however, a few instances where this is not possible in small vessels. Since blood vessel invasion (BVI) is a crucial diagnostic and prognostic feature, the criteria for its identification should be well delineated. The majority of authors agree that blood vessel invasion (BVI) should involve capsular or extra-capsular vessels in encapsulated tumours (Figure 2). In infiltrative tumours partially encapsulated or totally lacking a capsule, BVI can be present within the tumour nodule. These images (Figure 2) depict intracapsular BVI with tumour thrombus attached to the vessel wall, covered by endothelium or associated with fibrin. Tumour thrombus covered by endothelial cells qualifies as BVI (Figure 2b). However, endothelialization is not a requirement if the tumour is attached to the vessel wall (Figure 2c) or admixed with a fibrin thrombus (Figure 2d). If the tumour is encapsulated, intra-tumoural or subcapsular vessels do not qualify for BVI and should not be interpreted as such (Figure 2a). One study has raised the caveat that tumour cells within vascular lumina unassociated with thrombus, and tumour cells underlying intact endothelium could represent “pseudoinvasion” given the fenestrated, endothelial network of endocrine organs.² When this more stringent criterion of BVI is applied, the incidence of BVI in differentiated thyroid carcinoma decreased drastically from 7-62%³⁻⁷ to 3%,² while the risk of distant metastasis in association with the mere existence of BVI becomes 35%. This latter approach has not been validated by additional studies and may fail to identify a significant proportion of thyroid tumours with BVI, focal or extensive, that should be classified as carcinoma based on the presence of invasion, and that may benefit from appropriate risk stratification and/or additional therapies.

The consensus opinion is that the criteria used in Figure 2 to define BVI should be utilized. In regard to the extent of BVI, several papers have shown that the presence of 4-5 foci of BVI in encapsulated follicular/Hürthle cell carcinoma confers a much worse outcome than lower number of BVI foci.⁸⁻¹⁰ The most recent American Thyroid Association (ATA) guidelines classify a patient in a high risk category, if having 4 foci or more of BVI, while focal BVI (<4 foci) in an intrathyroidal follicular carcinoma will put the patient in low risk group.¹¹ More importantly, the National Comprehensive Cancer Network (NCCN) 2019 guidelines have defined minimal vascular invasion as a few foci (1-4) of vascular invasion, and does not mandate radioiodine (RAI) administration in an intrathyroidal, well defined, follicular or Hürthle cell carcinoma, with minimal vascular invasion.¹² Consequently, it is important to report the extent of BVI in encapsulated thyroid carcinoma by counting the foci of BVI. It is noteworthy that most papers that validated the importance of BVI cutoffs have counted individual vessel sections invaded by tumour separately, as different foci. In regard to papillary thyroid carcinoma (PTC), the presence of BVI was shown to impart poorer outcome.⁶ Furthermore any focus of BVI in PTC will put the patient in an intermediate risk category according to the most recent ATA guidelines.¹¹ It is therefore mandatory to report on the status of BVI in PTC (i.e., core item). There is no evidence that the number of BVI foci impact on prognosis in non-encapsulated PTC. Counting the BVI foci in non-encapsulated PTC is therefore not a core item. It is however a core item in those PTC

who are completely encapsulated. In a small proportion of surgically operable, but locally aggressive differentiated thyroid carcinomas, tumour is identified within perithyroidal large veins or the internal jugular vein as large plugs of tumour thrombus. These patients often have synchronous distant metastases or are at higher risk to develop these subsequently. Whilst the presence of extrathyroidal blood vessel invasion is not considered a separate core item in addition to blood vessel invasion, there may be benefit in noting this finding if present.

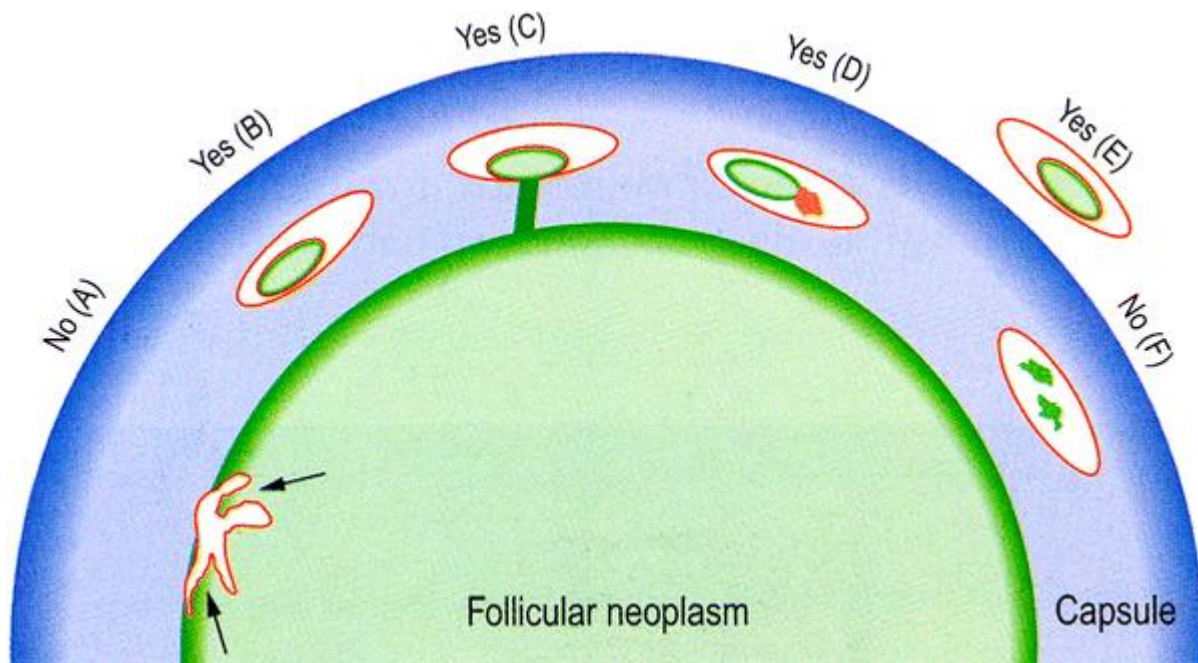


Figure 2: Blood vessel invasion (BVI). Schematic drawing for the interpretation of the presence or absence of BVI. The diagram depicts a follicular neoplasm (green) surrounded by a fibrous capsule (blue). **a** Bulging of tumour into vessels within the tumour proper does not constitute BVI. **b** Tumour thrombus covered by endothelial cells in intracapsular vessel qualifies as BVI. **c** Tumour thrombus in intracapsular vessel considered as BVI since it is attached to the vessel wall. **d** Although not endothelialized, this tumour thrombus qualifies for BVI because it is accompanied by a fibrin thrombus. **e** Endothelialized tumour thrombus in vessel outside the tumour capsule represents BVI. **f** Artefactual dislodgement of tumour manifesting as irregular tumour fragments into vascular lumen unaccompanied by endothelial covering or fibrin thrombus. Modified from the original version in Chan J (2007). *Tumours of the thyroid and parathyroid glands*. Diagnostic Histopathology of Tumours. Fletcher CDM. Churchill Livingstone Elsevier, Philadelphia.¹³ Reproduced with permission.

References

- 1 Lloyd R, Osamura R, Klöppel G and Rosai J (eds) (2017). *WHO Classification of Tumours of Endocrine Organs*, 4th ed. IARC Press, Lyon.
- 2 Mete O and Asa SL (2011). Pathological definition and clinical significance of vascular invasion in thyroid carcinomas of follicular epithelial derivation. *Mod Pathol* 24(12):1545-1552.
- 3 Xu B, Wang L, Tuttle RM, Ganly I and Ghossein R (2015). Prognostic impact of extent of vascular invasion in low-grade encapsulated follicular cell-derived thyroid carcinomas: a clinicopathologic study of 276 cases. *Hum Pathol* 46(12):1789-1798.

- 4 Cao J, Hu JL, Chen C, Wang QL, Fang XH, Zhang Y and Ge MH (2016). Vascular invasion is an independent prognostic factor for distant recurrence-free survival in papillary thyroid carcinoma: a matched-case comparative study. *J Clin Pathol* 69(10):872-877.
- 5 Kim HJ, Sung JY, Oh YL, Kim JH, Son YI, Min YK, Kim SW and Chung JH (2014). Association of vascular invasion with increased mortality in patients with minimally invasive follicular thyroid carcinoma but not widely invasive follicular thyroid carcinoma. *Head Neck* 36(12):1695-1700.
- 6 Wreesmann VB, Nixon IJ, Rivera M, Katabi N, Palmer F, Ganly I, Shaha AR, Tuttle RM, Shah JP, Patel SG and Ghossein RA (2015). Prognostic value of vascular invasion in well-differentiated papillary thyroid carcinoma. *Thyroid* 25(5):503-508.
- 7 Falvo L, Catania A, D'Andrea V, Marzullo A, Giustiniani MC and De Antoni E (2005). Prognostic importance of histologic vascular invasion in papillary thyroid carcinoma. *Ann Surg* 241(4):640-646.
- 8 Collini P, Sampietro G and Pilotti S (2004). Extensive vascular invasion is a marker of risk of relapse in encapsulated non-Hurthle cell follicular carcinoma of the thyroid gland: a clinicopathological study of 18 consecutive cases from a single institution with a 11-year median follow-up. *Histopathology* 44(1):35-39.
- 9 Ghossein RA, Hiltzik DH, Carlson DL, Patel S, Shaha A, Shah JP, Tuttle RM and Singh B (2006). Prognostic factors of recurrence in encapsulated Hurthle cell carcinoma of the thyroid gland: a clinicopathologic study of 50 cases. *Cancer* 106(8):1669-1676.
- 10 Lang W, Choritz H and Hundeshagen H (1986). Risk factors in follicular thyroid carcinomas. A retrospective follow-up study covering a 14-year period with emphasis on morphological findings. *Am J Surg Pathol* 10(4):246-255.
- 11 Haugen BR, Alexander EK, Bible KC, Doherty GM, Mandel SJ, Nikiforov YE, Pacini F, Randolph GW, Sawka AM, Schlumberger M, Schuff KG, Sherman SI, Sosa JA, Steward DL, Tuttle RM and Wartofsky L (2016). 2015 American Thyroid Association Management Guidelines for Adult Patients with Thyroid Nodules and Differentiated Thyroid Cancer: The American Thyroid Association Guidelines Task Force on Thyroid Nodules and Differentiated Thyroid Cancer. *Thyroid* 26(1):1-133.
- 12 National Comprehensive Cancer Network. *Thyroid Cancer* (Version 2.2019). Available from: https://www.nccn.org/professionals/physician_gls/pdf/thyroid.pdf (Accessed 1st November 2019).
- 13 Chan J (2007). *Tumours of the thyroid and parathyroid glands. In: Diagnostic Histopathology of tumours*. Fletcher CDM. Churchill Livingstone Elsevier, Philadelphia.